



**The 10th Annual
Scientific Meeting**
InaHRS 2023

CASE REPORT



PERSISTENT INCREASED VENTRICULAR PACING THRESHOLD, IS IT DISLODGMET OR MATURATION LEAD?

A. D. Prasetyo¹, E. Maharani¹, F. Hidayati¹

¹Faculty of Medicine, Public Health and Nursing, Universitas Gadjah Mada - Dr. Sardjito General Hospital, Yogyakarta, Indonesia

Background: The Pacing threshold is the most important functional parameter in the cardiac pacing system. Lower thresholds not only greatly save the pacemaker's battery power, but also reduce the possible discomfort of patients caused by the larger pacing stimulation. If a high threshold occurs within hours to a few days after implantation, then lead micro/macro-dislodgement should be suspected, if it occurs within a few weeks and is persistent, then the lead maturation process may be the cause. Several factors such as antiarrhythmic drugs, myocardial ischemia, electrolyte imbalance, diabetes, and electrical conversion may increase pacing thresholds and increase the probability of the early maturation process. We reported two cases with persistent high threshold pacing after pacemaker implantation.

Case Illustration: The first case, is a 63-year-old woman with a history of diabetes and coronary artery disease, post-implantation of single-chamber pacemaker due to complete heart block status. Chest radiography revealed the appropriate pacemaker lead position. Electrocardiogram revealed a ventricular-paced rhythm with intermittent loss capture. Interrogation of her pacemaker revealed an estimated battery life of 5 years. There was a significant increase in the right ventricular (RV) lead pacing threshold 3 months after implantation from 0.5 V @ 0.4 ms to 3.75 V @ 0.4 ms. The second case is a 67-year-old man with a history of single-chamber pacemaker implantation due to complete heart block status. Chest radiography revealed the appropriate pacemaker lead position. Electrocardiogram revealed a ventricular-paced rhythm. Interrogation of his pacemaker revealed an estimated battery life of 5 years. There was a significant persistent increase in RV lead pacing threshold within 2 years after implantation from 0.5 V @ 0.4 ms to 2.5 V @ 0.4 ms. Both of them performed pacemaker lead replacement due to high threshold pacing. But several months after reimplantation the high threshold pacing is still persistent.

Conclusion: The pacing threshold should be monitored after pacemaker implantation and the episode of high pacing threshold can predict the etiologist. Persistent high threshold pacing should be considered as early lead maturation.

Keywords: Pacing threshold, maturation lead, lead dislodgment.



Symptomatic accelerated idioventricular rhythm in young adult: a case report and literature study

A.F. Rachma¹, R.N. Rosyadi¹, R. Julario¹

¹ Department of Cardiology and Vascular Medicine, Faculty of Medicine, Universitas Airlangga,
Surabaya, East Java, Indonesia

Background: Accelerated idioventricular rhythm (AIVR) is defined as a ventricular ectopic rhythm that exceeds the sinus node, presenting as 3 or more premature beats with a rate of 50 to 110 bpm. This uncommon rhythm is related to pathologies such as acute myocardial infarction, carditis, congenital heart disease, cardiomyopathy, electrolyte imbalance and drug intoxication. Most of the time, episodes of AIVR are transient and benign, therefore there is no need for further treatment. Previous study stated that chronic treatment with anti arrhythmic drugs is not recommended generally as it may deteriorate patients' hemodynamic status. However, in selected patients anti arrhythmic drugs are proven to be beneficial.

Case Illustration: A 23-year-old woman who experienced a new-onset post-COVID dyspnea was referred to cardiology outpatient clinic due to episodes of syncope and chest pain. She had no previously known heart disease and did not take any specific medication. A resting ECG examination revealed AIVR with heart rate of 65 bpm while ECGs during exercise revealed no arrhythmia. Echocardiography result demonstrated a normal heart structure and function. A 24-hour Holter analysis was also conducted and showed a result of 24% burden of paroxysmal accelerated ventricular rhythm. Subsequently, electrophysiology study was done and it was concluded as AIVR with lower posterior RVOT origin. The patient was then treated with amiodarone. On follow ups, the patient reported no more symptoms and ECG examination revealed normal sinus rhythm. Further ablation is scheduled for this patient.

Conclusion: AIVR is a rare ventricular ectopic rhythm which is commonly found alongside with other cardiac pathologies. Although rarely symptomatic, in some cases in which symptoms are not tolerable, anti arrhythmic drugs such as amiodarone might be beneficial. However, chronic treatment with anti arrhythmic drugs are not recommended as it should be used as bridging therapy to more definitive treatment such as catheter ablation.

Keywords: accelerated idioventricular rhythm (AIVR), young adult, case report

A Case Report of Recurrent Ventricular Tachycardia in an Emergency Room

A. H. Laila¹, Febrina², N. Ubaidillah³

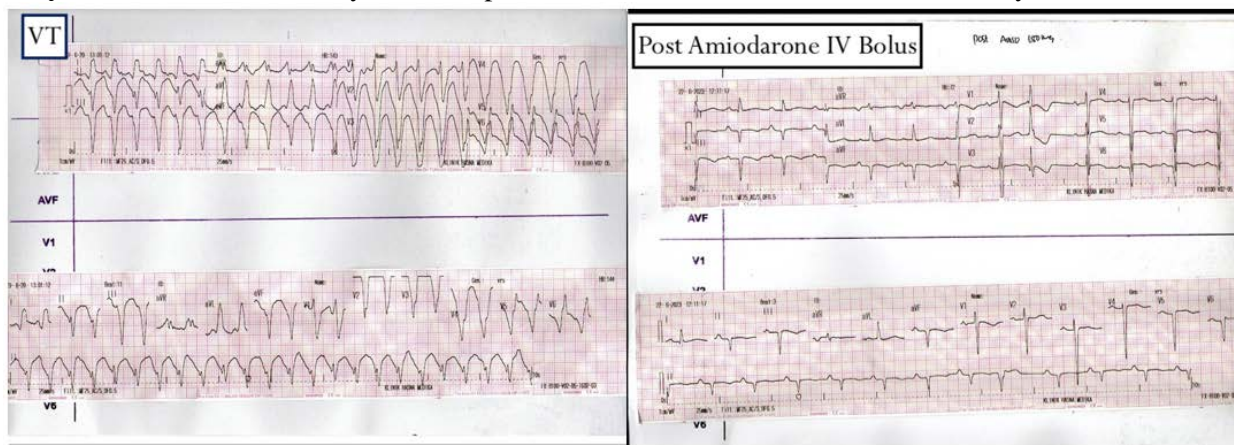
¹General Practitioner, Hasna Medika Bandung Heart Clinic, Bandung, Indonesia; ²Cardiologist, RSUD Cikalongwetan, Bandung, Indonesia; ³Interventionist Cardiologist, RS Dustira, Cimahi, Indonesia

Background: Ventricular tachycardia(VT) is known as a lethal arrhythmia in ischemic cardiomyopathy(ICM). VT in ICM generally occurs due to re-entry in the presence of arrhythmogenic substrate/scar. Recurrent VT may lead to hemodynamic collapse, heart failure, syncope, and sudden cardiac death(SCD).

Case Illustration: A 52-year-old male patient came to the emergency room due to palpitation that lasted for 15 minutes. The patient was alert and hemodynamically stable with blood pressure of 118/80 and heart rate of 180bpm. Electrocardiography revealed sustained monomorphic VT. After administering 150mg amiodarone, the electrocardiography converted to sinus rhythm. During inpatient care, no other episodes of VT were observed. From past medical history, the patient reported several episodes of palpitation and chest pain. One month prior, the patient underwent percutaneous coronary intervention(PCI) with stent placement on right coronary artery(RCA) due to anteroseptal STEMI and VT. However, three weeks after the first PCI, the patient reported palpitation and chest pain again. His last angiography revealed Left Main: Normal; Left Anterior Descending(LAD): Calcification, chronic total occlusion in Mid after D1 branch, and severe stenosis in the Proximal D1 branch; Left Circumflex: Moderate stenosis in proximal; RCA: Insitu patent old stent. However, stent placement of the LAD was unsuccessful. Echocardiography showed left ventricular ejection fraction of 29%, dilated left atrium and left ventricle, and regional wall motion abnormality. The patient is scheduled for implantable cardioverter-defibrillator(ICD) implantation.

Conclusion: In our case, VT can be managed with pharmacological treatment. However, pharmacological treatment can be proarrhythmic and might be not effective in the future. Long-term management is required since the patient had experienced repeated VT episodes. In our case, coronary revascularization alone is ineffective to prevent recurrent VT. Thus, ICD implantation should be planned because it is strongly recommended in the current guidelines as ICD improve overall survival in patients who survived SCD or with hemodynamically unstable VT.

Keywords: Ventricular Tachycardia; Implantable Cardioverter-Defibrillator; Coronary Revascularization





A Conventional Ablation of Premature Ventricular Complexes Originated from The Left Coronary Cusp, How to Perform it Systematically and Safe

A. Handayani¹, E. J. Gunawan¹, Johan¹, I. Adriani¹, D. L. Munawar¹,
B. Hartono¹, M. Munawar¹

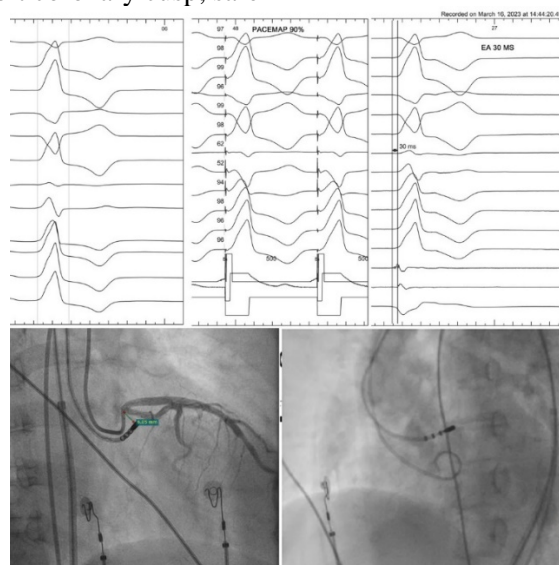
¹Binawaluya Heart Hospital, Jakarta, Indonesia;

Background: The Left Coronary Cusp (LCC) is uncommon but a well-known site for the ablation of premature ventricular complexes (PVCs). Proximity to the left coronary ostium makes ablation of this arrhythmia challenging. The step-by-step strategy of ablation should be made systematically and assure the safety regarding the risk of damaging the coronary circulation. In addition, there are also differences in how to analyse the precise site of ablation between the PVCs from Right Ventricular Outflow Tract (RVOT) and LCC, whereas the latter use preferential exit approach which earliest activation become more useful rather than pace-mapping.

Case Illustration: A female 58 years old referred to the hospital with palpitations for one month. Electrocardiography (ECG) from the previous hospital showed sinus rhythm with bigeminy PVCs. Analysis of the PVCs showed an inferior axis with left bundle branch block (LBBB) pattern and negative polarization in I and aVL with the transition on V2. This ECG findings suggest the PVCs originating from LCC or RVOT. A conventional ablation then performed to this patient with these steps. First, we map the Right Ventricular (RV) area which we found the earliest activation 38 ms with the pace-mapping showed 88% similarity and we performed several attempts which went unsuccessful. After that, we then moved the ablation catheter to search the origin from the Left Ventricular Outflow Tract (LVOT) using retrograde approach. The earliest activity was 30 ms with the pace-mapping showed 90% similarity. We then performed a coronary angiography and measured the distance between ablation point to the LCA ostium which is more than 5 mm. Ablation performed two times in the LCC area with successful result. After the ablation, then we put a pigtail catheter and performed the aortography which showed no complications.

Conclusion: A safety ablation of PVC originated from the LCC could be done by the conventional method using a systematic step-by-step approach to ensure the safety and success result.

Keyword: ablation, PVCs, left coronary cusp, safe



Picture 1. Figure (a) PVC morphology (b) pace-mapping of the PVC from LVOT area (c) earliest activity from the ablation catheter (d) the distance between ablation catheter LCA ostium (e) post ablation aortography

Left Atrial Reverse Remodelling Following Dual Chamber Pacemaker in A Patient with Asymptomatic Sinus Node Dysfunction and Left Atrial Enlargement, A New Insight

A. Handayani¹, E. J. Gunawan¹, Johan¹, I. Adriana¹, D. L. Munawar¹,

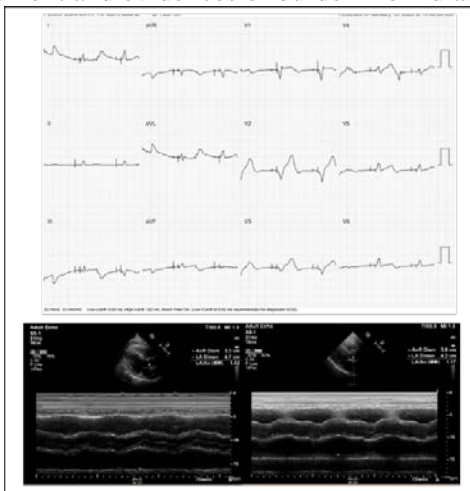
B. Hartono¹, M. Munawar¹

¹Binawaluya Heart Hospital, Jakarta, Indonesia

Background: Left atrial (LA) enlargement with a consequent decrease in LA function represents a structural remodelling that in turn promotes electrical remodelling and subsequently atrial fibrillation. Atrial remodelling is largely due to the development of rapid atrial tachyarrhythmias or secondary because of pressure or volume overload. Despite of these, LA enlargement could also be caused by atrial myopathy from the degenerative process. Moreover, atrial myopathies are found to have an association with sinus node dysfunction (SND) which is also related with the ageing. Symptomatic patients with SND are candidates for pacemaker implantation but not for the asymptomatic one.

Case Illustration: A male 73 years old admitted to our hospital due to documented marked sinus bradycardia (heart rate 39 bpm) and paroxysmal Atrial Fibrillation (AF) from the holter examination. He denied any common symptom related to SND but noted that sometimes he was reported felt sleepy. The baseline Electrocardiography (ECG) was normal and from the echocardiography we found LA enlargement. We suggested that this enlargement could be because of the increase of LA diastolic filling time. He was also hypertensive at the moment which supported this hypothesis. Due to the LA enlargement and AF, we considered to implant pacemaker in order to maintain physiological hemodynamic performance which will prevent further enlargement. After shared decision making, the dual chamber pacemaker implanted with left bundle pacing for the RV pacing. High frequency of right ventricular (RV) was prevented in purpose to prevent AV dyssynchrony so the pacemaker was set to the AAI mode switch to DDDR. There were no complications during and after the procedure. After four months follow up, we found the LA dimension size was decreased from 47 mm to 42 mm. There were also no episodes of paroxysmal AF and the blood pressure return to normal valued during follow up. We suggested a left atrial reverse remodelling had happened to this patient.

Conclusion: In this case report, a dual chamber pacemaker implantation promoted LA reverse remodelling in patients with SND, LA enlargement and evidences of burden from diastolic filling prolongation.



Picture 1. (a) Twelve lead ECG post DC PPM (b) First echocardiography revealed LA diameter of 47 mm (c) LA diameter after several months post PPM decreased to 42 mm

**Ablation Strategy for Third Episode of Recurrent Atrioventricular-Nodal Re-entrant Tachycardia
After Previous Successful Slow Pathway Ablation**

A. Handayani¹, E. J. Gunawan¹, Johan¹, I. Adriana¹, D. L. Munawar¹,

B. Hartono¹, M. Munawar¹

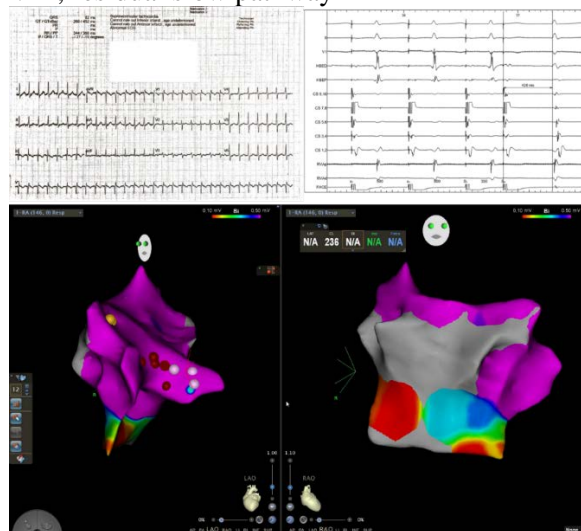
¹Binawaluya Cardiac Centre, Jakarta, Indonesia

Background: Atrioventricular nodal re-entrant tachycardia (AVNRT) is the most common type of supraventricular tachycardia. Even after successful slow pathway (SP) ablation, offers a success rate of 97%, has 1 to 4% recurrence rate. Consensus on the risk factors for AVNRT recurrence has not been established, however one of the possible causes is residual slow pathway.

Case Illustration: A female 62 years old, admitted to the hospital due to recurrent episode of narrow complex tachycardia. The patient had undergone slow pathway ablation two times in 2019. Electrophysiology Study (EPS) with programmed atrial stimulation revealed AH jump from 270 ms to 428 ms with single echo beat. There is no tachycardia could be induced. A three-dimensional ablation with 7F quadripolar steerable ablation irrigating catheter with 4 mm-tip was performed. His and coronary sinus ostium was marked, and then the slow pathway ablation was done at the low Koch triangle area with a power and temperature controlled at 30 watts and 40° Celsius for 40 seconds. It was performed for multiple times during sinus rhythm and pacing stimuli. A junctional rhythm was recognized and after an incident of transient AV Block, the ablation was stopped. Programmed stimulation, burst pacing and isoproterenol infusion after ablation showed no episode of AH jump and echo beat.

Conclusion: Recurrence of AVNRT might occurred and the residual slow pathway might be the cause. Repeated slow pathway ablation with the target of demolished of the AH jump after ablation was one strategy that could be implemented.

Keywords: Recurrence, AVNRT, residual slow pathway



Picture (a) Twelve leads ECG of the episode of NCT (b) AH jump from the EPS (c) 3D mapping of slow pathway area

A Challenging Ischemic Ventricular Tachycardia Ablation in Right Ventricular Area In A Patient on Dual Chamber Pacemaker and Without Easily Inducible Ventricular Tachycardia Intraprocedural

A. Handayani¹, E. J. Gunawan¹, Johan¹, I. Adriana¹, D. L. Munawar¹, Haikal²

B. Hartono¹, M. Munawar¹

¹Binawaluya Cardiac Centre, Jakarta, Indonesia;

²Indonesian Army National General Hospital

Background: Ventricular tachycardia (VT) ablation remains one of the cornerstone therapies in a patient with scar VT, especially in patient with frequent VT or VT storm. The mapping technique used to localize VT depend on the mechanism of VT. In re-entrant ischemic scar VT there is continuous activation of a re-entrant pathway; therefore it is necessary to identify critical sites to have a successful result. When no target is available (non-inducible VT or induction of hemodynamically un-tolerated VT or multiple VTs) substrate mapping can be used to guide ablation of scar-related VTs.

Case Illustration; A 71 years-old male due to palpitation and fatigue. He had already done Coronary Artery Bypass Surgery (CABG) and Percutaneous Coronary Intervention (PCI) a few years ag with low ejection fraction (33%). The baseline rhythm was third degree atrioventricular block. At first, we implanted dual chamber pacemaker (we could not implant ICD due to patient limitation) to overcome his bradycardia induced tachyarrhythmias. However, the VT was frequently occurred which then we decided to perform revascularization. After these two efforts, the VT still occurred.

We decided to perform three-dimensional VT ablation in this patient even though there were some difficult possibilities such as multiple VTs, compromised hemodynamic, and difficulty to approach right sided area due to passive pacemaker lead in RV. During procedure, substrate voltage mapping showed large scar area in the LV. When we tried to do the entrainment, the VT could not be induced, potentially due to the sedation. We tried to lowering the rate of PPM and decrease the sedative dose. However, it was still barely inducible. Finally, we decided to map from the right ventricle (RV). Pace-mapping was performed in mid-septum area which showed similarity of 94-95%. Ablation started in this area and directed to the border zone. The endpoint was un-inducible area with pacing. After procedure and several days of observation, the clinical VT did not occured and patient could be discharged from the hospital.

Conclusion: In a scar VT ablation, a wide range of strategies could be implemented to overcome the challenging that possibly occurred.

Keyword: VT ablation, pace-mapping, entrainment

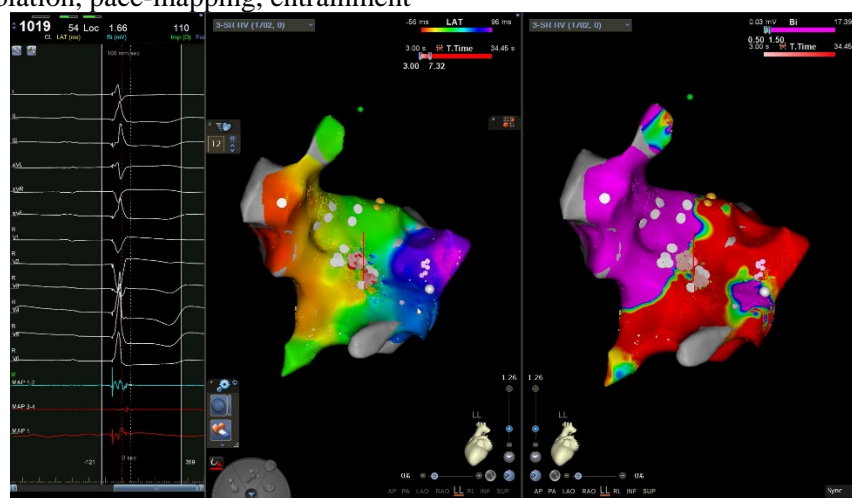


Figure 1. VT Ablation in Mid-RV Area

The Interplay Between Left Ventricular Non-Compaction Cardiomyopathy and Cardiac Arrhythmia: A Rare Case Series

A.K. Putri¹, E. Maharani², F. Hidayati²

¹Resident of Cardiology and Vascular Medicine, Gadjah Mada University/Sardjito General Hospital, Yogyakarta

²Staff Department of Cardiology and Vascular Medicine, Gadjah Mada University/Sardjito General Hospital, Yogyakarta

Background: Left Ventricular Non-compaction Cardiomyopathy (LVNC) is a rare genetic disorder characterised by prominent trabeculations and deep intertrabecular recesses in the left ventricle. This condition can lead to various complications. Electrocardiogram abnormalities are commonplace in LVNC and may be associated with mechanisms for arrhythmogenesis. The patients are at higher risk for sudden cardiac death, even with normal ejection fraction.

Case Illustration: We report a case series of 3 patients who presented to our hospital with heart failure with LVNC diagnosed by echocardiography and cardiac magnetic resonance. The first case was 66 years old male with the symptoms of heart failure. Transthoracic echocardiogram showed dilated all chamber, low ejection fraction of 21% and LVNC features. Coronary angiography showed non-significant coronary artery disease. Cardiac CT revealed hypertrabeculation in the left ventricle, while cardiac MR showed a ratio of non-compacted to compacted left ventricle of 8.3 (diastolic phase) at the anterolateral segment. The ECG of this patient shows atrial fibrillation. The patient received anticoagulants, antiarrhythmics, and heart failure treatment. The second case was a young male, 23 years old male with heart failure and malignant arrhythmia. He was referred after the ECG showed torsade de pointes (TDP). Holter monitoring demonstrates non-sustained ventricular tachycardia (VT). Cardiac MR showed hypertrabeculation in the left ventricle with a low ejection fraction of 23%. The third case was 21 years old female admitted to the emergency room with a history of syncope and seizure. Unlike the previous cases, this patient showed a preserved ejection fraction with a normal cardiac chamber. Prominent myocardial trabeculation at the left ventricle was shown from Cardiac MR. She was found to have monomorphic VT with unstable hemodynamics. It was reverted after cardioversion 100 Joule was done, and therapy was continued with lidocaine drip and propranolol. However, she had refractory VT.

Conclusion: In conclusion, Left Ventricular Non-compaction Cardiomyopathy predisposes individuals to develop various arrhythmias due to structural abnormalities in the left ventricle. These arrhythmias pose significant risks for adverse cardiovascular events and require careful management from medication to device therapy to prevent sudden cardiac death.

Keywords: Left ventricular noncompaction, LVNC, ventricular arrhythmia, atrial fibrillation

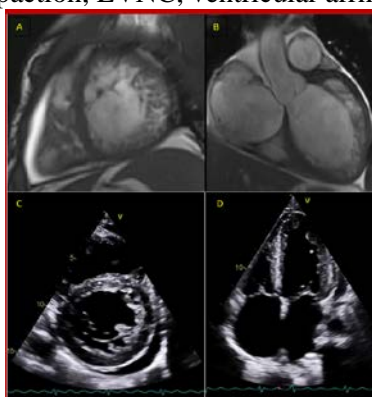


Fig 1. **A and B.** Cardiac magnetic resonance (CMR) showing dilated LV with trabeculations, recesses. **C and D.** Echocardiography showing heavy trabeculation at short axis view and 4 chamber view.



Navigating the Storm: Innovative Use of HD Mapping Ablation in Managing Recurrent Ventricular Tachycardia in ARVC

A. Kurniawan^{1,2}, A. J. Firdaus^{1,2}, S.S. Baskoro^{1,2}, A. Rizal^{1,2}, A.F. Rahimah^{1,2}, S.B. Raharjo^{3,4}

¹Department of Cardiology and Vascular Medicine, Faculty of Medicine Universitas Brawijaya, Malang, Indonesia;

²dr. Saiful Anwar General Hospital, Malang, Indonesia;

³Faculty of Medicine, Universitas Indonesia, Jakarta, Indonesia;

⁴National Cardiovascular Center Harapan Kita, Jakarta, Indonesia

Background: Arrhythmogenic right ventricular cardiomyopathy (ARVC) is a rare but significant inherited cardiac disease. It is characterized by fibrofatty infiltration of the right ventricle and a propensity for ventricular arrhythmias. The diagnosis of ARVC is multifaceted, relying on a combination of clinical, electrocardiographic, imaging, and pathological criteria. One of the major challenges in managing ARVC is the recurrent nature of the arrhythmias, which often prove resistant to conventional management strategies.

Case illustration: We present a complex case of a 39-year-old male with a history of recurrent ventricular tachycardia (VT) who had undergone multiple hospitalizations and cardioversion attempts. Despite these interventions, the patient's arrhythmias persisted. A Holter monitor revealed multifocal PVCs with a dominant RVOT anterior endocardial origin, suggesting a complex arrhythmic focus. A cardiac MRI showed late enhancement in various regions, indicative of ARVC. The patient's EKG during VT was also consistent with major ARVC criteria. Given the patient's reduced ejection fractions (LV EF of 45.2% and RV EF of 31.5%) and the complexity of the arrhythmias, a novel approach was needed. We opted for catheter ablation using HD Mapping, a cutting-edge technique that provides high-resolution, three-dimensional electroanatomic maps. This technique allows for more precise identification of the arrhythmic substrate and targeted ablation, which has been shown to improve success rates in complex arrhythmias. Through careful mapping and selective ablation maneuvers, we were able to successfully eliminate the ventricular tachycardia.

Conclusion: This case underscores the potential of HD Mapping ablation techniques in managing complex recurrent arrhythmias in ARVC patients. It highlights the need for innovative approaches in rhythm management and the importance of personalized treatment strategies in improving patient outcomes. Our experience suggests that with careful patient selection and the use of advanced mapping techniques, catheter ablation can be a viable option for patients with ARVC and recurrent VT.

Keywords: Arrhythmogenic right ventricular cardiomyopathy, ventricular tachycardia, catheter ablation, HD mapping, personalized treatment

Total atrioventricular block in a 50-year-old-female patient with Non-ST-Elevation acute coronary syndrome: half a loaf is better than none

A.N. Krediastuti¹

¹General Practitioner, Amal Sehat Hospital, Slogohimo, Wonogiri, Central Java

Background: Acute coronary syndrome is one of the common diseases in the emergency unit that has various complications including arrhythmia. The disease itself is indeed hard to be handled by the doctor in rural area, and get more complicated when the arrhythmia presents. We described a case of total atrioventricular (Av) block in Non-ST-Elevation acute coronary syndrome (NSTE-ACS) patient that did not end up in a mortality, but might persist with the morbidity in the future for the limited therapy and evaluation tools that we had.

Case Illustration: A 50-year-old-female patient presented with symptom of chest pain since a day before visiting the emergency unit. The vital sign showed blood pressure of 110/70 mmHg, heart rate of 40 beats/minute and normal respiration. The ECG finding showed total Av block with ST depression and T inversion in lead V1, V2, V3, V4. The laboratory finding for troponin I was negative. Because the troponin I was only qualitative the presence of NSTEMI could not be excluded. Regarding the very high-risk category for this patient, we educated her to be transferred to the Centre hospital in the first place. However, the patient refused to be referred and was then transferred to the High Care Unit. She was given dual antiplatelet of aspirin and clopidogrel. She got injection of sulphas atropine until maximum doses and was continued with continuous infusion of dopamine. Fondaparinux injection was given subcutaneously for 3 days. After 5 days in the hospital the patient was managed to be discharged. She was again educated to go to the Centre Hospital to be evaluated but still refused.

Conclusion: As an emergency unit doctor in rural area, we often put into difficult situation where we can't give the ideal therapy but still have to treat optimally. Despite its progress, cardiovascular disease management disparities are real. The continuing development in cardiovascular field should be followed by the effort to make it accessible for all, including those in the rural area. A networking program in cardiovascular disease management should be built to make a smoother referral procedure soon.

KEYWORDS: total Av block, management, rural area



ST-Elevation Myocardial Infarction with symptomatic bradycardia: the huge challenge of its management in rural hospital leading to inevitable mortality

A.N. Krediastuti¹

¹General Practitioner, Amal Sehat Hospital, Slogohimo, Wonogiri, Central Java

Background: The incidence of ST-Elevation Myocardial Infarction (STEMI) are widespread from urban to rural area. While people in urban area are easily getting the first medical contact with cardiologist that can conduct thrombolytic and percutaneous coronary intervention (PCI), most people in rural area are facing the opposite. It often leads to a higher rate of morbidity and mortality. There are multiple factors that need to be addressed to make a better outcome for the patients in rural area with STEMI diagnosis. In this case report, we present a limited therapeutic management in rural area towards a 40-year-old-female patient of Inferior STEMI.

Case Illustration: A 40-year-old-female patient presented with symptom of chest pain 4 hours before visiting the emergency unit. She had history of uncontrolled diabetic. The vital sign showed blood pressure of 110/60 mmHg, heart rate of 48 beats/minute, and normal respiratory rate. The ECG finding showed sinus bradycardia with ST elevation in lead II, III and aVf as well as ST depression and T inversion in lead V5 and V6. The laboratory finding showed positive troponin I, and elevated blood glucose of 319 mg/dl. The patient was diagnosed with inferior STEMI complicating with symptomatic bradycardia and uncontrolled diabetic mellitus. She was given dual antiplatelet of aspirin and clopidogrel. Nitrate sublingual was given continued with nitrate and morphine continuous infusion. She got injection of sulphas atropine as well as rapid insulin therapy. Her family was educated to be referred at the Centre Hospital to have further therapy but they refused due to some considerations. The patient was then transferred to the High Care Unit. Not long afterward, she had a cardiac arrest, the cardiopulmonary resuscitation was performed with pulseless ventricular tachycardia and defibrillation was delivered but no signs of spontaneous circulation.

Conclusion: Management therapy of STEMI in rural area still faces some challenges. The limitation of pharmacological therapy and the unavailable of cardiologist are the main issues. Others are the rejection of patient's family towards referral due to the distant location of Centre Hospital and the difficulty to get the referral timely.

KEYWORDS: STEMI, therapy, rural area

Case report: PVC Inducing Ventricular Tachycardia in Patient with Mild Hypokalemia

A.N. Moekoe¹, A. Rizal²

¹ General Physician at Wava Husada Hospital, Kepanjen, East Java

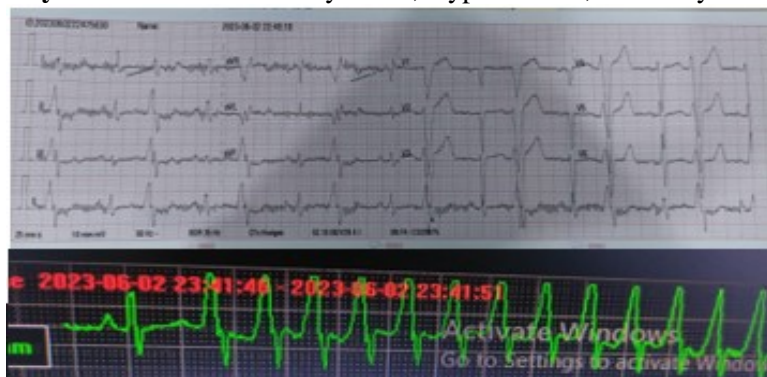² Arrhythmia Consultant, Cardiologist, Cardiology Department at Wava Husada Hospital, Kepanjen, East Java

Introduction: Potassium is one of many important electrolytes in charge of maintaining cardiac rhythm especially in terms of repolarization. Hypokalemia typically resulted in ST depression, T inversion, or U wave presentation, in which the probabilities of more fatal arrhythmias are increased. Many antiarrhythmic drugs affect cardiac potassium current. Careful choice of antiarrhythmic drugs is needed to avoid life-threatening arrhythmia.

Case report: 48 years old woman came to ER presented with recurrent dizziness for two days before admission. No history of chest pain, syncope, cold sweat was reported. Physical examination was unremarkable, with normal blood sugar. The patient was treated as vertigo and was given diphenhydramine and ondansetron. An hour after admission she complained of worsening dizziness, palpitation, and chest pain. ECG record showed sinus rhythm, with monomorphic bigeminy PVC, QT was hard to evaluate due to many artifacts and flattened T wave, without ST depression, T inversion, or U wave, hemodynamic was stable. Briefly after that, repeat ECG showed period of self terminating non-sustained VT (NSVT) of approximately 5 to 10s duration, patient was still awake with stable hemodynamic. Amiodarone infusion was started, and electrolyte serum was checked. However, periods of NSVT and PVC occurrence were still recurring. Lab results returned with mild hypokalemia of 3,4. KCl infusion was started, and amiodarone was changed into lidocaine infusion. Patient was assessed with VT with bigeminy PVC, and hypokalemia. KCl infusion was started, and amiodarone was changed into lidocaine infusion, and she underwent ICU admission. Patient reported no complaint and gradually QTc normalization in the next, repeat lab exam showed normokalemia of 4,2, patient was discharged on the fourth day and was arranged for outpatient control.

Conclusion: Hypokalemia may present with atypical ECG findings such as PVC, ventricular tachycardia, ventricular or atrial fibrillation, and torsades de pointes. Serum potassium correction and safe antiarrhythmic choices are also needed due to the risk of inducible malignant arrhythmia by some antiarrhythmic drugs.

Keyword: Ventricular tachycardia, Hypokalemia, Antiarrhythmic drugs



A Nightmare After First Dose of Sodium Channel Blocker for Paroxysmal Atrial Fibrillation

S. E. Nauli¹, A. N. Ramdhani¹

1. Cardiovascular Department, Tangerang District Hospital, Tangerang, Indonesia

Background: Propafenone is a class IC antiarrhythmic drug which usually used to treat various types of arrhythmia, commonly paroxysmal atrial fibrillation. It reduces cellular conduction activity by blocking the fast inward sodium channels. It also has beta-blocking and calcium-blocking properties. Cytochrome P450 2D6 complex (CYP2D6) in the liver is the main pathway to metabolize this drug. Propafenone toxicity is uncommon and could affect the multiorgan system, especially the cardiovascular system.

Case Illustration: A 54 years old Asian woman with paroxysmal atrial fibrillation was hospitalized for rhythm control. Previous medications were amiodarone, ace-inhibitor, MRA antagonist, beta-blockers, and oral anticoagulant. Initial evaluation showed stable and normal vital signs. Laboratory examination reports were unremarkable except for low TSH level with normal FT4 level and slightly elevated creatinine. During hospitalization, amiodarone was stopped due to thyroid toxicity, and low-dose propafenone was introduced. Unfortunately, 3 hours after the initial dose of propafenone, her level of consciousness decreased. She was hypotensive and bradycardia. Electrocardiography (ECG) showed junctional bradycardia with rates of 30-40 beats/min. Propafenone was stop. She was sent to the intensive care unit and treated with intravenous fluids, atropine, and dopamine. However, her heart rate did not respond to the medication. We decided to use a temporary pacemaker (TPM) for the patient. Following TPM placement, her vital signs and clinical condition improved. 48 hours after propafenone administration, her rhythm was gradually converted to sinus bradycardia. ECG evaluation showed myocardial ischemia. TPM was removed and she was discharged in stable condition several days later.

Conclusion: Propafenone toxicities are uncommon and the majority of them are caused by overdose following suicide attempts. Nonetheless, several cases were reported of propafenone toxicity at therapeutic doses. Medication that inhibits CYP2D6 could increase the plasma concentration of this drug. Additionally, slow metabolizer patient which has abnormalities of CYP2D6 is at risk of toxicity. Herein, we present a rare presentation of propafenone toxicity following the first low dose of propafenone.

Keyword: Toxicity, Propafenone.



Unravelling The Enigma: Decoding The J Wave in A Young Man

A. N. Valmai¹, I. Januartten², P. N. Permatasari³, D. A. Kurniawan⁴

¹General Practitioner, Malang Hasna Medika Cardiac Clinic, Malang, Indonesia

²General Practitioner, Malang Hasna Medika Cardiac Clinic, Malang, Indonesia

³General Practitioner, Baptis General Hospital, Malang, Indonesia

⁴Cardiologist, Malang Hasna Medika Cardiac Clinic, Malang, Indonesia

Background: The appearance of J wave in ECG is often found in healthy individuals. J wave have long been reported in hypothermia and hypercalcemia cases, but recently J wave has been reported in cases that usually associated with life threatening cardiac arrhythmia. There are two types of J wave syndrome, Brugada Syndrome (BrS) and Early Repolarization Syndrome (ERS). ERS is an early repolarization pattern ECG that associated with history VT/ VF in the absence of organic heart disease. Differentiating between J wave syndrome is the important key to considering further management.

Case Illustration: A 30-year-old male came to the emergency department with chest discomfort two days before admission. There were no dyspnea, palpitation, or history of syncope. He had an unremarkable medical history prior to his complaint and no previous family history. His vital sign was normal and no abnormalities found on physical examination. The ECG showed J point elevation in V2-6 according to early repolarization pattern. The serial ECG showed the same pattern. The Shanghai ERS score 2.5. Shanghai ERS score <3 excludes the diagnosis of early repolarization syndrome. It is challenging to diagnosed J wave appear in a young man patient. Using Shanghai score system for diagnosis of Brugada syndrome or early repolarization syndrome the J wave syndrome can be distinguished and appropriate treatment can be given immediately.

Conclusion : It really requires attention and further action if J wave is found in ECG especially if the patient has a history of syncope, sudden cardiac arrest, or family history related with ERS.

Keywords: J wave syndrome, Brugada syndrome, Early repolarization syndrome, Early repolarization pattern

The Crossroad in the Para-Hisian Accessory Pathway in Patients with Wolf Parkinson White Syndrome: Does A Risk of Pacemaker Dependency Justify Correcting Recurrent SVT?

A.P. Monika¹, F. Hidayati², E. Maharani²

¹Resident of Cardiology and Vascular Medicine Departement Faculty of Medicine, Universitas Gadjah Mada, Yogyakarta, Indonesia

²Staff of Cardiology and Vascular Medicine Department of Cardiology and Vascular Medicine, Faculty of Medicine, Universitas Gadjah Mada, Yogyakarta, Indonesia

Background: Radiofrequency catheter ablation (RFA) of the accessory pathway (AP) has been used to treat WPW syndrome with high success rates. Para-Hisian is one of unusual location AP in WPW syndrome associated with high risk complication of complete AV block during catheter ablation. We present two patients who presented with several episodes of palpitation due to WPW syndrome with para-Hisian AP those refused to continue to RFA after been told higher risk of total AV block.

Case Illustration: We presents two cases of WPW syndrome that the electrophysiology study (EPS) revealed the parahisian AP. First case is a 24 years old female with sudden onset and self limiting palpitation also. A 12 lead ECG showed sinus rhythm (SR) with preexcitation that suggested from anteroseptal (Figure 1A). During incremental pacing from RV, orthodromic AVRT was induced. TCL was 380 ms and the most fused A-V signal was at right posteroseptal (parahisian) (Figure 1C). Second case is a 54 years old male with history of chestpain prior syncope, sudden onset palpitation, and history of SVT that converted by cardioversion. A 12 lead ECG was SR with overt pre-excitation that suggested from posteroseptal TA and MA origin (Figure 1B). Mapping of AP at posteroseptal area showed the most fused A-V signal at posteroseptal of TA (His area). Incremental and programmed atrial & ventricular stimulation did not induce any tachyarrhythmia (Figure 1D). The ablation was not proceed due to very high risk of AV block and they are planned to perform the ablation with 3D mapping system.

Conclusion: Catheter ablation of para-Hisian APs can be challenging due to prone to mechanical block leading to the permanent pace maker with catheter manipulation. WPW syndrome with right septal or posteroseptal APs may cause LV dyssynchrony and jeopardize global LV function, therefore RFA of APs is expected to resulted in normalized QRS duration as well as mechanical resynchronization and improved LV function. RF delivery with low incremental energy is important and should be terminated immediately with onset of a junctional rhythm or persistence of AP conduction after 10 sec. There are some different approaches for ablation, including the inferior vena cava approach (IVC-A), the noncoronary cusp approach (NCC-A), or the superior vena cava approach (SVC-A), have been reported. When combining the right- and left-sided approaches, the success rate is higher. Cryotherapy also can be performed and has potential advantages to diminish the risk of heart block while ensuring efficacy with the 3D electro-anatomic mapping system to be an option.

Keywords: WPW syndrome, radiofrequency catheter ablation, para-Hisian accessory pathway

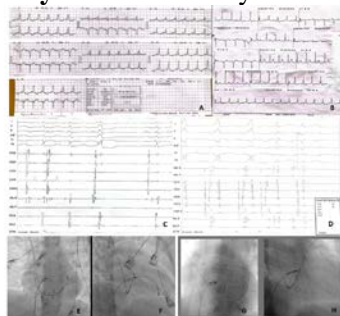


Figure 1. (A) Twelve-lead ECG of first case showed sinus rhythm with a short PR interval, negative delta wave at V1, positive

delta wave at I, II, III, aVL and aVF suggested from anteroseptal origin (B) and the second case ECG showed sinus rhythm with a short PR interval, negative delta wave at V1 and III, positive delta wave at I, II, aVL and aVF suggested from posteroseptal TA and MA origin. (C) Intracardiac electrograms of first case showed the most VA fusion at posteroseptal, (D) meanwhile in second case the EGM showed the most fused A-V signal at posteroseptal of TA (His area). (E&F) Fluoroscopic image during the EP study [left anterior oblique (LAO 30) and right anterior oblique projection(RAO 30)] forfirst case (G&H) and second case.



High degree AV block in a heavily calcified severe Aortic Stenosis

A Sejati^{1,2}, S Salim^{2,3}

1 Faculty of Medicine, Universitas Atma Jaya, Jakarta, Indonesia;

2 Department of Internal Medicine, Tzu Chi Hospital, Jakarta, Indonesia;

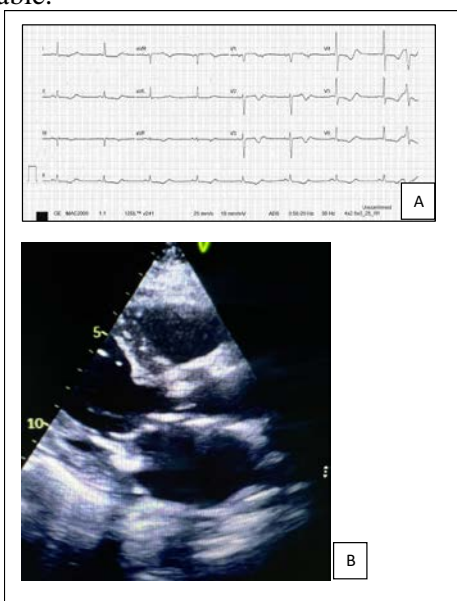
3 Faculty of Medicine, Universitas Indonesia, Jakarta, Indonesia.

Background: In the next decade, elderly patients will be the norm in Indonesia. They will suffer from multiple cardiovascular morbidities. Valve abnormalities, particularly severe aortic stenosis, are overlooked in relation to high degree AV block.

Case Illustration: A 73-year-old female presented to the cardiology clinic with worsening dyspnea over the previous week. She had a lengthy history of hypertension and a cerebral hemorrhage. She had been able to carry out daily activities with minimal assistance for the previous three months, and suddenly required full assistance for the past week. She denied chest pain, syncope/pre-syncope, and palpitations.

The patient appeared dyspneic on physical examination while sitting upright. BP was 160/70 mmHg, pulse was 42 bpm with occasional extrasystoles, and RR was 24 breaths per minute. JVP was distended. A murmur was detected at the right upper parasternal border during systole. The apical impulse remained intact. In addition, there is a significant enlargement of the right thyroid gland without a bruit. The sudden decrease in physical capacity and bradycardia prompted us to perform an electrocardiogram, which revealed a 2:1 block. (figure 1A) These findings will qualify patients for permanent pacemaker placement. Nevertheless, elderly patients with systolic murmur also prompted us to perform Echocardiography, which revealed a dilated left atrium, concentric left ventricular hypertrophy, a global normokinesia left ventricle with an LVEF of 69%, gr.2 diastolic dysfunction, severe aortic stenosis, (figure 1B) and mitral annular calcification. She was then advised to undergo both surgical aortic stenosis correction and implantation of a permanent pacemaker.

Conclusion: Both high degree AV block and severe aortic stenosis can result in decreased physical capacity. Although the sudden drop and bradycardia favor a high degree block as the cause, screening elderly patients for aortic valve disease is reasonable.



A Case of Wide and Narrow Complex Tachycardia with Cycle Length Alternans in Concealed Wolff-Parkinson-White Syndrome

A. Supit^{1,2}, D.Y. Hermanto¹, S.B. Raharjo¹, D.A. Hanafy¹, Y. Yuniadi¹

¹National Cardiovascular Center Harapan Kita, Jakarta, Indonesia;

²Dr. Soedarso General Hospital, Pontianak, Indonesia

Background: In Wolff-Parkinson White (WPW) syndrome, pre-excitation may not always be evident on electrocardiogram (ECG), potentially obscuring the presence of an accessory pathway (AP). Wide complex tachycardia may be manifestation of WPW syndrome. The evaluation of wide complex tachycardias (WCT) remains a great diagnostic dilemma commonly encountered by the physician.

Case Illustration: A 41-year-old man admitted due to history of recurrent episodes of palpitation. He had documented wide complex tachycardia of right bundle branch block (RBBB) pattern with left axis deviation, suggesting an idiopathic left ventricular tachycardia (ILVT). On the day of admission, he developed alternating wide and narrow QRS complex tachycardia which demonstrated Coumel's law. Tachycardia was terminated by amiodarone injection and ECG showed sinus rhythm without delta wave. During electrophysiological study, RBBB, LBBB pattern and narrow complex tachycardia (NCT) were inducible. A ventricular overdrive pacing maneuver was done, which resulted in a VAV response. This ruled out atrial tachycardia and with the finding of a PPI-TCL < 115 ms was in favor of an orthodromic AVRT utilizing an accessory pathway. Cycle length and VA interval were longer during RBBB tachycardia and shorter during LBBB tachycardia, indicating the presence of an orthodromic AVRT using an accessory pathway. Cycle length alternans with fixed VA interval was noted during narrow complex tachycardia, also suggestive of an accessory pathway. Earliest atrial activity was seen at distal his catheter and the most AV fusion was seen at anteroseptal tricuspid area. Two months later, radiofrequency ablation was successfully performed.

Conclusion: Identifying the etiology is essential to provide appropriate treatment. We report the case of a patient with no delta wave at resting ECG and documented ECG wide complex tachycardia. The presence of an accessory pathway hence the diagnosis of WPW syndrome became clear only after undergoing an electrophysiology study. In this patient, not only were pacing maneuvers able to demonstrate the diagnosis of an orthodromic AVRT, but also the Coumel's law and cycle length alternans during tachycardia were suggestive of AVRT. The phenomenon of Coumel's law also can facilitate identification and localization of a concealed accessory pathway.

Keyword: Wolff-Parkinson White (WPW) syndrome, wide complex tachycardia

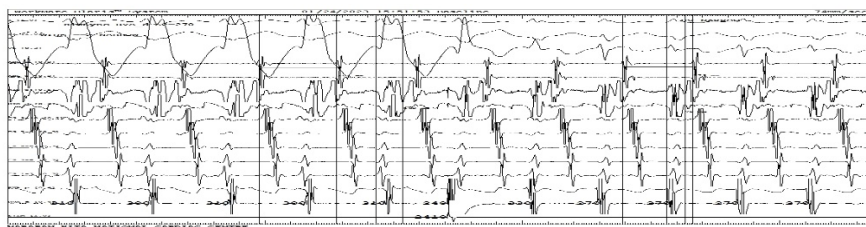


Figure 1. Wide to narrow complex tachycardia after single ventricular extra stimulus. Cycle length and VA interval were longer during RBBB tachycardia.

**Ventricular Bigeminy Rhythm due to Chronic use of Digoxin in Patient With Atrial Fibrillation:
Is It Digoxin Toxicity?**

A.T. Fadilla¹, D.S. Estiningsih^{1,2}, Irwan^{1,2}, H.D. Putra^{1,2}

¹Division of Cardiology and Vascular Medicine, Arifin Achmad General Hospital, Pekanbaru, Indonesia

²Departement of Cardiology and Vascular Medicine, Faculty of Medicine, Riau University, Pekanbaru, Indonesia

Background: Digoxin plays an important role in appropriately selected patients in AF with suboptimal rate control, worsening of symptoms, or quality life. Digoxin toxicity can be known although digoxin level can not be checked. Digoxin toxicity can cause any type of arrhythmia included ventricular bigeminy.

Case Illustration: A 50 y.o male came to Arifin Achmad hospital due to nausea, palpitations, and dizziness. He had rheumatic valve disease and medication from previous hospital was furosemide, spironolactone, digoxin, bisoprolol and warfarin. He had BP 130/80 mmHg, RR 25 x/min, SpO₂ 99%, HR 50x/min, and prolonged mid-late diastolic murmur at the apex. An ECG showed AF SVR, downsloping ST depression with reverse tick sign, and ventricular bigeminy. Laboratory examinations revealed Na 133 mmol/L, K 3.3 mmol/L, Ca 1.12 mmol/L. Serum digoxin level was not checked due to unavailability. TTE showed LA dilated, severe MS, moderate MR, mild TR, and good LV systolic function. Digoxin was omitted from treatment. Phenytoin and potassium chloride IV was given. He was symptomatically treated and improved well. The patient was discharged from hospital by initiating beta blocker.

Discussion: Digoxin can induce parasympathetic stimulation that slows the sinus rate. Impulse may shift to a latent pacemaker (escape beat) which can originate from ventricle and persistent impairment will allow a continued series of escape beats, termed an escape rhythm which is a protective mechanism. Effective sinus length that exceeds the sum of escape interval and the refractory period following the escape beat can cause escape-capture bigeminy. Hypokalemia increases digoxin sensitivity because potassium and digoxin compete for the same ATPase-binding site causing an increase in intracellular sodium and calcium so electrolyte correction is necessary. EKG findings commonly involve the downsloping ST depression with “reverse tick”, flattened, inverted, biphasic T waves, and shortened QT interval.

Conclusion: Chronic use of digoxin can cause digoxin toxicity which can be characterized by bradycardia and ventricular bigeminy rhythm. It can be recognized clinically and by ECG although serum digoxin levels cannot be checked. Electrolyte disturbance also increase digoxin toxicity so the treatment is required

Keywords: Ventricular Bigeminy, Digoxin Toxicity, Atrial Fibrillation

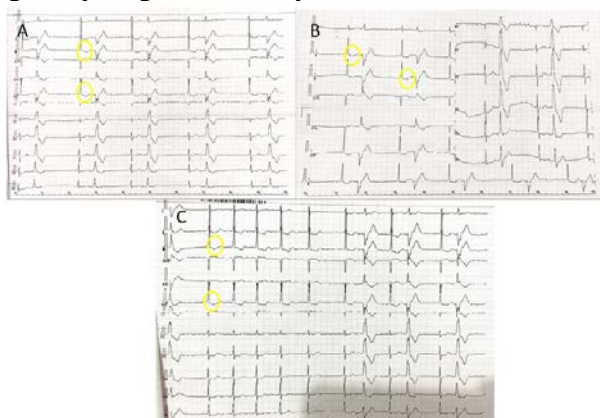


Fig 1. ECG showed downsloping ST depression with reverse tick sign (yellow circle) with (A) AF SVR with PVC bigeminy on the 1st day (B) AF NVR and PVC bigeminy on the 2nd day (C) AF NVR and some episodes of PVC bigeminy on the 3rd day

Ventricular Bigeminy Rhythm in Rheumatic Valve Disease Patient With Atrial Fibrillation: Is It Digoxin Toxicity?

A. T. Fadilla¹, D. S. Estiningsih^{1,2}

¹Division of Cardiology and Vascular Medicine, Arifin Achmad General Hospital, Pekanbaru, Indonesia

²Departement of Cardiology and Vascular Medicine, Faculty of Medicine, Universitas Riau, Pekanbaru, Indonesia

Background: Atrial fibrillation is a common complication of mitral stenosis. Digoxin plays an important role in appropriately selected patients in AF with suboptimal rate control (resting HR >110 bpm), worsening of symptoms, or quality life. Electrolyte disturbances can cause any type of dysrhythmia more likely even the serum digoxin level is within normal limits.

Case Illustration: A 50 y.o male came to general hospital due to shortness of breath on exertion and palpitation. He claimed that he had been suffering RHD since 2018. He had BP 130/80 mmHg, RR 25 x/min, SpO2 99%, HR 80x/min, and prolonged mid-late diastolic murmur at the apex. An ECG showed AF NVR, downsloping ST depression with reverse tick sign, and some episodes of PVC bigeminy. Cardiomegaly with hilar enlargement was found on chest x-ray. Laboratory examinations revealed HB 13.6 g/dl, Na 133 mmol/L, K 3.3 mmol/L, Ca 1.12 mmol/L, uric acid 11 mg/dl. TTE showed LA dilated, severe MS, moderate MR, mild TR with low probability of PH, and good LV systolic function. He was treated with furosemide 80 mg/day, spironolactone 25 mg/day, digoxin 0.25 mg/day, bisoprolol 2.5 mg/day, and allopurinol 100 mg/day. The patient was planned to have a mitral valve replacement but it was delayed due to being positive covid-19.

Discussion: Hypokalemia increases digoxin sensitivity because potassium and digoxin compete for the same ATPase-binding site causing an increase in intracellular sodium and calcium. It results in brief inward currents that generate the delayed afterdepolarization. If the amplitude of the delayed afterdepolarization reaches a threshold voltage, an action potential will be generated. Such action potentials can be self-perpetuating and lead to tachyarrhythmias. EKG findings commonly involve the downsloping ST depression with “reverse tick”, flattened, inverted, biphasic T waves, and shortened QT interval

Conclusion: Digoxin toxicity can occur when they are exposed to precipitating factors such as hypokalemia, hypomagnesemia, or hypercalcemia. The first management of digoxin toxicity includes stopping administration of the drug. However, it remains unclear what causes the arrhythmia in this patients. A previous ECG is needed to make it clear.

Keyword: Ventricular Bigeminy, Atrial Fibrillation, Digoxin Toxicity

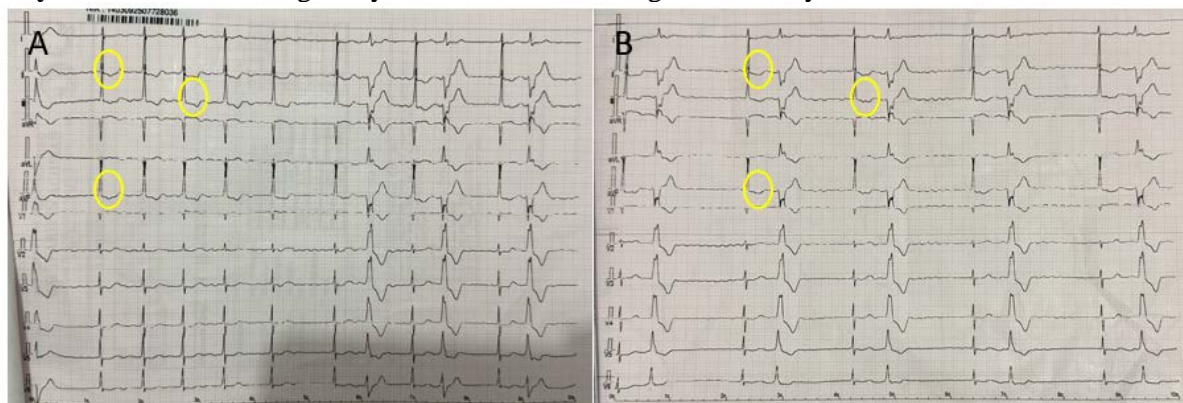


Fig 1. ECG showed downsloping ST depression with reverse tick sign (yellow circle) with (A) AF NVR and some episodes of PVC bigeminy on the 1st day (B) AF SVR and PVC bigeminy on the 2nd day

**Combination of Aminophylline Infusion and Salbutamol Inhalant in Management of
Bradyarrhythmia in Severe Hyperkalaemia in Chronic Kidney Disease Patients with Severe
Anaemia : A Case Report**

A. T. Pramadias¹, M. G. F. Harmani¹

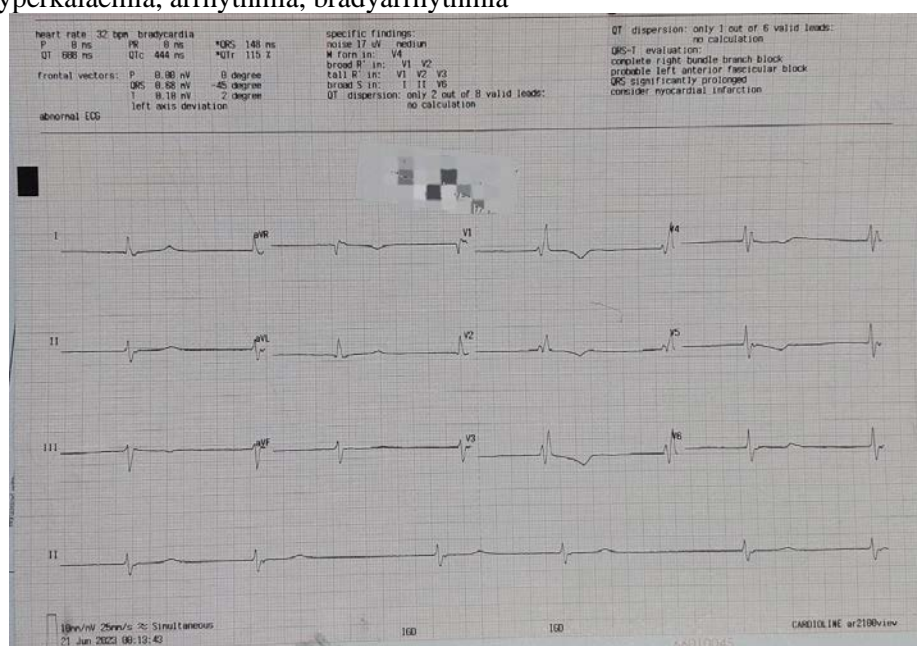
¹Adhyaksa General Hospital, Jakarta, Indonesia

Background: Hyperkalaemia is a life-threatening condition resulting in cardiac arrhythmia, including bradyarrhythmia with increased risk of mortality.

Case Illustration: 78-Year-Old woman presented to ER with chief complaint shortness of breath since 1 day ago. Shortness of breath worsened when lying down. Patient also had history of gastrointestinal bleeding 6 days ago of warfarin consumption. Patient had history of atrial fibrillation, chronic kidney disease and dyspepsia. Vital sign was unstable, blood pressure 74/54 mmHg, heart rate 24-38 bpm with typical signs of heart failure. The electrocardiogram showed AF SVR, sine wave pattern was not found. Lab results are hyperkalaemia 7.3 mmol, severe anaemia with Hb 4.1, and eGFR 10. Sulphas atropine 0.5 mg iv with maximum dose 3 mg, 10 mg insulin iv, 1 gr calcium gluconate iv, 50 cc dextrose 40% iv and 5 mg salbutamol inhalant were administered. Dopamine drip was given started from 15 mcg/kg. Temporary pacemaker and continuous renal replacement therapy was required, but reference hospital was not available. After 3 days of admission, heart rate remained low 40bpm with serum potassium 7.0 mmol. Aminophylline bolus 6mg/kg was administered followed by slow rate infusion 0.5 mg/kg/hour. Two days after aminophylline therapy, the electrocardiogram showed AF NVR with heart rate 100 bpm and serum potassium 3.6 mmol. Patient was discharged with good condition.

Conclusion: Hyperkalaemia should be suspected in patient with acute onset of bradyarrhythmia. Hyperkalaemia destabilizes myocardial conduction by decreasing the resting membrane potential, leading to arrhythmias. Several drugs can be used for the acute treatment of bradycardia. Aminophylline has positive chronotropic effects on the heart, likely mediated by inhibiting adenosine's suppressive effects the SA node. In a single trial, aminophylline infusion also resulted in a decrease in serum potassium. Beta-agonist both infusion and inhalant were effective to decrease serum potassium along with calcium gluconate, insulin, and glucose intravenous.

Keyword: Hyperkalaemia, arrhythmia, bradyarrhythmia



HYPERKALAEMIA-INDUCED BRADYARRHYTHMIA: WHEN TO PACE PERMANENTLY?

A. Taufiqah¹, A. I. Supit², D. S. Prahasti²

¹General Practitioner, Cardiology and Vascular Medicine Department, Dr. Soedarso Regional Public Hospital, Pontianak, Indonesia

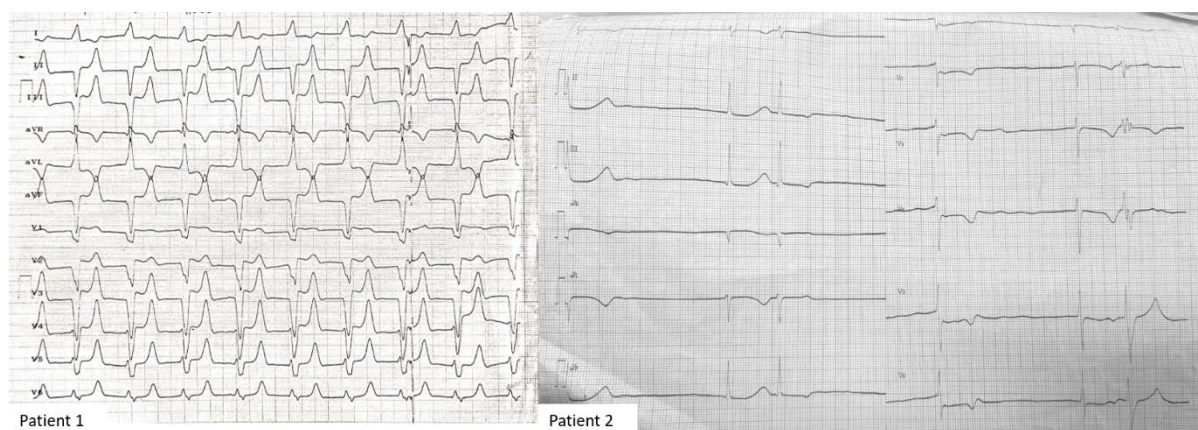
²Cardiologist, Cardiology and Vascular Medicine Department, Dr. Soedarso Regional Public Hospital, Pontianak, Indonesia

Background: Hyperkalaemia is one of electrolyte disturbances that causes malignant bradyarrhythmia. Hyperkalaemia could develop in advanced heart failure patients whose treated with MRA and ACE-I /ARB/ARNI and chronic kidney disease (CKD) patients. Hyperkalaemia sometimes goes unrecognized until it causes death.

Case Illustration: A 62-year-old woman was admitted to ER due to recurrent syncope. ECG showed total atrioventricular block (TAVB) with ventricular escape rhythm. She was also diagnosed with CKD and receiving routine haemodialysis. Laboratory work-up was significant for potassium level of 7.39 mmol/L. In ER, she was given a total of 3 mg intravenous atropine sulphate and hyperkalaemia therapy, but the bradyarrhythmia persisted. The patient then underwent temporary pacemaker. ECG on day 3 showed a return to sinus rhythm. However, despite correction of hyperkalaemia, bedside ECG monitor showed intermittent bradyarrhythmia, thus after further discussion and the patient live in remote area, we decided to implant permanent pacemaker on day 7. A 72-year-old man was admitted to ER due to syncope and dyspnoea on exertion. He was hypotensive. ECG showed atrial fibrillation with slow ventricular response, 30-40 bpm. He had a history of mitral and tricuspid valve replacement. Laboratory result was significant for potassium level of 5.91 mmol/L. He was given atropine sulphate, dopamine and dobutamine infusion and hyperkalaemia correction. Since the symptoms persisted, the patient then underwent TPM insertion. When hyperkalaemia resolved, bradyarrhythmia also resolved, therefore the TPM was pulled out.

Conclusion: Hyperkalaemia is a life-threatening condition if left untreated. Routine examination and correction of hyperkalaemia can be considered as the alternative initial management before the insertion of the cardiac pacemaker. Physician's consideration is important to assess the patients' needs prior to pacemaker implantation

Keywords: Total AV Block, Hyperkalaemia, Permanent Pacemaker, Temporary Pacemaker



Sudden Onset of Arrhythmia in Patient on Chemotherapy: a Case Report

A. Taufirachman¹, Ruswandiani², P. P. Nugraha³

¹General Practitioner of Kramat 128 Hospital, Jakarta, Indonesia

²Cardiologist of Kramat 128 Hospital, Jakarta, Indonesia

³Anesthesiologist of Kramat 128 Hospital, Jakarta, Indonesia

Background: Paclitaxel-carboplatin is standard chemotherapy for women with ovarian cancer. The addition of bevacizumab to standard chemotherapy improved the outcome. However, here we report the case of a patient who developed a sudden arrhythmia one week after chemotherapy.

Case Illustration: A 56-year-old woman with ovarian cancer was brought to the hospital with complaints of abdominal pain and vomiting. The patient had undergone her first chemotherapy session with bevacizumab, paclitaxel, and carboplatin one week prior. The patient had a history of stroke and hypertension and regularly consumes bisoprolol and rivaroxaban. Previously, the patient did not experience chest pain, shortness of breath, or palpitations. Physical examination was found normal. First ECG upon admission showed normal sinus rhythm with T-wave inversion in V1-3. Chest X-ray showed cardiomegaly with elongation of aorta, echocardiography found good LV and RV function. Laboratory tests revealed severe pancytopenia, with normal electrolytes and kidney function. On the second day, the patient started decreasing consciousness, shock, and tachypnea. The patient was transferred to the ICU and intubated due to respiratory failure. The following day, the patient suddenly developed visible arrhythmia on the monitor as shown in Figure 1 (A). When ECG was about to be performed, the rhythm on the monitor changed to supraventricular tachycardia. Synchronized cardioversion was performed, and later ECG showed idioventricular rhythm. Shortly after, the patient went into cardiac arrest and resuscitation was initiated. Unfortunately, the patient passed away.

Conclusion: The sudden onset of arrhythmia in this patient is likely due to chemotherapy and its cardiotoxicity. However, a more comprehensive evaluation is still needed to explore other possible causes. The balance between chemotherapy's effectiveness and cardiotoxicity risk requires collaboration between oncologists and cardiologists.

Keyword: Chemotherapy, Arrhythmia

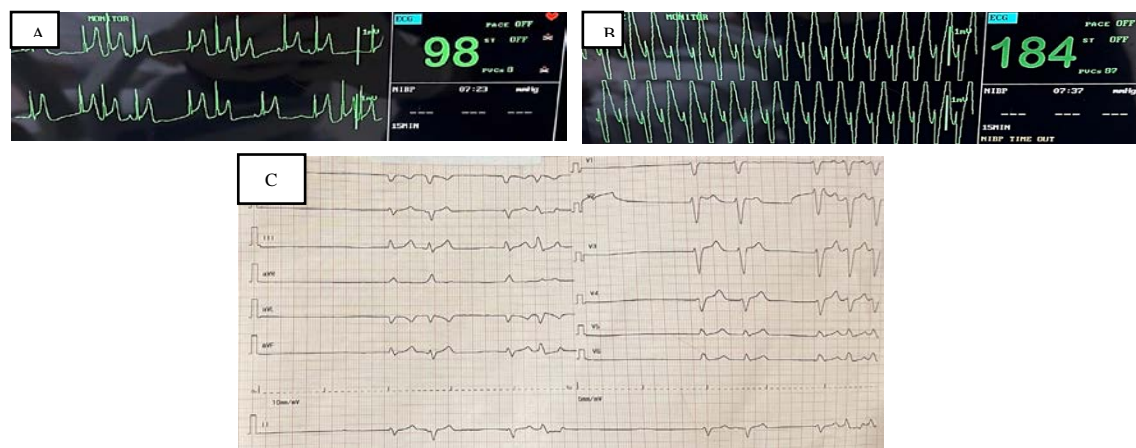


Figure 1. Sinus rhythm with PAC showed on the monitor (A);
The rhythm changes to supraventricular tachycardia (B);
ECG post cardioversion showed idioventricular rhythm with multifocal PVC (C)

Nasopharyngeal Swab Induced Vagal Maneuvers In A Patient With Supraventricular Tachycardia : Is it Accidental?

A.Taufirachman¹, N.Atikah¹, Ruswandiani²

¹General Practitioner of Kramat 128 Hospital, Jakarta, Indonesia

²Cardiologist of Kramat 128 Hospital, Jakarta, Indonesia

Background: Using nasopharyngeal swabs has been a standard procedure for determining the appropriate ward in hospitals for years during the COVID-19 pandemic. Here we report the case of a patient that provides the reader a valuable insight into the pathophysiology of atrioventricular nodal re-entry tachycardia (AVNRT) and vagal maneuvers to treat this phenomenon.

Case Illustration: A 49-year-old woman with a history of controlled type 2 diabetes and hypertensive heart disease came to the Emergency Department with shortness of breath. The patient has a history of routinely taking aspirin, amlodipine, bisoprolol, captopril, clopidogrel, isosorbide dinitrate (ISDN), metformin, and nitroglycerin. Upon arrival, the initial electrocardiogram (ECG) showed supraventricular tachycardia with a heart rate of 152 beats per minute (bpm). During the COVID-19 pandemic, a nasopharyngeal swab was used to determine the appropriate ward. After the nasopharyngeal swab, the cardiac rhythm converted to a sinus rhythm with 80 bpm. The patient's shortness of breath decreased, and vital signs improved. Later, laboratory tests indicated normal electrolyte levels, kidney function, and cardiac enzymes. Chest X-ray revealed cardiomegaly and echocardiography showed good right ventricular (RV) and left ventricular (LV) functions. The nasopharyngeal swab can cause stimulation known as the trigeminal cardiac reflex (TCR). TCR is a vagally mediated brainstem reflex that manifests as sudden alterations in blood pressure, heart rate, and respiration manifested by apnea, hypotension, bradycardia, and asystole as a result of stimulation of any of the branches of the trigeminal nerve along their course leading to increased parasympathetic activity and remission of atrioventricular re-entry tachycardia.

Conclusion: Nasopharyngeal swab may lead to increased parasympathetic activity in the atrioventricular node and its bradycardia effect cause conversion of supraventricular tachycardia to sinus rhythm.

Keyword: Nasopharyngeal swab, vagal maneuvers, supraventricular tachycardia, atrioventricular nodal re-entry tachycardia, sinus rhythm, trigeminal cardiac reflex

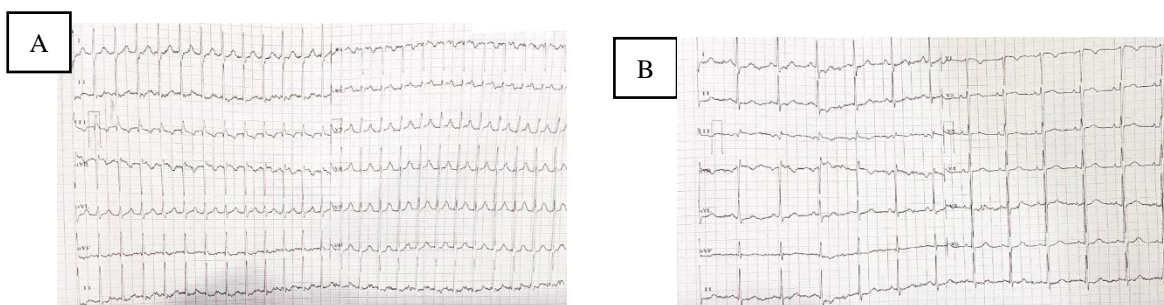


Figure 1. The ECG upon arrival showed supraventricular tachycardia (SVT) (A); ECG after nasopharyngeal swab convert to sinus (B)

Unveiling the Cardiac Challenges: Sinus Node and AV Node Dysfunction in Systemic Lupus Erythematosus

A.W.Hudoyo¹, E. Maharani², F. Hidayati²

¹Resident of Cardiology and Vascular Medicine Department, Sardjito General Hospital, Yogyakarta

²Arrhythmia Staff of Cardiology and Vascular Medicine Department, Sardjito General Hospital, Yogyakarta

Background: Systemic lupus erythematosus (SLE) is a multisystem disease with various potential adverse effects, including cardiovascular system. Conduction disorders may occur primarily as progression of SLE and secondarily from medications used to treat SLE. Progressive infiltration of fibrosis or granulation tissue is believed as mechanism of SLE-induced conduction defects.

Case Illustration: 16 years old girl referred with itchy in the whole body, chest pain, and sudden onset of gum bleeding. In the ER, low heart rate (30 bpm) with ECG showing junctional rhythm was detected. Laboratory revealed strong positive ANA-IF, low C3, C4 complement and increased anti ds-DNA antibody (37.5 U/ml) with total EULAR/ACR score 28 indicating SLE. Echocardiography showed good LV (EF 67%) and RV function (TAPSE 18mm), small PDA, diameter 3mm, L to R shunt and mild pericardial effusion. Patient treated with methylprednisolone pulse regiment used for severe SLE. On the day 7 of steroid treatment, atrial rhythm and total atrioventricular block (TAVB) with junctional escape rhythm manifested. This finding was confirmed with 24-hours Holter examination. At first, myocarditis was thought to be the cause of the conduction abnormalities. However, MRI cardiac contrast displayed no sign of acute myocarditis. Plasmapheresis was performed in hope of reversing the conduction disorders. In the observation, TAVB still persisted even after twice protocol of plasmapheresis. Permanent pacing is then indicated in the patient with symptomatic AV block attributable to a known potentially reversible cause when AV block does not resolve despite treatment of the underlying cause. Based on the consideration, permanent pacemaker (PPM) VVIR was implanted. After PPM implantation, her symptoms improved and patient is currently undergoing intensive SLE treatment.

Conclusion: Conduction disorders manifested as sinus node dysfunction and AV node dysfunction is uncommon complication of SLE. Although some conduction defects may resolve after treatment of the active phase of SLE flares, patients who are particularly symptomatic may require careful evaluation for the possibility of pacemaker implantation.

Keywords: systemic lupus erythematosus; TAVB; atrial rhythm; SND; AVND; myocarditis



Exercise Induced ARVC in Young Woman: Athlete's Heart?

A. Y. Amany, H. H. Satoto, A. Yudanto¹

¹ Department of Cardiology and Vascular Medicine, Medical Faculty of Diponegoro University, Kariadi General Hospital Semarang, Indonesia

Background: Arrhythmogenic Right Ventricular Cardiomyopathy (ARVC) is a leading cause of sudden death among young athletes but can affect people of all ages and all activity levels. Intense sports activity leads to the adaptation of cardiac structure and function, called athlete's heart. These changes usually comprise a balanced dilatation and hypertrophy of all four cardiac chambers

Case Illustration: A 57-year old woman presented with skipped heart beat without episode of syncope or palpitations since a year ago. She has hypertension. She worked as a police woman and used to had endurance exercise. Holter monitoring revealed multifocal PVCs suggesting ARVC. Echocardiography showed all chambers dilatation, with normal LV and RV systolic function. MRI revealed low RV volume with fibrofatty replacement of the RV myocardium suggesting ARVC with small fibrotic area at endocardium. ICD was not warranted due to insurance coverage issue.

Conclusion: ARVC is a relatively under-recognized hereditary cardiomyopathy, and it is important to recognize the ECG findings of ARVC and another imaging modality could help to distinguish either it was physiological or pathological RV remodelling. Diagnosing ARVC is still challenging to encounter rare pathological entities with clinical findings, for its importance of further investigations and management. Although Athlete's heart usually constitutes a balanced dilation and hypertrophy of all four chambers, there is increasing evidence that intense endurance activity may particularly tax the right ventricle (RV), both acutely and chronically.

Keywords: ARVC, exercise, Athlete's heart

**Successful Ablation of Double Accessory Pathway:
A Rare Case of Coexistence between Right Inferoseptal WPW and Left Lateral AVRT**

A. Yudha¹, P. Ardianto¹

¹Department of Cardiology and Vascular Medicine, Faculty of Medicine,
Diponegoro University – Dr. Kariadi Central General Hospital, Semarang, Indonesia

Background: Double accessory pathways, characterized by the presence of two abnormal conduction pathways in the heart, are an exceptionally rare occurrence. We present a unique case of a patient with dual accessory pathways, one demonstrating Wolff-Parkinson-White (WPW) syndrome utilizing the right inferoseptal pathway, and the other manifesting atrioventricular reentrant tachycardia (AVRT) through the left lateral pathway. This case report aims to describe the diagnostic and therapeutic approach employed, as well as the successful ablation of the double accessory pathway.

Case Illustration: A 51-year-old male presented with recurrent episodes of palpitations, and intermittent dizziness. Electrocardiography (ECG) revealed a pre-excitation pattern consistent with WPW syndrome, a delta wave was observed, with a negative deflection in V1, transitional zone in V2, and negative in lead III AVF, indicating an accessory pathway through the right inferoseptal pathway. Further evaluation with electrophysiological study (EPS) confirmed the presence of accessory pathways, with the right inferoseptal pathway exhibiting pre-excitation during sinus rhythm.

RFA successfully eliminated the right inferoseptal accessory pathway, the coronary sinus propagation was changes from concentric to eccentric pattern indicating another accessory pathway from left lateral. Another mapping was performed at mitral annulus retrogradely. VA fusion was found at left lateral area and demonstrating inducible AVRT. RFA successfully eliminated the left lateral accessory pathway, and the final result showed retrograde block.

Conclusion: This case underscores the importance of a comprehensive diagnostic approach in patients with dual accessory pathways. Successful ablation of both the right inferoseptal WPW and left lateral AVRT pathways was accomplished, leading to the resolution of symptoms and prevention of potential arrhythmic complications. This report highlights the effectiveness of EPS-guided RFA in managing complex arrhythmias and emphasizes the significance of thorough evaluation and individualized treatment strategies for patients with rare accessory pathway configurations.

Keywords:

Wolff-Parkinson-White syndrome, atrioventricular reentrant tachycardia, accessory pathway, double pathway, radiofrequency ablation.

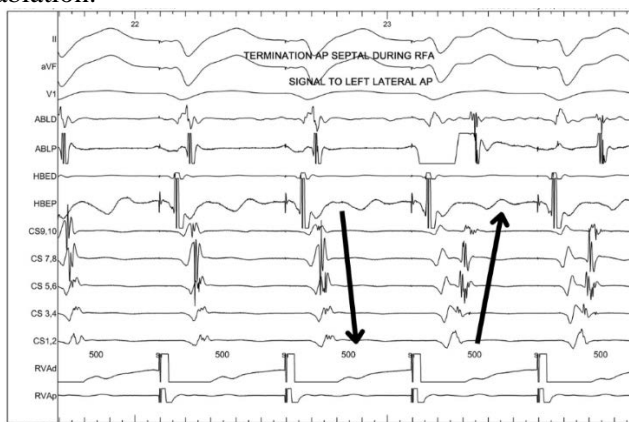


Figure 1. The coronary sinus propagation was changes from concentric to eccentric pattern.

Total AV Block on Coronary Artery Disease Post Percutaneous Coronary Intervention Right Coronary Artery : What Should We Do ? Permanent Pacemaker or Revascularization? A Case Report

B. A. Wicaksana¹, D. S. Christabella¹, C. Y. Silitonga²

¹General Practitioner, dr. Drajat Prawiranegara General Hospital, Serang, Banten, Indonesia;

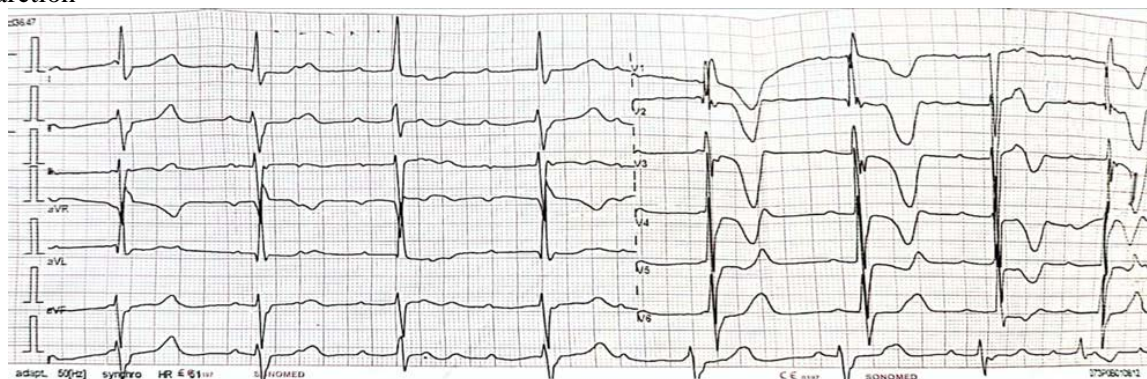
²Cardiologist, dr. Drajat Prawiranegara General Hospital, Serang, Banten, Indonesia

Background: AVB happens when the heart conduction is partially or completely blocked and can be caused by CAD. Blockage on RCA (type IV anatomy) compromises blood flow to septal branches of LAD and AV node which is significantly associated with severe conduction disturbance. PPM implantation needs to be considered for patients with symptomatic AVB, but reversible causes must be evaluated and managed first. In AMI, being one of AVB etiology, revascularization is more appropriate before PPM implantation.

Case Illustration: A 55-year-old man came to the emergency department with general weakness since a day before admission. He also complained of nauseous, vomiting and loss of appetite. There were no chest pain or shortness of breath. Patient had history of CAD, gone through PCI 6 months prior to admission and consumed carvedilol daily since then. Physical examination showed bradycardia of 51 beats per minute. ECG was performed with result of total AV block. The patient was hospitalized for 4 days with the administration of dopamine IV. There were no changes in ECG during admission. Further laboratory findings showed patient had normal cardiac enzyme level (CKMB 19.5; Trop I <0.1) which excluded reinfarction as the cause of bradyarrhythmia. Patient was discharged after improvement of symptoms and was suggested for the possibility of PPM. During hospitalization, patient never felt any chest pain, shortness of breath, or any other sign that leads to AMI. Medication given was only to increase heart rate using dopamine infusion which never had any significance. This showed that the cause of TAVB was not AMI and revascularization was not performed. Beta-blocker use was also excluded as it is more associated with AF, sinus bradycardia/pauses and SSS than severe types of AVB. Other reversible causes, such as drug toxicity, Lyme disease or transient increase in vagal tone, were also excluded. Therefore, the possibility of PPM implantation should be considered.

Conclusion: PPM implementation should be considered for TAVB patients with CAD.² However, there is a possibility for revascularization if patient shows any sign of AMI. Reversible causes need to be excluded before making treatment decisions.

Keywords: Atrioventricular Block, Percutaneous Coronary Intervention, Cardiac Pacemaker, Myocardial Infarction



Coronary-Cameral Fistula Manifest as SVT with Aberrancy: A Tale of Steal Phenomenon

B. Dewanggi¹, N. R. Muttaqin¹, T. Viradanti²

¹Gatot Subroto Presidential Hospital, Jakarta, Indonesia

²Faculty of Medicine, Jenderal Achmad Yani University, Cimahi, Indonesia

Background: Coronary-cameral fistula (CCF) is a rare cardiac anomaly that is found in only 0.002% of the general population.¹ It is characterized by abnormal communication between the coronary artery and the cardiac chamber. Usually, patients with CCF are asymptomatic, and myocardial ischemia or arrhythmia related to fistula are uncommon.² In this report, we present a case of a CCF patient manifesting as SVT aberrant following acute coronary syndrome.

Case illustration: a 38-year-old man comes to ER with sudden onset palpitation accompanied by chest discomfort. He reports similar history that resolve spontaneously about 4 years ago. His only risk factors are male gender and his older brother with premature coronary arterial disease (PCAD). Blood pressure was 100/80 mmHg, HR 180 bpm regular, RR 18 times/min, with no sign of heart failure. The ECG showed wide QRS tachycardia and CRBBB morphology consistent with SVT aberrance. Troponin-I was positively increased. After administering intravenous amiodarone, ECG converted to sinus rhythm with deep T inversion on lead II-III-aVF and V3-V6. Transthoracic echocardiography demonstrated normal dimensions of all chambers, LVEF 63%, TAPSE 22 mm, and mild hypokinetic mid-anterior wall. The patient refuses to do angiography so he was treated conservatively. Two weeks after discharge, the treadmill stress test was performed to assess whether tachyarrhythmia was induced by exercise or ischemia. The results come back with a positive ischemic response without any arrhythmia. Angiography was performed and established multiple coronary-cameral fistulae from proximal RCA to RA and complicated by the small caliber of the RCA. Myocardial ischemia can occur in CCF patients as a result of the “steals phenomenon” in which coronary blood flow reduces due to pressure differences between two arterial beds.² This ischemia may induce tachyarrhythmia, thus further increasing heart rate and causing more coronary “steal”.³ This condition can create a vicious cycle that leads to potentially fatal arrhythmia like SVT with aberrancy.

Conclusion: Even if it's rare, the coronary steal phenomenon in CCF patients may induce life-threatening cardiovascular events.

Keywords: myocardial ischemia, coronary-cameral fistula, coronary steal phenomenon

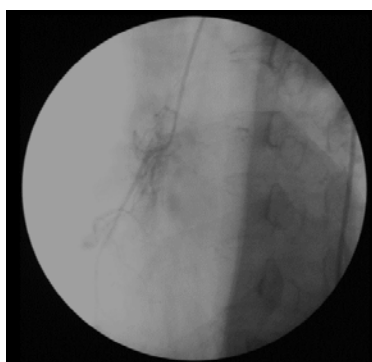


Figure 1. Plexiform coronary camera fistula from RCA to RA

Complete Heart Block with Loss of Pacemaker Capture Due to Lead Microdislodgement : A Case Report

B. J. Tando¹, R. Sukarya², B. Bintoro³, R. A. Manulang⁴, C. I. Rahayu³, Kornadi³

¹General Practitioner, Ciawi General Hospital, West Java, Indonesia

²Cardiologist, Ciawi General Hospital, West Java, Indonesia

³Consultant Cardiologist, Ciawi General Hospital, West Java, Indonesia

⁴Consultant Cardiologist, Siloam Kebon Jeruk Hospital, Jakarta, Indonesia

Background: Permanent pacemaker is a class I indication for complete heart block. With increasingly number of the case, basic understanding of troubleshooting for devices is essential.

Case Illustration: A 79 years male was referred to our hospital with dizziness and weakness since two days, with history of pacemaker implantation five months prior. He was alert, blood pressure 130/90 mm/Hg and heart rate of 38 bpm with 8mcg/kg/minute Dopamine. His ECG shows loss of pacemaker capture (Fig1). He denied manipulating the pacemaker. X-ray showed no significant changes on the device. We interrogated the pacemaker and found low impedance with high threshold. We further suspected lead dislodgment and confirming it by fluoroscopy.

Lead dislodgement management depends on the time of pacemaker implantation. In early displacements, reopening the pouch and lead reposition are possible since the distal end of the lead has not been caught and fixed by the endocardial fibrous reaction. In late displacements, surgical repositioning is often not feasible. The solution is to implant a new lead in the chamber in which displacement has occurred canceling the previous one. In this case, lead has not been fixed by endocardial fibrous, so lead repositioning via surgical repositioning was performed that provided good results.

Conclusion: Lead displacement is complication that has to be kept in mind for early approach whenever feasible. Postoperative follow-up should be carried out regularly to rule out any possible complications.

Keywords: Pacemaker, Lead Dislodgement, Complete Heart block

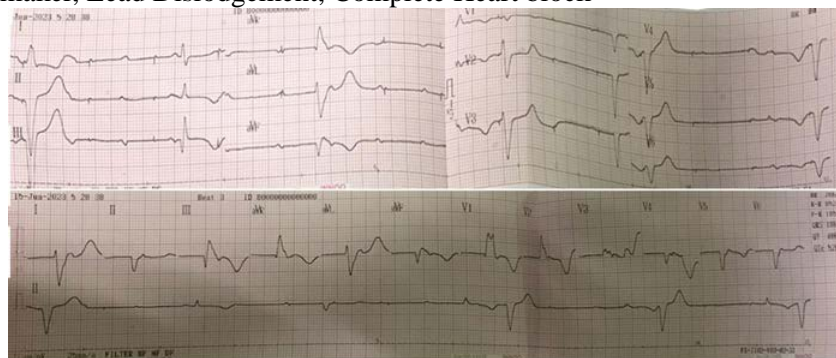


Fig 1. Complete Heart Block with Loss of Pacemaker Captures

Supraventricular Tachycardia in Woman with a History of Preeclampsia : Case Report

B.Kusumanti¹.

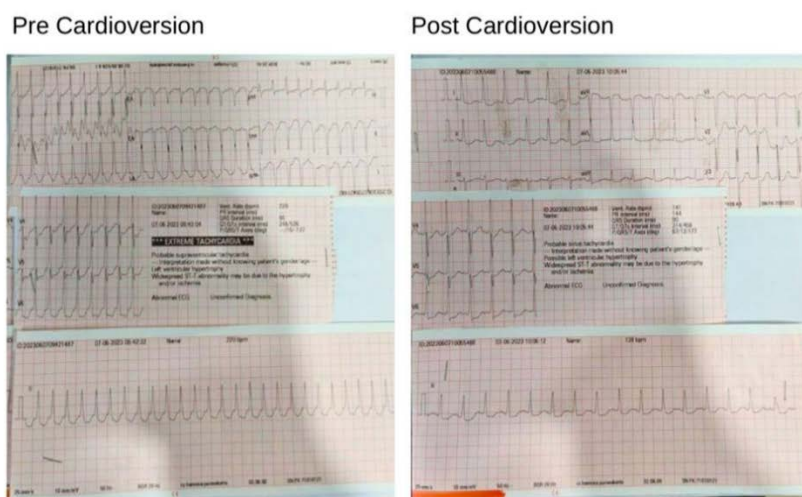
RSU Hermina Purwokerto, Indonesia

Background: Preeclampsia is associated with significantly higher prevalence of asymptomatic global left ventricular (LV) abnormal function/geometry and myocardial injury than uneventful pregnancy. Preeclampsia is also associated with significantly higher risk of subsequent heart failure, ischemic and hypertensive heart diseases, and related mortality compared with uneventful pregnancy. Hypertensive heart disease can manifest as many cardiac arrhythmias, both supraventricular and ventricular arrhythmias may occur in hypertensive patients, especially in those with left ventricular hypertrophy (LVH) or HF.

Case illustration: A 44 years old woman came to ER with complaints palpitation with dyspnea, there was no chest pain, but accompanied by cold sweat. She has history of preeclampsia and uncontrolled hypertension (after a period of preeclampsia). She denied history of thyroid disease. The clinical examination showed pulse rate of 220 /min with ECG showing presence of SVT and the hemodynamic BP 230/120 mm of Hg, RR 35/ min SpO2 94%, cold and calmmy acral. A vagal maneuver was performed but failed, then we did synchronized cardioversion 50 j successfully convert to sinus tachycardi 134/ min, followed by amiodarone maintenance dose of 1 mg/minute for 6 hours, furosemide 60 mg iv and ISDN 5 mg per oral.

Conclusion: Woman with preeclampsia are at significantly increased risk of asymptomatic LV dysfunction/hypertrophy and essential hypertension within 1 to 2 years after delivery. One of the principal manifestations of this progression is the change in the geometry and function of the left ventricle. Left ventricular hypertrophy is also the major determinant of the development of ventricular arrhythmias in hypertensive patients. One of the proarrhythmogenic features in LVH is the presence of early after depolarizations, which may trigger sustained arrhythmias. Activation of the sympathetic nervous system and RAAS are important components of the pathophysiology and development of LVH. Sympathetic activation may trigger ventricular arrhythmias. In unstable Spraventricular Tachycardia as in case, the best option is synchronized cardioversion.

Keywords: Supraventricular Tachycardia, Preeclampsia, Synchronized Cardioversion





Successful Cardioversion Unstable Supraventricular Tachycardia at Emergency Department with Many Limitations : A Case Report

B.V.K. Putri¹, Rasmijon², V.V. Amelya¹

¹Bhayangkara Hospital, Bengkulu, Indonesia

²Faculty of Medicine, Universitas Bengkulu, Bengkulu, Indonesia

Background: Supraventricular Tachycardia (SVT) indicates tachycardia with atrial rates >100 bpm at rest. Unstable SVT is a life-threatening emergency and must be treated immediately, especially when the patient first comes to the Emergency Department. Clinical signs and symptoms of unstable SVT include hypotension, hypoxia, shortness of breath, chest pain, shock or altered mental status.^{1,2}

Case Illustration: A 62 years old women came to the emergency department of Bhayangkara Hospital Bengkulu with chest discomfort since 3 hours before admission. The patient also complained palpitations, vomiting, light-headedness, and 2 periods of syncope. First syncope occurred 2 minutes, eight hours before admission. Second syncope occurred 5 minutes, three hours before admission. The patient was compos mentis with BP 78/55 mmHg, HR 197 - 202 x/min, oxygen saturation increased from 90% to 98% with oxygen 4 lpm. The ECG revealed regular narrow QRS <120 ms with hidden P – wave and atrial rates 197 bpm. We performed synchronized cardioversion 100 J. After cardioversion was performed, complaint of chest discomfort and palpitations were relief. The patient was compos mentis with BP 123/73 mmHg, HR 90 x/min. The ECG after synchronized cardioversion revealed sinus rhythm.

Conclusion: Cardioversion is the first choice in patients with unstable haemodynamic narrow QRS tachycardia. Immediate direct-current (DC) synchronized cardioversion allows the defibrillator to deliver the shock synchronized with the QRS complex. Cardioversion must be carried out as soon as possible by medical team at emergency department. Taking treatment immediately aims to restore the haemodynamic condition as soon as possible and to prevent patient with unstable SVT does not fall into more critical condition.^{1,3}

Keyword: Supraventricular tachycardia, Unstable haemodynamic SVT, Cardioversion

Symptomatic Bradycardia in Type B Wellens' Syndrome: When Early Reperfusion Is Not The Option

B.W. Jhundy¹, A. Sain²

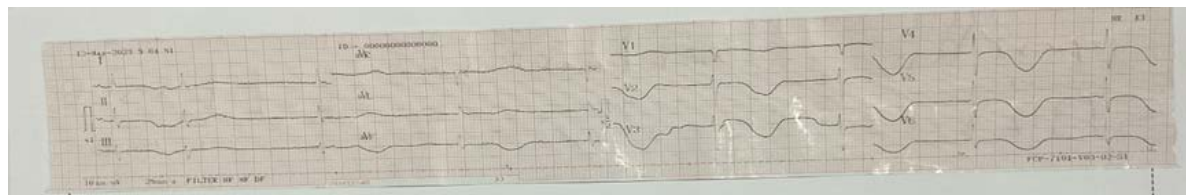
¹General Practitioner, Mitra Plumbon Indramayu Hospital, West Java, Indonesia; ²Cardiologist, Mitra Plumbon Indramayu Hospital, West Java, Indonesia

Background: Wellens' syndrome is associated with severe stenosis of the left anterior descending artery (LAD). Type B has an electrocardiographic (ECG) pattern of deeply inverted T-waves in leads V2-3 that can extend to involve any other precordial leads. In addition, absence of precordial Q waves is required and cardiac biomarkers are normal or slightly elevated.

Case Illustration: We present a case of a 64 year old female patient who came with typical cardiac chest pain which started 1 hour before presentation and a syncope episode before arrival in the emergency department. At triage, her vital signs were conscious, blood pressure of 90/60 mmHg and a heart rate of 43 beats per minute (bpm). Cardiovascular examination revealed bradycardia with irregular rhythm and the absence of any murmurs, rubs, or gallops. All other physical findings were unremarkable. ECG done at the time of admission showed deep and symmetrically inverted T-waves in leads V2-V3 including V4-V6 with a rate of 43 bpm. Patient was assessed with anterior STEMI equivalent Wellen Type B but refused to be referred to secondary hospital for further management. Loading dose of aspirin, clopidogrel, sublingual nitrate, intravenous atropine iv at the dose of 1 mg, dopamine 5mcg/kg/minute and subcutaneous fondaparinux were given. Laboratory test revealed a troponin I level of 0.02 ng/mL (normal reference level <0.03 ng/mL). Patient was discharged after four days of treatment with a heart rate of 66 bpm and disappearance of chest pain. In the outpatient unit after discharge, the patient finally agreed to be referred to a secondary hospital. Cardiac catheterization revealed coronary artery disease 1 vessel disease and she undergone percutaneous coronary intervention 1 drug eluting stent in LAD.

Conclusion: Wellens' syndrome STEMI equivalent is diagnosed with characteristic ECG findings even in the absence of ST elevation and non significant increase in cardiac enzymes. It should be promptly managed with the best treatment available involving patient decision to prevent extensive anterior wall infarction. Our patient had early recognition and intervention that enabled us to halt the progression of symptomatic bradycardia and potentially fatal anterior wall myocardial infarction.

Keywords: Symptomatic Bradycardia; type B Wellens' syndrome; STEMI equivalent; reperfusion



Tachycardia-Induced Cardiomyopathy: A Reversible Cause of Heart Failure

C.J. Hardi, M.D¹, D.A. Hanafy, M.D, PhD^{1,2}

¹National Cardiovascular Center Harapan Kita, Jakarta, Indonesia; ² Faculty of Medicine, Universitas Indonesia, Jakarta, Indonesia

Background: Tachycardia-induced cardiomyopathy (T-CM) is characterised by left ventricular (LV) dysfunction with subsequent heart failure from sustained or persistent tachyarrhythmias.¹ T-CM is an important cause of heart failure because of its reversibility with adequate rate control.² T-CM can manifest in the setting of either an incessant or paroxysmal tachycardia and should be suspected if no other cause of LV dysfunction is identified.

Case Illustration: A 55-year-old male was referred to the arrhythmia clinic for incessant tachycardia. He played tennis regularly and consulted a cardiologist due to sudden loss of endurance, complaining of progressive breathlessness during activity and orthopnea. Heart failure was diagnosed and his ECG was previously misinterpreted as sinus tachycardia due to acute heart failure. 12-lead ECG showed a regular, narrow QRS tachycardia of typical atrial flutter with 2:1 conduction without LV hypertrophy, Q waves or ST-T changes. Echocardiography was significant for mildly dilated LV, reduced LV function with an ejection fraction of 24% and moderate mitral regurgitation (MR). Transoesophageal echocardiogram confirmed no left atrial appendage thrombus and ablation was planned. An incessant, clockwise typical atrial flutter (atrial TCL 230 ms) was seen with positive entrainment at the cavotricuspid isthmus (CTI). A 3D geometry of the RA was constructed. Linear radiofrequency ablation (35W, 45°C, 17ml/min) was delivered point by point along the CTI using an irrigated ablation catheter, ECG converted to sinus rhythm during ablation. A bi-directional block was documented. Post-ablation, his symptoms improved. A follow up echocardiography after 1 month showed normal LV dimensions, improved LV function at 53%, and non-significant MR.

Conclusion: T-CM should be strongly considered in patients with persistent tachyarrhythmias, such as in this patient. Accurate ECG diagnosis of the tachycardia is important. Appropriate diagnosis of T-CM and cessation of tachyarrhythmias not only will reverse LV dysfunction with its associated morbidity, mortality, and cost, but most importantly, will improve quality of life and long-term prognosis.

Keywords: Atrial Flutter; Tachycardia-Induced Cardiomyopathy

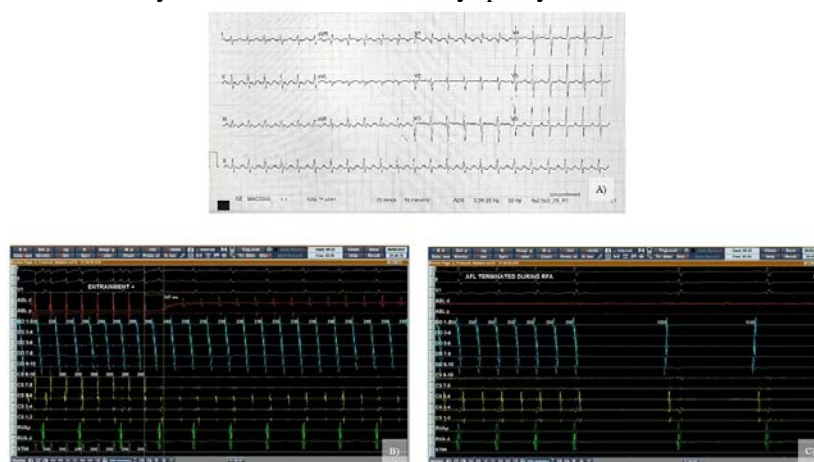


Figure 1 – 1a) Baseline 12-lead ECG showing a regular, narrow QRS tachycardia - typical atrial flutter with 2:1 conduction; 1b) Positive entrainment at CTI, PPI-TCL <20 ms; 1c) ECG converted to sinus rhythm during ablation at CTI.

Wide Complex Tachycardia in Acute Coronary Syndrome: Is It True Ventricular Tachycardia? A Challenging Case in Daily Practice

C. L. Putra, M. G. Perdana, F. Hanif, S. N. Irbah, J. Budiono, F. Ahmad, V. Pratama, N.A. Tafriend, Haikal, A. Harsoyo

Department of Cardiology, Gatot Soebroto Central Army Hospital, Jakarta, Indonesia

Background: To understand Wide Complex Tachycardia (WCT) (>140ms) we need to identify: R/S complex in precordial lead, R to S interval, AV-dissociation, and VT morphology.¹ In this case-report, we try to describe that not all wide-looking QRS is VT.

Case Illustration: A 45-year-old woman presented to the Emergency, with chief-complaints of angina for 3 days with classic risk-factor CAD: uncontrolled-hypertension, Type2-Diabetes-Mellitus(T2DM), and Dyslipidemia without alcohol and smoking. Vital-signs: Compos-Mentis(CM), Blood-Pressure(BP) 163/67mmHg, Heart-Rate(HR) 170BPM, Respiration-rate(RR) 22/minute, non-elevated JVP, obese grade-1, temperature 36,6°C, A2>P2, apex displaced 1cm lateral-LMCS. Laboratory-examination showed an increased high-sensitivity Troponin-I, blood-sugar, LDL-serum, ureum-serum, and creatinine-serum followed by decreased magnesium-serum, and normal limit HB and HCT. First ECG showed: regular likely WCT with QRS-complex(<120ms), ventriculoatrial-rate of 1:1 in lead V1, short-RP interval(40ms), with HR-173BPM (Typical-AVNRT). This patient underwent autoconversion to sinus-rhythm with ST-depression in leads I, aVL, V5, and V6. QS-pattern is seen in leads V1-3, and inverted-Twaves are seen in leads II, III, aVF, V5, and V6, with HR-95BPM. This patient had two-episodes of the same arrhythmia every 2-hours. X-ray in ED showed Left Ventricular Hypertrophy (LVH) with normal limits in other chambers. We diagnosed NYHA-I, Hypertensive Heart Disease grade-II, T2DM, Renal-Insufficiency, CAD(NSTEMI-TIMI4/7), and NCT(Typical-AVNRT) with hemodynamic-instability. Synchronized-cardioversion 50-joule with sedation for every episode, UFH-bolus 60IU/KgBw-IV with maintenance 12IU/KgBw-IV (PT-APTT target 1,5-2x control), Clopidogrel loading-dose 300mg-orally, Aspirin loading-dose 324mg-orally, Ramipril 10mg-orally, Bisoprolol 5mg-orally, Atorvastatin 40mg-orally, Novorapid-bolus 10U-SC, and Diazepam 2mg-IV are given in ED. Echocardiography in ICU showed MV-E/A<1, MV-DecT 161ms, Ejection-Fraction 44%(HFmrEF), RWMA, and LVH-concentric which showed diastolic-dysfunction grade-I and systolic-dysfunction. coroangiography showed normal LMCA, stenosis 70%–80% in proximal(1,0,0) with white-thrombus and diffuse stenosis 80%–90% in mid to distal(1,1,0) LAD, stenosis 80%–90% in distal(0,1,0) LCx, and stenosis 30%–40% in proximal(1,0,0) and 80%–90% in distal(1,1,0) RCA. This patient's syntax-score is-23. We considered CABG(IA-class) and PCI(IIIA-class) for this patient. We planned thallium-perfusion to consider reperfusion-therapy timing.

Conclusion: NCT sometimes mimics WCT, they require careful consideration in order to reach a definitive diagnosis. To clearly differentiate this case further investigation using an electrophysiology-study is needed.

Keywords: Wide Complex Tachycardia, Narrow Complex Tachycardia, Acute Coronary Syndrome, Electrophysiology-study

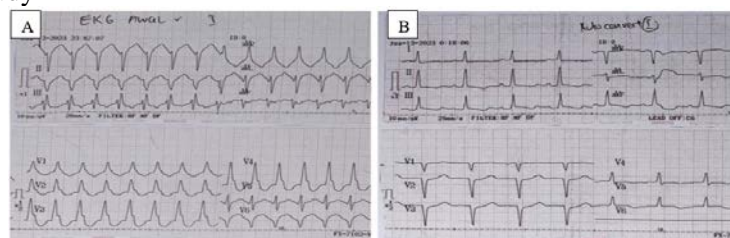


Figure 1: A: Regular likely WCT with QRS-complex(<120ms), ventriculoatrial rate of 1:1 in lead V1, short RP interval(40ms), with HR-173BPM (Typical AVNRT). B: Autoconversion to sinus-rhythm with ST-depression in leads I, aVL, V5, and V6. QS-pattern is seen in leads V1-3, and inverted-Twaves are seen in leads II, III, aVF, V5, and V6, with HR-95BPM.

**Coarse Atrial Fibrillation in Rheumatic Heart Disease: Rate versus Rhythm control,
What should we choose?**

C. Mulyawati¹, A.Z Widiastuti², M. Susanti³

¹General Practitioner, RSUD dr. R. Sosodoro Djatikoesoemo, Bojonegoro, Indonesia

²General Practitioner, Faculty of Medicine, Diponegoro University, Semarang, Indonesia

³Cardiologist, RSUD dr. R. Sosodoro Djatikoesoemo, Bojonegoro, Indonesia

Background: Atrial fibrillation is a typical tachyarrhythmia due to a complication of Rheumatic Heart Disease (RHD). Its presence is linked to a poor prognosis and increased mortality. As a preventable cardiovascular disease, RHD should be treated immediately. The efficacy and superiority of rhythm control over rate control have been demonstrated for treating symptomatic atrial fibrillation and maintenance of sinus rhythm but these strategies are not applicable to all patients. Some trials showed similar outcomes for both rhythm and control rate strategies but only in elderly patients.

Case illustration: A 33 years old man presented to the ER with shortness of breath, fever, painful of joints, and a cough since six days ago. Patient was smoker. Past medical history was denied. On physical examination BP 116/64, HR 110 bpm irregular, RR 26, SpO₂ 97% on 3 lpm NC, T 38.1 degrees, fine rales on the lungs, and murmur on auscultation of mitral valves. The ECG detected coarse atrial fibrillation with rapid ventricular response (RVR) and RAD. Chest x-ray were cardiomegaly with mitral heart configuration. Based on Jones Criteria patient was diagnosed with atrial fibrillation RVR with rheumatic heart disease (RHD). Blood culture was taken, empiric antibiotic with 12 gr Ampicillin and 3mg/kg/day of Gentamycin was given. Heart failure medication including Spironolactone, Furosemide, Candesartan, and Digoxin was prescribed. The patient was admitted to the intensive care unit and scheduled for echocardiography. There was severe mitral stenosis, moderate MR, mild TR, and RV systolic dysfunction in echocardiography. The Blood culture results were negative for any bacteria. The patient recovered after seven days of medical care.

Conclusion: There is no evidence that rhythm control, including medication, cardioversion, or catheter ablation, improved clinical outcomes. In contrast, patients treated with rate control demonstrated swift clinical improvement and decreased mortality at hospital discharge. These findings suggest that rate control strategies are becoming as safe and efficacious as rhythm control strategies, particularly in younger patients with AF and RHD.

Keywords : atrial fibrillation, rate control, rhythm control, rheumatic heart disease

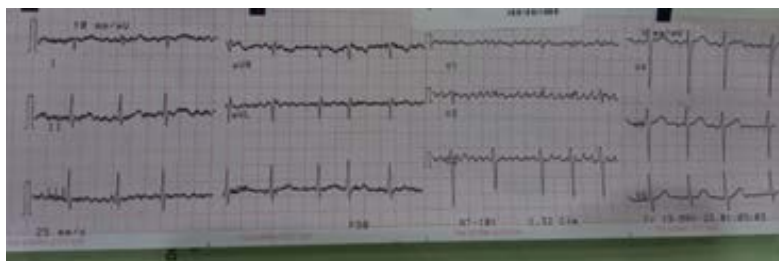

Figure 1. The ECG at ER showed coarse atrial fibrillation with rapid ventricular response (RVR)

Epicardial Accessory Connections Producing Posteroseptal Accessory Pathways

C. Rith, S. B. Raharjo

Division of Arrhythmia and Pacing, National Cardiac Center Harapan Kita Jakarta

Background: Accessory Pathway (APs) located in the posteroseptal and left posterior areas may be difficult to ablate according to relative epicardial localisation, thickness of the myocardium, anatomic complexity of this area and coexistence of a CS diverticulum. The patients with left-sided APs that were difficult to ablate from endocardial surface. It was difficult to find the most fused or absence of an AP potential while endocardial mapping, so the CS may be a useful marker of subendocardial pathway localized in the atrioventricular groove. CS anatomy should be carefully assessed. Irrigating ablation catheter was placed inside the CS venous system and mid cardiac vein is effective in most epicardial posteroseptal APs. The regions of accessory pathway are visualized with ventricle pacing to see the most fused, the effective target site was 2-3cm within the CS os. In this case, AP potentials were absent or small in amplitude from endocardium, but a large AP potential was recorded withing the CS.

Case Illustration: 27 years old man with episode of palpitation and syncope. No family medical history. From the Holter examination showed infrequent PVC, episode of SVT. Echocardiography examination showed normal cardiac finding. MRI was done before ablation showed not match with ARVC. On the surface EKG, we suspected that the patient has VT with wide complex tachycardia, no RS in precordial lead and present the AV dissociation.

After the decapolar catheter was inserted and positioned in the CS, the most AV fused and the earliest V at CS 5-6 (left-sided AP). Aggressive atrial pacing induced wide complex tachycardia, eventually changed to narrow complex tachycardia with TCL 300 ms and no AV dissociation, the VT was excluded. Following this, the RVOP was performed by RVA pacing for 8 beats and then stop, the SVT continues after stop pacing, the results were VAV, PPI-TCL < 115 ms and VA interval was 106ms. Afterward retrograde pacing during sinus rhythm showed an eccentric retrograde conduction with the most VA fusion and earliest A at CS 5-6 (left lateral). Therefore the diagnosis was concealed orthodromic AVRT with LLAP.

One right femoral artery puncture was done and one 8F sheath was inserted. IV heparin was administered according to bodyweight intravenously. Mapping the AP location by retrograde aortic approach with irrigated ablation catheter advanced to mitral annulus, but unfortunately the catheter was stuck in chordae tendineae that we can't even move. Meanwhile we do an Echocardiography showed an acute mitral regurgitation and the patient became agitated and then Fentanyl was provided to calm down the anxiety and trying extract gently of the catheter. Finally, the catheter was taken out uncomplicatedly and reevaluate by Echocardiography again showed that no mitral regurgitation nor chordae rupture. Subsequently changed to antegrade approach by transseptal puncture. Mapping with non irrigated ablation catheter at CS 5-6 area during retrograde ventricular pacing. Multiple RFAs (40 watt, 60 C, 20 s) were delivered to this area during ventricular pacing. The fused A-V signal didn't separate during ventricular pacing. Simultaneously non irrigating catheter was replaced by irrigating catheter. Multiple RFAs (30 - 40 watt, 45 C, 120 s) were delivered to the CS 5-6 area during ventricular pacing. The fused A-V signal did not separate during ventricular pacing again. Next the irrigating ablation catheter was moved inside the coronary sinus and placed to CS 5-6 area (the earliest activation and the most fused was found within the venous system) at posteroseptal AP. Multiple RFAs (30 - 40 watt, 45 C, 60 s) were delivered, during ventricular pacing successfully separated the AV fusion within 1.3 second. Retrograde pacing showed a decremental retrograde conduction via AV node.

Conclusion: The coronary sinus was a myocardial coat with extensive connections to the posterior coronary vein or the middle cardiac vein that can connect to the left ventricular epicardium and form epicardial posteroseptal and left posterior AP. At this point if the APs that were difficult to ablate from the endocardial surface and its absence of AP potential during endocardial mapping, in combination with a relatively large AP potential with the most AV fused within the CS may be a helpful marker of subepicardial location.

Non-Sustained VT with Heart Failure: A Case Report

D. Ardelia¹, Z. Mukhtar²

¹Graduate Faculty of Medicine, University of North Sumatera, Medan, Indonesia

²Departement of Cardiology and Vascular Medicine, Faculty of Medicine, University of North Sumatera, Medan, Indonesia

Background: Ventricular tachycardia (VT) is a common arrhythmia in patients whose diagnosed with heart failure (HF). Patients with HF, half of the death are sudden due to life-threatening ventricular arrhythmias, including VT and the patients may present either with cardiac arrest to emergency department or with palpitations, syncope, chest pain, or implantable cardioverter-defibrillator (ICD) shocks to cardiology outpatient clinics, varying according to the hemodynamic stability of VT. Both non-sustained VT (VT duration <30 sec) and sustained VT (VT duration >30 sec) in patient with HF are associated with significant morbidity and mortality.

Case illustration: A female, 45 years old was referred with unstable condition without any shock sign. Her chief of complaint are chest pain and breathing difficulty. She's been diagnosed with HF with LVH, preserved EF, had several episodes of PVC and post stroke 1 month ago. She received treatment in the form of spironolactone, ramipril and bisoprolol but her adherence to taking medication was not good. During admission, her ECG shown non-sustained VT (NSVT). The patient received a bolus of 150 mg amiodarone in 50 cc D5% within 30 min and 80 mg of furosemide but the ECG still showing NSVT and increased heart rate, then proceed with administrated drip of 300 mg amiodarone in 250 cc D5% within 1 hour.

Conclusion: Patients with incidentally found NSVT require further evaluation. Patient with preserved EF and possibly underappreciated, burden of NSVT which confers a higher risk of mortality.

Keywords: Ventricular arrhythmia, Ventricular tachycardia, Non-sustained VT, Heart Failure

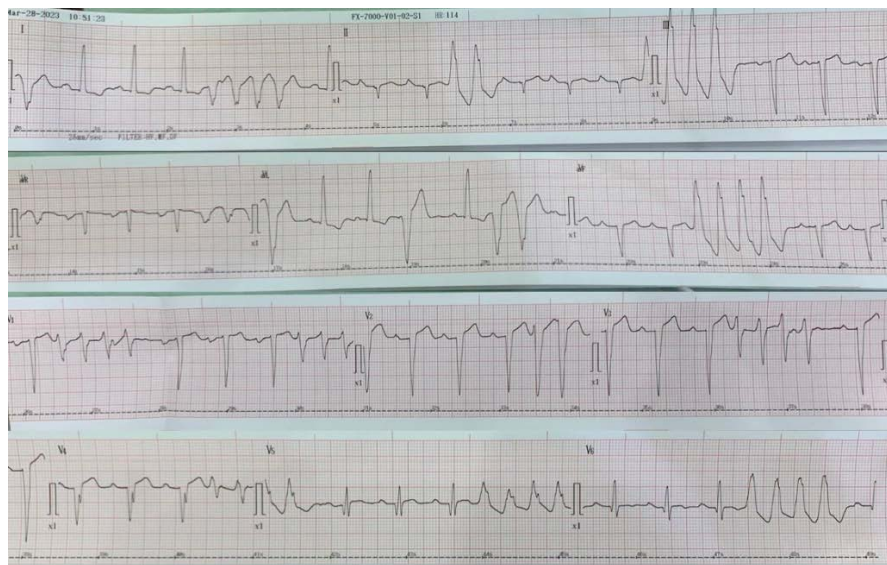


Figure 1. ECG on admission showing NSVT.

Atrial Fibrillation in patient with Leptospirosis: Challenging Case in Rural Area – A Case Report

Fergina.D¹, Ma'bud.T², Fitria.I³, Nugroho.B⁴

¹ General Practitioner, Malinau Regional Hospital, North Kalimantan, Indonesia; ² Clinical science program, Faculty of Medicine Chulalongkorn University, Thailand; ³ Internist, Malinau Regional Hospital, North Kalimantan, Indonesia; ⁴ Cardiologist, Tarakan Regional Hospital, North Kalimantan, Indonesia

Background: Leptospirosis is a zoonotic bacterial disease prevalent in tropical and subtropical areas, primarily affecting low-income populations. Cardiac disturbances are quite common and electrocardiographic abnormalities may be found in more than 70% cases of leptospirosis with atrial fibrillation, atrioventricular conduction blocks and non-specific ventricular repolarization abnormalities being the most common.

Case Illustration: A 44-year-old male farmer came to ER with complaints of shortness of breath, chest pain, and loss of appetite. There were no history of fever or any cardiovascular diseases. Patient was alert, BP 80/60, pulse 186 bpm irregular, respiration 30x/min, SpO₂ 72% room air. On examination, there were subconjunctival hemorrhage, icteric sclera, rales on lower lung bilateral, normal JVP. There were no Murmur, Gallop and Pretibial Edema. Abdominal exam within normal. Laboratory examination showed WBC 9700, platelet 145.000, AST 544/ ALT 520 IU/L, Urea 75 mg/dl, Creatinine 1,08 mg/dl, Blood Glucose 17 mg/dL, Troponin I negative, Hepatitis B/ C negative. ECG showed atrial fibrillation HR 180 bpm, and T inverted in V4-6. Cardioversion was done 3 times, rhythm was unconverted to sinus, but rate was down to 126 bpm. Norepinephrine, digoxin and bisoprolol were started, and the patient was admitted to ICU. On the 2-day of admission to the ICU, ECG serial showed atrial fibrillation with normal ventricular response and T inverted in all lead. IgM dan IgG Leptospirosis came positive. The patient was then treated with ceftriaxone 2 gr once daily, iv methylprednisolone. Echocardiography examination later revealed left atrium diameter and ejection fraction within normal limit. Patient had an uneventful recovery, but Atrial Fibrillation remained at a normal ventricular rate until the last day of admission.

Conclusion: Our patient presented with atrial fibrillation with leptospirosis, resulting in hemodynamic instability and management challenges. It may be a coincidence or could be an unusual complication of leptospirosis. It still hard to conclude whether atrial fibrillation induce by leptospirosis, or it was undiagnosed atrial fibrillation. However, close monitoring is essential for reducing morbidity and mortality outcomes.

Keywords: Leptospirosis, Atrial Fibrillation.

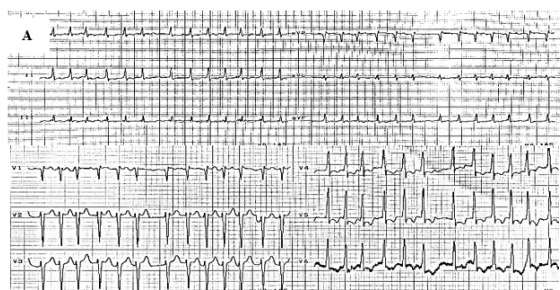
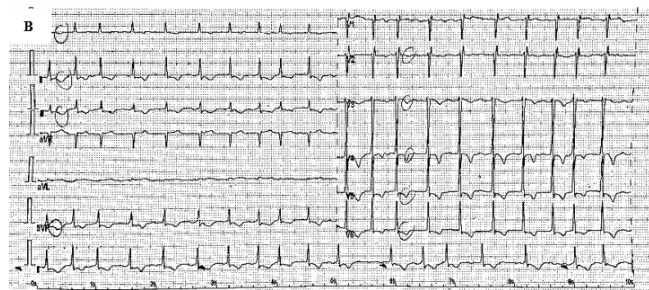


Figure A. ECG on admission in ER



B. ECG on 2nd day of admission in ICU

Epsilon Waves in an 11-Year-Old Patient with a Family History of Arrhythmogenic Right Ventricular Dysplasia on Implantable Cardioverter Defibrillator

D. H. Pradipta¹, B. A. Pramono²

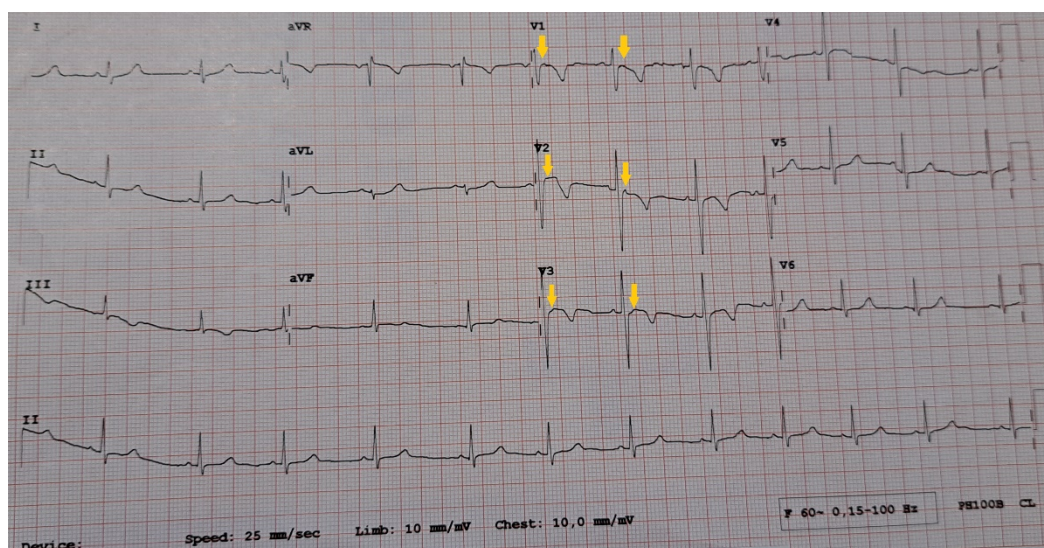
^{1,2}RSUD Panembahan Senopati, Bantul, Indonesia

Background: Epsilon wave is defined as a late potential wave occurring after the end of the QRS complex that is clearly located on the ST-segment. Epsilon waves is a rare phenomenon that can only be seen in a minority of patients with Arrhythmogenic Right Ventricular Dysplasia (ARVD). ARVD is an inherited progressive disease of the heart muscle that can cause dangerous arrhythmias and sudden death. In this condition, patients that considered at high risk for sudden cardiac death should receive an implantable cardioverter defibrillator (ICD). The diagnosis of ARVD is based on Task Force Criteria. This criteria is also important to detect early diagnosed of ARVD patients for preventing further complication.

Case description: An 11-year-old boy came to our clinic to do heart check-up because his father had a history of ARVD on ICD with recurrent VT. This boy was fully alert, blood pressure was 131/116 mmHg, heart rate was 60 bpm, respiratory rate was 18 bpm, body temperature was 36.3°C, SpO₂ was 98%, and had no physical complain. The electrocardiography showed normal sinus rhythm with the appearance of epsilon wave and T wave inversion in V₁₋₃. Echocardiography showed no kinetic abnormalities in the right ventricle and no dilation in RVOT.

Conclusion: In this case, there is a high possibility that this boy could be diagnosed with ARVD based on Task Force Criteria since that he had 1 major criteria (the presence of epsilon waves in V₁₋₃) and 2 minor criteria (family history in clinical diagnosis based on present criteria and inverted T waves in V₂₋₃). The echocardiography showed no abnormalities since this patient might still in early or silent phase. This stage is a subclinical phase with concealed structural abnormalities. This patient requires electrophysiology study and further examinations to make a certain diagnosis. Other family members, especially first-degree relatives need to assess their condition related to the issue of the inherited disease.

Keywords: arrhythmia, ARVD, epsilon wave



When the Cure Causes the Pain: Post-Cardiac Injury Syndrome Following Ventricular Tachycardia Ablation

D. J. Pesireron¹, D Nugraha², F Alkaff³, P Ardhiyanto⁴, A Yudanto⁵, S Sungkar⁶

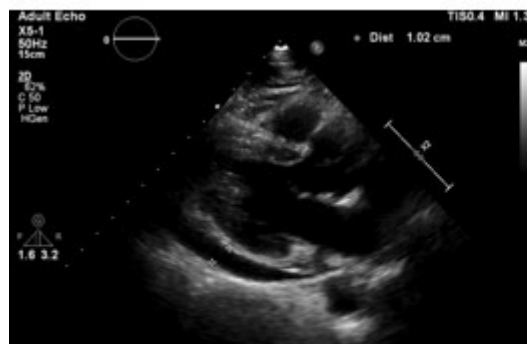
¹ Department of Cardiology and Vascular Medicine, ²Faculty of Medicine Diponegoro University- ³Dr. Kariadi Central General Hospital, Semarang, Indonesia

Background: Post Cardiac Injury Syndrome (PCIS) is an inflammatory syndrome secondary to cardiac injury that develop after percutaneous cardiac intervention such as catheter ablation. Acute post-ablation pericardial effusion as a manifestation of PCIS is a common complications of atrial fibrillation ablation but its occurrence following an uneventful ventricular tachycardia (VT) catheter ablation is rare.

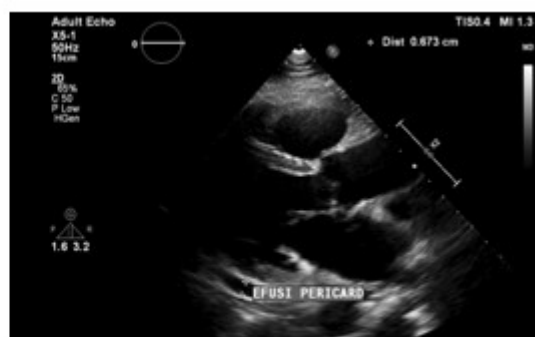Case Illustration: 47-year-old women with complaints of frequent palpitations. Holter monitoring showed frequent premature ventricular contraction (PVC) with episodes of non-sustained ventricular tachycardia. Patient was referred for an electrophysiological study and catheter ablation. During the procedure ventricular tachycardia (VT) with right ventricular outflow tract (RVOT) origin was recorded. A total of four radiofrequency (RF) burns were applied to the anterior and posterior-mid septal region of RVOT. In the following day, the patient had a severe chest discomfort with a slight dyspneu, relieved when she's leaning forward. 12 lead ECG examinations showed ST elevation in almost all lead (lead I, II, III, avF, avL, V4-V6), with PR depression. Laboratory findings showed elevated CRP and Troponin, Transthoracic echocardiography revealed circumferential pericardial effusion. The patient was diagnosed with PCIS and initiated on NSAID, steroid and low-dose colchicine. At a 5-day follow-up, the patient was free of symptoms and the pericardial effusion was diminished.

Conclusion: Pericarditis as a manifestation of Post Cardiac Injury Syndrome (PCIS) although rarely occurred following a VT catheter ablation, can still happen. Early identification and prompt treatment is vital to mitigate the complication.

Keyword: Post cardiac injury syndrome, inflammation, ablation, pericardial effusion



TTE Post Ablation



TTE Follow Up



Hyperkalemia, Junctional Bradycardia Effect Routine Use Spironolactone in CHF Patient without Electrolyte Evaluation

D. Kartikasari¹, Y. Astuti²

¹ General Practitioner, Pelita Husada Hospital

² Department of Cardiology and Vascular Medicine, Pelita Husada Hospital

Background: The routine use of spironolactone in patients with congestive heart failure (CHF) without evaluating their electrolyte levels can lead to the development of hyperkalemia.

Case illustration: A 71-year-old male presented to the emergency room following a syncopal episode in front of his house. He complained of weakness, dizziness, tremors, and cold sweats. The patient had a history of CHF. On examination, his blood pressure was 110/80 mmHg, pulse rate was 35 beats per minute, respiratory rate was 26 breaths per minute, and oxygen saturation was 77%. An electrocardiogram (EKG) revealed junctional bradycardia with a heart rate of 33 beats per minute. Laboratory results confirmed hyperkalemia. To address this, we administered D40% 2 flash and 10 IU of insulin intravenously. Over the first 4 hours, potassium levels gradually decreased from 8.40 to 6.86, followed by a further decrease to 5.82 over the subsequent 4 hours. Potassium plays a critical role in regulating the normal electrical activity of the heart. Elevated extracellular potassium levels decrease myocardial excitability, affecting both pacemaking and conducting tissues. Progressive hyperkalemia suppresses impulse generation by the sinoatrial (SA) node and impairs conduction through the atrioventricular (AV) node and the His-Purkinje system, resulting in bradycardia, conduction blocks, and potentially cardiac arrest. In this case, the administration of D40% 2 flash and 10 IU of intravenous insulin led to a gradual decrease in potassium levels and notable clinical improvement. Although initial administration of 10 IU IV insulin effectively lowered potassium levels, it also carried the risk of inducing hypoglycemia. The combination therapy of D40% 2 flash and 10 IU IV insulin effectively mitigates the risk of hypoglycemia. Moreover, this treatment approach has demonstrated effectiveness as an initial therapy in our hospital, which lacks immediate access to dialysis facilities.

Conclusion: In situations where immediate dialysis is unavailable, non-dialytic therapy involving the administration of 10 IU IV insulin is a viable solution for hyperkalemic patients. The combination of D40% 2 flash and 10 IU IV insulin effectively addresses concerns regarding hypoglycemic effects. This treatment approach has proven efficacy and can serve as an initial therapy option, particularly in healthcare facilities without immediate dialysis capabilities.

Keywords: Hyperkalemia, Junctional Bradycardia

Case Report: Premature Ventricular Contraction (PVC) Couplets After Electrical Cardioversion of Monomorphic Ventricular Tachycardia with Hemodynamic Instability

D. L. Mulya¹, A. Gabriella²

¹General Practitioner, Emergency Department, RSUD Dr. Adjidarmo, Lebak, Banten

²Cardiologist, Cardiovascular Department, RSUD Dr. Adjidarmo, Lebak, Banten

Backgrounds: Premature Ventricular Contraction (PVC) couplets is defined as an early ventricular beat that appears two beats in a row. This condition can induce wide QRS tachyarrhythmia such as ventricular tachycardia (VT) with hemodynamic disturbance such as loss of consciousness, hypotension, cardiac type of chest pain and shortness of breath. This case is usually found in emergency room settings, delayed diagnosis and treatment can lead to cardiac arrest with a high mortality rate.

Case Illustration: A 55 years old male came to the emergency room with experience of sudden palpitation and shortness of breath one hour before admission. He had a past medical history of coronary arterial disease (CAD) 14 years ago and was taking medication routinely, and he had controlled diabetes type II. Based on examination in the emergency room, he is fully conscious, blood pressure 118/85 mmHg, Heart Rate 209 bpm, respiratory rate 28 times in one minute, the ECG shows regular wide QRS complex with same shape of QRS waves and it concluded as monomorphic ventricular tachycardia. He got cardioversion using 100 Joules under sedation of midazolam injection 4 mg, after intervention the ECG showed sinus rhythm with premature ventricular contraction (PVC) couplets. The patient administered amiodarone injection 150 mg followed by amiodarone continuous infusion 360 mg for 6 hours and 540 mg for 18 hours. One day after care, the ECG shows sinus rhythm without any PVC wave. After five days of inpatient care, he was discharged from the hospital with stable condition without any complaint.

Conclusions: PVC couplets are suspected to be the cause of the monomorphic VT in this patient, the PVC couplets may result from scarred myocardial tissue as a result of an old myocardial infarction. Administration of amiodarone is effective to prevent recurrent PVC and VT. Further examination is required for evaluation and confirmation of the cause couplet PVC.

Keywords: Ventricular Tachyarrhythmia, Monomorphic Ventricular Tachycardia, Electrical Cardioversion, Premature Ventricular Contraction

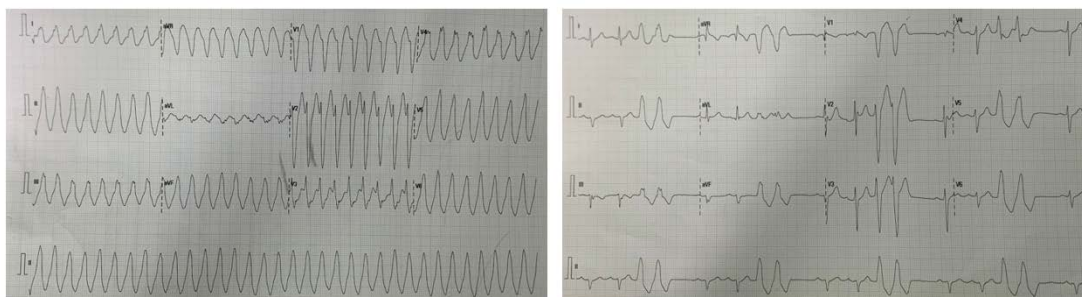


Figure 1. (Left) ECG 12 lead show monomorphic ventricular tachycardia (VT), (Right) Direct ECG 12 lead after electrical cardioversion show sinus rhythm with premature ventricular contraction (PVC) couplets

A Malignant ventricular arrhythmia immediate after permanent pacemaker implantation, what could be the diagnosis?

D. Lestari¹, A. Rizal²

¹Cardiology Resident, Faculty of Medicine Universitas Brawijaya- Saiful Anwar Hospital, Malang, Indonesia

²Departement of Cardiovascular Medicine, Faculty of Medicine Universitas Brawijaya-Saiful Anwar Hospital, Malang, Indonesia

Background: Current studies reported an incidence of 12-31% ventricular arrhythmias during cardiac pacing months or even years after pacemaker implantation. Patients with coronary artery disease or reduce ejection fraction often increase the risk of ventricular arrhythmias (25–40% of cases). We reported a case of malignant ventricular tachyarrhythmias following pacemaker implantation.

Case Illustration: This case concerns a 78-year-old female who was referred from a private Hospital with general weakness and frequent syncope. History of uncontrolled hypertension, type II DM, and menopause. Electrocardiography showed a complete heart block with a narrow junctional escape rhythm and decided temporary pacemaker (TPM) insertion. Chest radiography showed cardiomegaly. Transthoracic echocardiograms (TTE) revealed EF 56% by teich and regional wall motion abnormality. During observation, there was no improvement in condition. Therefore, permanent pacemaker implantation was decided. The PPM mode P/R wave 19.2, impedance 935 Ohm, threshold 0.9 V. The generator was programmed lower rate 60 bpm, upper rate 130 bpm, amplitude 3.5 V, pulse width 0.4 ms, and sensitivity 2.8 mV. Post-procedure, the patient remained stable and was transferred to the ward. Approximately six hours after the procedure, She suffered seizure and from ECG monitor showed ventricular tachycardia. Then, she got intravenous amiodarone and was transferred to cardiovascular intensive care. We suspected a PPM malfunction and we did a fluoroscopy evaluation, but the results was normal. Her permanent pacemaker (PPM) interrogation revealed normal device function with stable impedance, sensing, and pacing threshold values. Her serum electrolytes, including potassium (K 3.8 -> 3.06 mmol/L). She received potassium correction. During follow-up in cardiovascular intensive care, there was no event.

Conclusion: From this case, we can summarize that identifying a potential cause of arrhythmia (5H-5T) is important and suspicion pacing impulse formation may deleteriously interact with spontaneous cardiac depolarization due to sense, pace, or accidental inhibition defects of the pacemaker. It consequently may generate malignant arrhythmias. Stratification for underlying heart disease as a potential cause of future ventricular arrhythmias and subsequent sudden cardiac death prior to implantation of the device is very important, instead of determining patients who are eligible for pacemaker implantation.

Keywords: Malignant ventricular arrhythmia, permanent pacemaker

TERMINATING BY COUGH, IS IT VENTRICULAR OR SUPRAVENTRICULAR TACHYCARDIA?

D. Mandasari¹, H.R Akbar²

¹General Practitioner in Al Huda Banyuwangi Hospital

²General Practitioner in Petrokimia Gresik Hospital

Background: The incidence ventricular tachycardia (VT) in STEMI is 1 in 20 patients. Vagal tone stimulation is known to stop supraventricular tachycardia (SVT) and distinguish it from VT. The literature demonstrates the rare cases of vagal tone stimulation for terminating VT

Case Illustration: A 47-year-old man was admitted after complaining of typical chest pain, dyspnea, and palpitations for one day. There is no family history of cardiovascular disease or previous illness. During a physical examination, the patient's blood pressure was 50/30 mmHg, heart rate was 202 beats per minute, and respiration rate was 38 beats per minute. When the initial ECG revealed VT, he made plans for synchronized cardioversion; however, before the cardioversion, he coughed and the ECG returned to sinus rhythm. STEMI anterior was evident on the second 12-lead ECG. Troponin I was positive and hypokalemia (3.11 mmol/L) were found to be present in the test results. A chest x-ray showed pulmonary congestion and cardiomegaly. A loading dosage of aspirin 160 mg, clopidogrel 325 mg, atorvastatin 40 mg, amiodaron 150 mg, dopamine begins at 5 mcg/minute, infusion of kalium chloride, and enoxaparin were given to the patient. The patient's ECG made a suggestion to VT based on the Brugada algorithm. Following STEMI, VT develops from the Purkinje system as a result of automaticity and is exacerbated by hypokalemia. The suggested mechanism is a quick shift in heart size via lowering Purkinje fiber stretch and vagal-mediated acetylcholine release. In this patient, VT resolved with an intense cough that increased vagal parasympathetic tone.

Conclusions: In this case, coughing enhanced the vagal parasympathetic tone, which could end the tachycardia. Therefore, it should be thought of as a potential emergency treatment before receiving definitive medication.

KEYWORDS: Ventricular tachycardia, Supraventricular tachycardia, Cough

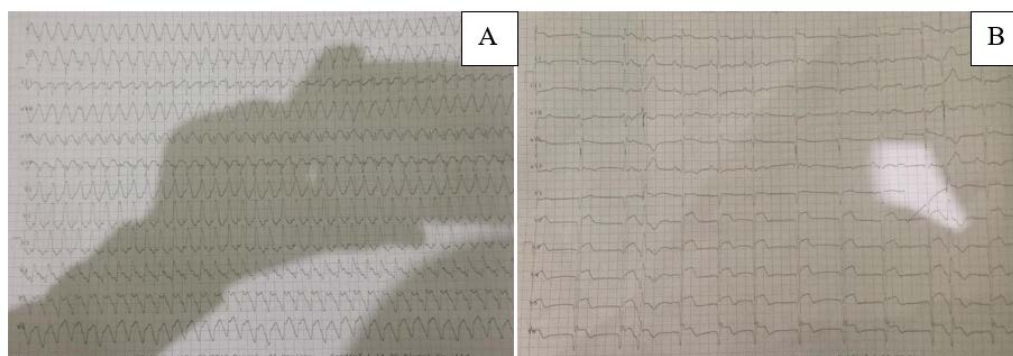


Figure 1a. ECG on admission 2b. ECG after the patient coughed.

**Cardiac Arrest as Myocard Infarct Complication : What should we do in Rural Primary Healthcare
?**

D. Priyanto

Mardi Waluyo Hospital, Metro, Indonesia

Background: The incidence of cardiovascular disease is increasing annually. Based on Riset Kesehatan Dasar (Riskesdas)’s data in 2018, at least 15 of 1000 population in Indonesia had heart disease. The largest cause of death is ischaemia heart disease, responsible for 16% of total global mortality. Proper management is early recognition and management to prevent complication such as cardiac arrest.

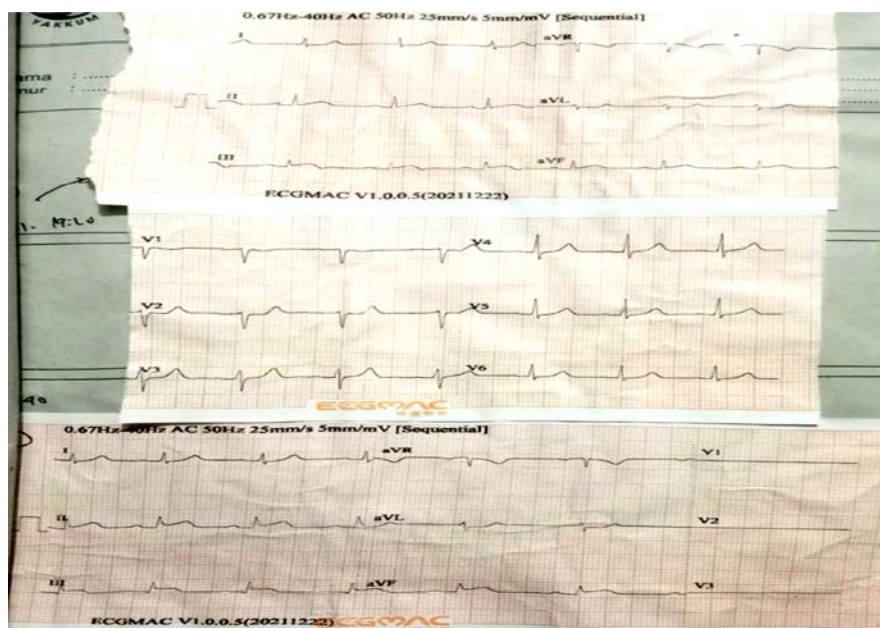
Case Illustration: A thirty years old male patient was taken to the clinic with sudden unconsciousness after playing football 15 minutes and apnea for 2 minutes. At clinic, he had no response and no carotid pulse, then cardiopulmonary resuscitation (CPR) was performed. The electrocardiogram (ECG) showed pulseless electrical activity (PEA), and we administrated intravenous 1 mg of epinephrine 1:1000 every 3 minutes. After 5 cycles of CPR, the patient was return of spontaneous circulation (ROSC) with sinus rhythm of ECG. He still had poor perfusion, blood pressure of 70 per palpation and pulse 90 times perminute. After a fluid challenge using 250 ml of normal saline, systolic blood pressure increased to 80 per palpation and pulse 87 times perminute. After 5 minutes, the patient had seizure followed by the second cardiac arrest. CPR is performed, and after the second administration of epinephrine, the patient was ROSC with systolic BP of 60 per palpation. ECG showed ST segment elevation in lead II, III and aVF. We gave epinephrine drip in 100 ml normal saline with dose 0.1 mcg/kgbb/minute. Immediately, the patient was given aspirin 320 mg and clopidogrel 320 mg then referred to hospital.

Conclusion: Case recognition with proper and rapid management of patients with myocardial infarct can reduce mortality rate of heart disease.

Keywords

Cardiac arrest, Myocard infarct, Primary healthcare

19:20



19:40

Figure 1. Patient’s ECG, 5 minutes after cardiac arrest and 25 minutes after cardiac arrest

Tonic-Clonic Seizures in Child with Implanted Epicardial Pacemaker with Complete Atrioventricular Block: Epilepsy or Pacemaker Malfunction?

¹*D. S. Budi, ²R. P. Putra, ²I. K. Murni, ¹F. Hidayati, ¹E. Maharani

¹ Department of Cardiology and Vascular Medicine, Faculty of Medicine, Public Health and Nursing, Universitas Gadjah Mada/Dr Sardjito General Hospital, Yogyakarta, Indonesia

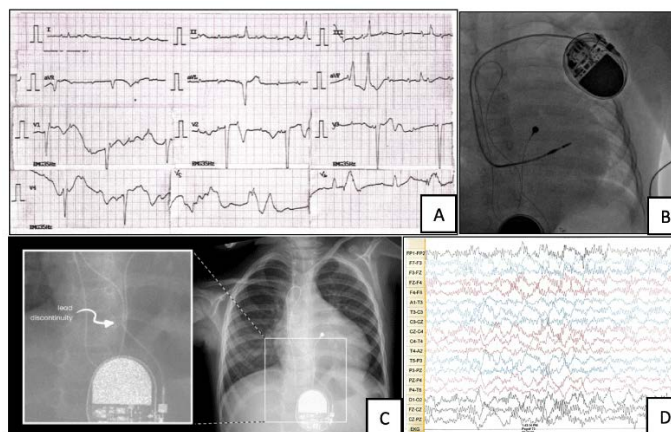
² Department of Child Health, Faculty of Medicine, Public Health and Nursing, Universitas Gadjah Mada/Dr Sardjito General Hospital, Yogyakarta, Indonesia

Background: It can be challenging to distinguish between cardiogenic and neurological syncope. Cardiogenic syncope and epilepsy present similarly, which may result in incorrect diagnosis and treatment.

Case illustration: A 4-year-old child who had a congenital total heart block and a pacemaker implanted at age 2 presented with recurrent generalised tonic-clonic seizures as soon as she fell. The patient was diagnosed with epilepsy, thus received up-titrated valproic acid, but the convulsions continued. The electrocardiogram revealed total atrioventricular block and output failure with ventricular escape. A pacemaker lead discontinuity was visible on a chest X-ray. There were 48 instances of high ventricular rate, ventricular lead impedance greater than 9999 ohms, and a high pacemaker threshold on reprogramming. Therefore, the patient was assessed with an epicardial pacemaker lead fracture, then the pacemaker was modified to OVO mode. A VVIR transvenous permanent pacemaker was implanted because the patient's weight was adequate. The patient didn't experience any more seizure episodes after that.

Conclusion: In patients with bradycardia, tonic-clonic seizures that mimicking epileptic seizures can occur. The abrupt drop in cardiac output that causes decreased cerebral perfusion (Stokes-Adams syndrome) resulting tonic-clonic seizures that are resistant to anticonvulsants is thought to be caused by ventricular arrhythmias. Lead fracture, an uncommon issue that can affect patients with pacemakers implanted, can cause output failure and increased lead impedance. To determine the source of seizures and to provide the patient with the best possible care, which includes a new pacemaker, requires good clinical examination, careful electrocardiography analysis, and confirmed by imaging.

Keywords: tonic-clonic seizures, congenital complete heart block, lead fracture, pacemaker



Picture 1. Electrocardiogram of the patient (A), Chest X-Ray that showed discontinuity of epicardial lead (B), TPM implanted (C), Electroencephalography (D)

**Cardiotoxic Chemotherapy in the Patient With Brugada Syndrome: How to Deal with It?
A Case Report**

D. Setiaji¹, F. Hidayati¹, E. Maharani¹

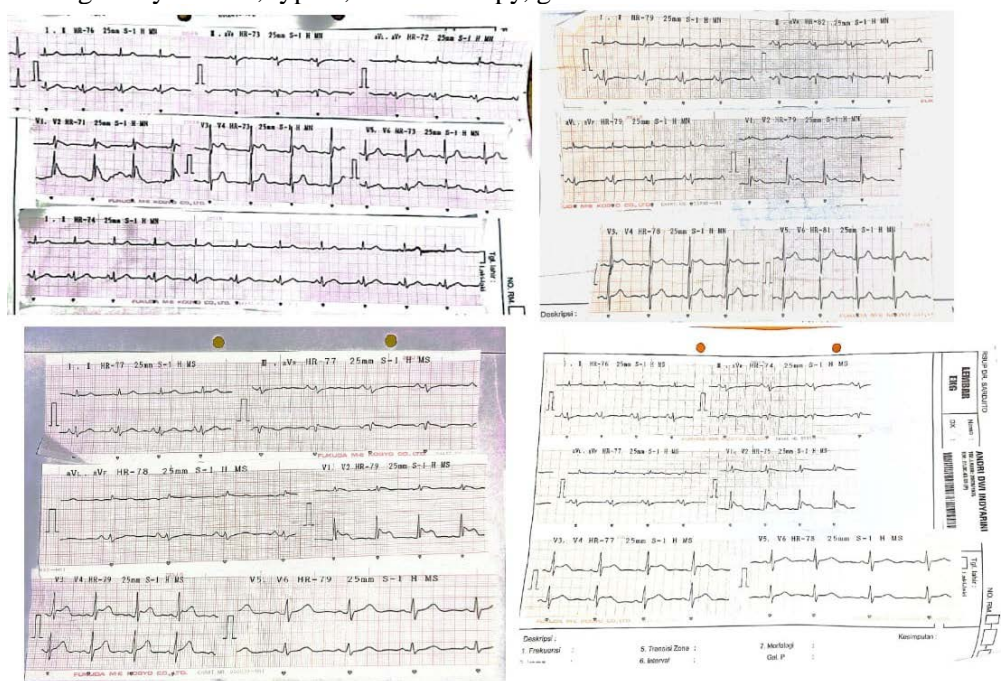
²Department of Cardiology and Vascular Medicine, Faculty of Medicine, Public Health and Nursing Universitas Gadjah Mada, Sardjito General Hospital, Yogyakarta, Indonesia

Background: Brugada syndrome (BrS) is a rare and hereditary disease related to sudden cardiac death, its characterized by coved-type ST-segment elevation ≥ 2 mm followed by a negative T wave in ≥ 1 of the right precordial leads. Brugada syndrome is associated with many cardiac diseases such as Long QT syndrome (LQTS), Early repolarization syndrome, etc, also non-cardiac diseases such as epilepsy, thyroid disease, and cancer. This report is of a case of type 1 Brugada syndrome in a cancer patient and discusses the importance of pre-chemotherapy ECG and close monitoring for side effects, especially the cardiotoxic effect.

Case illustration: A 46-year-old woman, without any previous medical history, was diagnosed with NPC T4N0M1 by the results of a non-keratinizing squamous cell carcinoma biopsy. The patient had undergone surgery and was planned to undergo chemotherapy with the TPF regimen (a combination of docetaxel, cisplatin, and fluorouracil) for 3 cycles and also radiotherapy. In the electrocardiography before chemotherapy, there was found a Brugada pattern type 1. From further anamnesis, there weren't any complaints before such as dizziness or fainting, and sudden death history in the family. The patient continues to be given chemotherapy with close monitoring and regular ECG examination. From further follow-up, no symptoms were found in the patient while being given chemotherapy.

Conclusion: Brugada syndrome causes 20% of sudden cardiac death in structurally normal hearts. The administration of chemotherapy drugs has many side effects such as the risk of cardiotoxicity which has the potential to trigger arrhythmias and sudden cardiac death. This condition further increases the risk in patients with Brugada syndrome. Close monitoring of chemotherapy administration on Brugada patients should be warranted. Guidelines on which chemotherapy drugs are safe for BrS patients are urgently needed.

Keywords: Brugada syndrome, type 2, chemotherapy, guidelines



Atrial Tachycardia with Wenckebach Block in Pregnancy: How to Differentiate with The Others and Treat It?

E Rosmillah¹, D Caroline², MR Amadis¹, RN Rosyadi¹, BB Dharmadjadi¹, R Julario¹

¹Department of Cardiology and Vascular Medicine, Faculty of Medicine, Universitas Airlangga, Surabaya, Indonesia

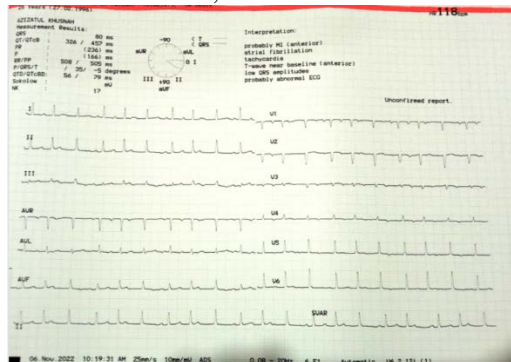
² Department of Cardiology and Vascular Medicine, Mitra Keluarga Kenjeran, Surabaya, Indonesia

Background: Supraventricular tachycardia (SVT) is dysrhythmia that originates from at or above the atrioventricular (AV) Node with a heart rate 100 bpm, and the QRS complex may be narrow (<120 ms) or wide (>120 ms). The prevalence of SVT is 2.25/1000 persons with a female and male ratio is 2:1 across all age groups. In pregnancy, SVT is reported in 22–33 per 100 000 pregnancies that include atrioventricular re-entry tachycardia (AVRT), atrioventricular nodal reentry tachycardia (AVNRT), and focal atrial tachycardia (FAT). Most to least frequency SVT in pregnancy is AVNRT, AVRT, and FAT. SVT treatment in pregnancy differs from common therapy because few antiarrhythmic drugs have adverse fetal effects, such as low birth weight, preterm labor, and fetal distress, which also depends on the gestational week. This case presents a rare case about a pregnant patient whom we suggested suffering FAT accompanied by second-degree AV block.

Case presentation: A 26-year-old woman in third-trimester gestation complained of palpitation and shortness of breath. The first physical examination showed a hemodynamically stable, and ECG pattern showed a supraventricular rhythm of 206 bpm. Thus, we diagnosed her as SVT with hemodynamically stable and treated her with vagal maneuver, beta-blockers, and calcium channel blockers. However, there was no sign of conversion to sinus rhythm and her condition showed hemodynamic instability, so we did synchronize cardioversion and administered Digoxin. Nevertheless, The ECG pattern emerged controversy because the P wave and T wave were difficult to be identified. We suggested the P waves overlap with the T waves. Therefore, the most possible diagnosis of this patient was FAT with Wenckebach block. So, we planned an electrophysiology study (EPS) for diagnosis and therapy and administered Diltiazem until she delivered labor via section cesarean. When she was discharged, we prescribed her Amiodarone and Metoprolol. Unfortunately, the patient is lost to follow-up.

Conclusion: SVT should be recognized in the first place so we can decide on the appropriate treatment. In this case, the pregnant patient with FAT and Wenckebach block has been reported, which is a rare case. Because the patient is pregnant, the therapy choice should be considered because of fetal and maternal adverse effects.

Keywords: SVT, Pregnancy, Wenckebach Block, FAT





An Unusual Anatomy of Coronary Sinus in Patient with Wolff-Parkinson-White Syndrome and Stretched Patent Foramen Ovale with Atrial Septal Aneurysm Undergoing Accessory Pathway Ablation

F. Ahmad, S.B. Raharjo, S.A. Manurung, C. Rith, D.Y. Hermanto, D.A. Hanafy, Y. Yuniadi
Division of Arrhythmia, Department of Cardiology and Vascular Medicine, Faculty of Medicine
Universitas Indonesia / National Cardiovascular Center Harapan Kita, Jakarta, Indonesia

Background: The coronary sinus (CS) is an important vascular structure that allows access to the coronary veins in multiple interventional procedures including ablation catheter. The success of the procedure is supported by the knowledge of the CS anatomy, particularly the recognition of its anomalies and other existing structural heart disease.

Case Illustration: We report a rare case describing the accidental finding of an abnormal septal anatomy structure in a 46-year old woman with Wolff-Parkinson-White (WPW) syndrome undergoing right posteroseptal accessory pathway ablation. We found a difficulty when inserting the decapolar catheter to CS during ablation procedure. Finally, we had successfully inserted the catheter to the CS, but in the unusual form as it shown on fluoroscopic view. Transoesophageal echocardiography was performed, it showed a stretched patent foramen ovale (PFO) left to right shunt and atrial septal aneurysm with hyperkinetic interatrial septum. These findings suggesting the possibility cause of the unusual anatomy of the CS.

Conclusion: This case highlights the importance of understanding the CS anatomy and its variations during performing the catheter ablation procedure. Another diagnostic modalities, like cardiac MRI and MSCT may be needed for further detailed evaluation of CS anatomy.

Keywords: coronary sinus, accessory pathway ablation, stretched patent foramen ovale, atrial septal aneurysm



**A Challenging Dual Chamber Pacemaker Implantation in Persistent Left Superior Vena Cava :
When Knowledge of Anatomy and Adequate Implantation Technique Have an Important Role**

F. Ahmad, S.B. Raharjo, S.A. Manurung, C. Rith, D.Y. Hermanto, D.A. Hanafy, Y. Yuniadi
Division of Arrhythmia, Department of Cardiology and Vascular Medicine, Faculty of Medicine
Universitas Indonesia / National Cardiovascular Center Harapan Kita, Jakarta, Indonesia

Background : Persistent left superior vena cava (PLSVC) is a rare congenital malformation and generally asymptomatic. It is usually discovered incidentally during a pacemaker implantation through the left axillary vein approach.

Case Illustration : We report a case of the incidental finding of PLSVC in a 57-year old man with total AV block undergoing dual chamber pacemaker implantation. After achieving access through the left axillary vein, the guide wire repeatedly coursed on the left side of the mediastinum, rather than crossing the midline. We confirmed from cephalic vein access and the guidewire still could not be advanced into the normal expected course of SVC, raising suspicion of PLSVC. Then guide wire was advanced to PLSVC and coronary sinus to right atrium and finally reach into inferior vena cava. A ventricular lead was successfully passed and fixed into the RVOT area with alpha loop configuration and an atrial lead was then passed through and directly fixed into right atrial appendage. Both atrial and ventricular sensing and pacing parameters were excellent and post-procedure fluoroscopy showed satisfactory lead positioning.

Conclusion: Pacemaker implantation in patients with PLSVC is technically challenging. Good knowledge of cardiac structure anatomy and adequate implantation technique are needed to achieve a good result in this such rare case.

Keywords: total AV block, dual chamber pacemaker implantation, persistent left superior vena cava

Complete Resolution of Total Atrioventricular Block Immediately after Failed Fibrinolytic Therapy on Inferior ST-segment Elvation Myocardial Infarction in Limited Facility: A Case Report

F. Deantri¹, D.L. Mulya², A. Gabriella²

¹Puskesmas Kalanganyar, Lebak, Indonesia

²dr. Adjidarmo Hospital, Lebak, Indonesia

Background: One of the acute complications that can occur in cases of inferior ST-segment myocardial infarction (STEMI) is Total AV Block (TAVB). This condition may be the result of increased vagal tone or ischemic condition of the AV node as the impact of myocardial infarction process. Early successful reperfusion is associated with early recovery of AV node. Hence, immediate reperfusion should be achieved as soon as possible even in limited facility.

Case Illustration: A 58-years-old male presented to our emergency department with ischemic chest pain. The initial pain started 6 hours prior to presentation. Two hours before admitted to the hospital, the patient experienced transient loss of consciousness for five minutes and regained full consciousness afterward. Patient had history of uncontrolled Diabetes Melitus Type 2 and smoking. On physical examination, hypotension, bradycardia, irregular heart beat, cold and clammy extremities were found. Initial ECG findings showed ST-segment elevation in lead II, III, and aVF. Cardiac enzymes were elevated. The patient then diagnosed with Inferior STEMI with TAVB. Patient underwent fibrinolysis as the reperfusion strategy. One hour after fibrinolysis, there was no chest pain and the ECG finding had returned to regular sinus rhythm yet ST-segment elevation remained unchanged. The patient refused to be reffered to PCI-capable center. Six hours post-fibrinolytic ECG had returned to sinus rhythm and normal ST-segment in the inferior lead. The patient was discharged from the hospital after 10 days with stable condition and no chest pain.

Conclusion: Fibrinolysis as reperfusion strategy in limited facility can be done and can be useful in achiving early recovery of AV node in patient with inferior STEMI and TAVB regardless of its successfulness right after the administration.

Keywords: Inferior STEMI, Total Atrioventricular Block, Failed Fibrinolytic, Complete Resolution

Effectiveness of Amiodarone for Recurrent Atrioventricular Nodal Re-Entry Tachycardia

F. Rachmaningrum¹, D. Dewi², R. Ekaputra¹, G. Tryan¹

¹General Practitioner, RSUD Banyumanik 2, Semarang, Indonesia

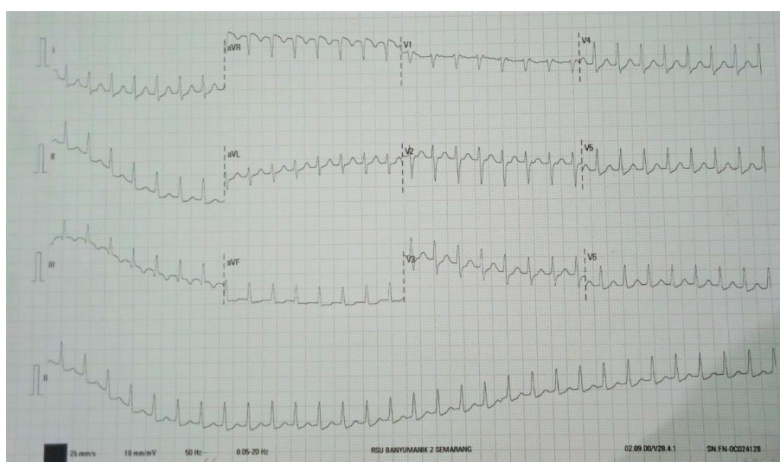
²Cardiologist, RSUD Banyumanik 2, Semarang, Indonesia

Background: Atrioventricular nodal re-entry tachycardia (AVNRT) is the most common type of paroxysmal supraventricular tachycardia, due to the presence of a re-entry circuit within or adjacent to the AV node. Management of AVNRT depends on patient stability. Patients with stable hemodynamic should be treated first with vagal maneuvers and should be performed at least twice to terminate the arrhythmia, it should need medical therapy if it doesn't work. Adenosine, non-dihydropyridine calcium channel blockers, beta-blockers and amiodarone are the medical treatment option in AVNRT.

Case illustration: A 46-years-old woman came to the emergency room with sudden onset of palpitation lasting 2 hours. She was alert and well perfused. She had no chest pain nor shortness of breath. During examination, the patient had a blood pressure of 103/77 mmHg, a pulse rate of 190 bpm, a respiratory rate of 24/minute, and oxygen saturation of 99% on room air with normal in general physical examination. 12-lead ECG showed regular narrow complex tachycardia with pseudo R' in lead V1. Chest x-ray examination showed cardiomegaly. She had similar symptom 2 years ago. Vagal maneuver and carotid sinus massage was performed but there were no change in heart rate. Rhythm changed after administration of amiodarone. Evaluation of ECG showed a sinus rhythm with heart rate 78 bpm.

Conclusion: Management of AVNRT is highly dependent on the clinical condition of the patient. Vagal maneuvers can be performed first in patient with stable hemodynamic. The first line medical therapy is adenosine but its availability is limited in Indonesia. Other agents which may be used include calcium-channel blockers, beta-blockers, and amiodarone. Amiodarone is an antiarrhythmic drug with the highest usage frequency. It has a broad therapeutic spectrum for a variety of arrhythmias and quite effective for AVNRT. Amiodarone has a low negative inotrope and can be used for AVNRT with heart failure.

Keywords: Atrioventricular node re-entry tachycardia, amiodarone, supraventricular tachycardia



Mild Hyperkalemia as a Reversible Cause of Sinoatrial Node Dysfunction. Unusual Manifestation of Acute Kidney Injury in an Elderly Patient

F. Tandri¹, I.P. Farissa¹, A.Y.A.B. Mochtar², P. Ardhiyanto²

¹Cardiology Resident, Faculty of Medicine, University of Diponegoro, Semarang, Indonesia

²Cardiac Electrophysiologist, Dr. Kariadi General Hospital, Semarang, Indonesia

Background: Hyperkalemia was noted as frequent cause of cardiac rhythm disturbances. Sinoatrial node dysfunction is less likely to occur if potassium level isn't very high due to its low resting potassium conductance. However, in conjunction with degenerative changes of sinoatrial node in elderly patients, it may occur even in presence of mild hyperkalemia.

Case Illustration: A 72-year-old woman was referred to our hospital with complaints of lightheadedness and presyncope for past 2 days. She notably has low urine output due to her assumption of having heart failure which has led to restriction in water intake. She was previously healthy without any comorbidities. Upon presentation, blood pressure was 110/70 mmHg with slightly irregular, weak, and slow pulse rate. Electrocardiogram (ECG) (**Figure 1A**) showed sinus bradycardia (52 bpm) with right bundle branch block (RBBB), which is competing with junctional escape rhythm, resulting in isorhythmic atrioventricular (AV) dissociation and sinus pause, contributing to slightly irregular rhythm. Hyperkalemia (5.7 mmol/L) and decreased renal function (creatinine [Cr] 3.2 mg/dl, eGFR 15 mL/min/1.73m²) were noted. Echocardiography revealed normal left ventricular function (ejection fraction 70.2%) without any wall motion abnormality. Because of unresponsiveness to dopamine and persistent symptoms, patient underwent temporary transvenous pacemaker placement and received rehydration with 500 cc of Normal Saline, natrium bicarbonate and calcium polystyrene. Permanent Pacemaker (PPM) Implantation was planned. Three days later, patient became asymptomatic with improved urine output, potassium level (4.3 mmol/L), and renal function (Cr 1.0 mg/dl, eGFR 60 mL/min/1.73m²). Subsequent ECG (**Figure 1B**) showed sinus rhythm (83 bpm), RBBB, and deep T-wave inversions in leads V1-5 (T-wave memory), without any pacing spikes. Five days of follow-up demonstrated a trend of normal heart rate (60-85 bpm), which postponed PPM implantation.

Conclusion: Sinoatrial nodal dysfunction was attributed to presence of mild hyperkalemia and decreased renal function, which was most likely the cause of symptoms. The diminished degree of hyperpolarization occurring at end of phase 3 prevents full reactivation of channels for sodium and calcium, resulting in a decreased slope of phase 4 in hyperkalemia. This may be responsible for the changes in sinoatrial function observed in this case.

Keyword: Sinoatrial Node Dysfunction, Mild Hyperkalemia, Geriatric, Isorhythmic AV dissociation, T wave memory

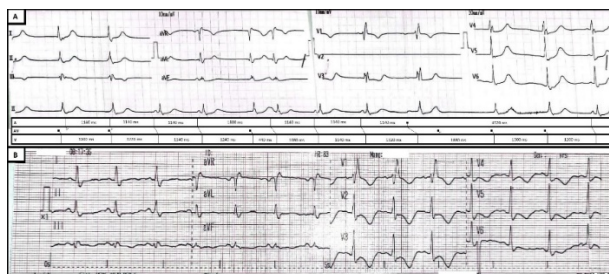


Figure 1. The ECG with a ladder diagram in the symptomatic phase reveals Sinus Bradycardia (52 bpm) with RBBB. The first two sinus beats compete with a junctional escape rhythm resulting in isorhythmic AV dissociation. Sinus pauses occur after the 4th and 8th ventricular beats which are terminated by the junctional escape rhythm and subsequent atrial rhythm (A). After the improvement of urine output, potassium levels, and renal function, the patient exhibited a fully intrinsic rhythm (83 bpm) without any signs of pacing spikes. The persistent RBBB remained, accompanied by an exaggeration of T-wave inversion in precordial leads. This is likely caused by cardiac T-wave memory from the previous pacing rhythm (B).

Total Atrioventricular Block in Young Woman : How to Resolve the Problem?

G. F. Ramadhan¹, E. Supriadi²

¹Dr. Bratanata Army Hospital, Jambi, Indonesia; ²Raden Mattaher General Hospital, Jambi, Indonesia

Background: Total Atrioventricular (AV) Block or third-degree AV Block is unusual in young people. Total AV Block increases with advanced age because degenerative process happened. In young age, underlying cardiac disease and idiopathic fibrosis may cause Total AV Block. Cardiac pacing is indicated for all patient with this abnormal rhythm. Unfortunately, permanent pacemaker is limited on some cardiac center. Therefore, it still important to determine the etiology for better treatment strategies and minimize complication from cardiac pacing.

Case Illustration: A 40-year-old woman came to emergency room with chest discomfort one day before admission. She just reported one episode of sudden loss of consciousness while working in the office. She was otherwise well and no any disease history and drug taking. On the presentation, her blood pressure was 120/60 mmHg and heart rate was only 42 bpm. Other physical examination was normal. Initial 12-lead-ECG revealed a 3rd degree (Total) AV Block with a rate of 42 bpm (Figure 1a). Laboratory examination including complete blood count, electrolyte, kidney function and cardiac biomarker was within normal range. Therefore, Patients was worked up as unstable total AV block and maximum three times bolus of 1 mg atropine was given immediately and the patient was observed. The recorded ECG remained Total AV Block with a recorded heart rate of 54 bpm. The vital signs stable, but chest discomfort unresolved. Patient was referred to facilitated hospital in the same province for further diagnostic and pacemaker implantation. Coronary angiography revealed normal and temporary pacemaker was implanted. Unfortunately, the patient was planned to be referred again to other cardiac center with attending electrophysiologist for permanent pacemaker (Figure 1b).

Conclusion: Total AV block can be present in any of age. Permanent cardiac pacing almost always necessary for total AV block. However, this management methods still unavailable in some hospital due to lack of electrophysiologist. Hence, treatment with drugs and temporary pacemaker was fundamental for initial workup of total AV Block before referral process done.

Keywords: Total AV Block, Cardiac Pacemaker

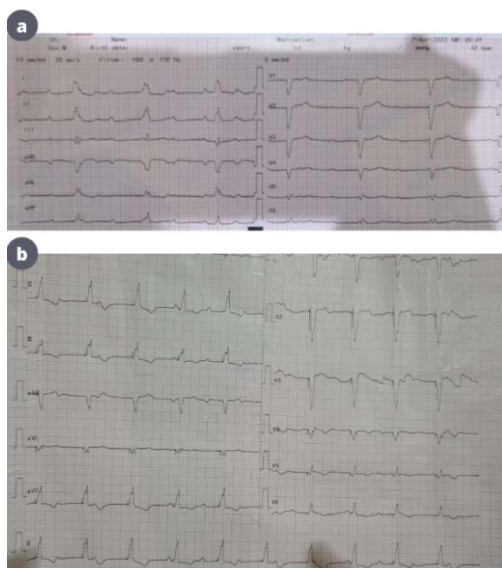


Figure 1. a. Initial ECG found Total AV Block with 42 bpm; b. ECG after permanent cardiac pacemaker implantation showed ventricular paced rhythm with 60 bpm

The Swinging Heart: Electrical Alternans in Patient with Massive Pericardial Effusion

¹Ghiena I. A., ²Surya H. P.

¹General Practitioner, Soekarno Regional Hospital, Bangka Belitung, Indonesia

²Interventional Cardiologist, Soekarno Regional Hospital, Bangka Belitung, Indonesia

Background: Massive pericardial effusion is a condition where there's a build up of excessive fluid in the pericardial layers. Pericardial effusion can be either caused by the inflammatory process or not. Metastatic pericardial disease occurs in one tenth of patients with cancer and most commonly originated from the lungs, breast tumors, melanoma and hematologic malignancies. Colorectal cancer has a hematogenous spread, but rarely metastasizes to pericardium. In the supporting examination, pericardial effusion can be detected through electrocardiogram examination with electrical alternans imaging. In this case, we reported a 56 years old male patient who had been diagnosed with colonic carcinoma with massive pericardial effusion.

Case Illustration: Mr. R, 56 years old with complaints of severe shortness of breath since a week ago, worsen a day before admitted to the hospital, shortness of breath accompanied by coughing up phlegm, lethargic body, chest pain, orthopneu. The patient who had been diagnosed with colonic carcinoma with massive pericardial effusion. From the physical examination obtained: tension: 96/54 mmhg, heart rate: 135x / m, rr: 28x / m. Heart sounds: muffled heart sound, heart sounds from a distance. From A 12-lead electrocardiogram showed sinus tachycardia and low-voltage QRS with marked electrical alternans. Echocardiography: massive pericardial effusion as a swinging heart. Recognition of a large pericardial effusion via ECG or echocardiography findings described above can facilitate emergent pericardiocentesis. In this case, pericardiocentesis drained 1,125mL of blood-stained fluid.

Conclusion: Massive pericardial effusion is a serious condition in patients who have unstable hemodynamics. With meaningful physical examination and simple support such as electrocardiogram, it found the presence of electrical alternans as one of the signs of pericardial effusion, it is hoped that pericardiosynthesis management can be done quickly and precisely. So hopefully the patient's prognosis will be better.

Keywords: Electrical Alternans, Pericardial Effusion, Swinging Heart.

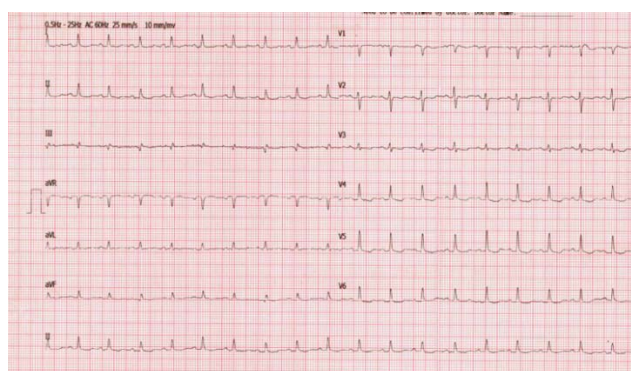


Figure 1. A 12-lead electrocardiogram showed sinus tachycardia and low-voltage QRS with marked electrical alternans



Implantation of a permanent pacemaker in the Persistent Left Superior Vena Cava: A special challenge

G. Saerang^{1,2}, S. S. Baskoro^{1,2}, A. Rizal^{1,2}, A. Prastya^{1,2}

¹Department of Cardiology and Vascular Medicine, Faculty of Medicine Universitas Brawijaya; ²dr. Saiful Anwar General Hospital

Background: Persistent left superior vena cava (PLSVC) is a rare congenital anomaly characterized by the persistence of a left superior vena cava, resulting in venous drainage abnormalities. It is usually asymptomatic and often represents an incidental finding during an invasive procedure. Pacemaker implantation in PLSVC is challenging due to anatomic changes and potential difficulties in lead placement.

Case Illustration: The first case, an 81 years old woman with heart failure came to the hospital with complain of dizziness, blurred vision, and vomiting. Her heart rate is 30 beats per minute and the EKG shows AV block. He had a temporary pacemaker installed at the previous hospital and was referred for a permanent pacemaker. During the procedure, a PLSVC was found which made it difficult to install the pacemaker lead, so several maneuvers were performed and finally the lead was successfully placed. The Second case, A 65-year-old man was referred to the cardiac clinic because of an irregular heart rhythm during a medical examination. The patient occasionally feels dizzy, and Holter monitoring shows sinus pauses. The patient was diagnosed with sinus node dysfunction and a permanent pacemaker was installed. During the procedure, PLSVC was obtained and various maneuvers were performed for lead implantation but failed. Then it was decided to replace the access via the right side and finally the lead was successfully installed.

Conclusion: Pacemaker implantation in patients with PLSVC can present some unique challenges and may be associated with certain complications. A various maneuvers can be performed for lead implantation. A right side approach can be attempted when various maneuvers have been attempted but failed The optimal lead position depends on the specific anatomy of the PLSVC. PLSVC can be problematic, and increase procedure time even in experienced hands. Complications related to pacemaker implantation can occur and are managed accordingly.

Keywords: Pacemaker implantation; persistent left superior vena cava;



Idiopathic Premature Ventricular Complex and Left Ventricular Dysfunction: Does Circadian Variation Have a Role?

G. Shabirina, S. B. Raharjo, B. H. Nugroho

Department of Cardiology and Vascular Medicine, Faculty of Medicine,
Universitas Indonesia, Jakarta, Indonesia; National Cardiovascular Centre Harapan Kita, Jakarta,
Indonesia

Background: Frequent idiopathic premature ventricular complex (PVC) can cause left ventricular (LV) dysfunction. PVC burden is an important factor that causes LV dysfunction.(1) However, the role of circadian variations of PVC on LV function remains unknown. We presented two cases of patients with high burdens of idiopathic PVC who had different circadian rhythm variations.

Case Illustration: The first case is a 51-year-old female patient who came to Harapan Kita Hospital with rapid heart beat occasionally during activities. A 12-lead ECG showed sinus rhythm with trigeminal PVC (morphology: left bundle branch block (LBBB) pattern, inferior axis, R/S transition at lead V3, positive at lead I; suggesting an RVOT origin). A 24-hours Holter monitoring revealed sinus rhythm with frequent monomorphic PVC (15%), with QRS duration 360 ms. An important Holter finding is the circadian variation of the PVC was 72.4%. Echocardiography examination showed the global longitudinal strain (GLS) was -22.7. The second case is a 58-year-old female patient who was referred to Harapan Kita Hospital with frequent PVC without any symptom nor complaints. A 12-lead ECG showed similar to the first patient. 24-hours Holter monitoring revealed similar morphology, frequent monomorphic PVC (16%), with QRS duration 360 msec. The circadian variation of the PVC was 29.83%, and the GLS was -15.9.

Conclusion: We have described two patients with similar PVC burden, PVC origin, and similar QRS duration. However, we noticed that one patient had high circadian variation and another one showed low circadian variation. GLS echocardiography revealed a normal LV intrinsic systolic function in the first patient, and reduced GLS in the second patient. Therefore, we suggested that the circadian variation of PVC may have impact on the LV intrinsic systolic function.

Keywords : Circadian Rhythm Variation, Idiopathic PVC, Left Ventricular Dysfunction

Bradyarrhythmias post Cardiac Valve Surgery: When to Implant Permanent Pacemaker ? A Case Report

H. Hutabarat¹, A.A Lukito¹, R.A.P. Fernandes¹, S. Chandra¹
¹Siloam Hospitals Lippo Village, Indonesia

Background: Arrhythmia is one of the most common complications after cardiac surgery. Causes of bradyarrhythmias is multifactorial. Several mechanisms of postoperative bradyarrhythmias include direct damage to the conduction system during surgical manipulation, tissue edema of surrounding SA/AV node. Valve surgery or combined procedures (multiple valve and CABG) increases the risk of developing atrioventricular blocks as a postoperative complication. Kim et al found that if AV block persists for ≥ 48 hours, PPM installation is recommended on day 7. However, Merin et al found that there was no significant difference between early (≤ 5 days) or late implantation to pacemaker dependency.

Case Illustration: A 57-year-old man presents to the emergency room with shortness of breath worsened with activity, swelling in lower extremities, normal blood pressure, tachycardia, and tachypnea. There was increased JVP, crackles in bilateral lung, regular heart sounds and murmur. NTproBNP was 4918 pg/mL. EKG showed AF-RVR. Chest Xray revealed cardiomegaly. Echocardiography showed mild dilatation of all cardiac chambers, LVEF 29%, global hypokinetic, severe MR, moderate TR, and volume overload.

The patient was stabilized, coronary arteries evaluation showed slow flow and non-significant lesion. Mitral valve replacement, Tricuspid valve repair and LAA ligation was performed. Day 1 post surgery, patient experienced recurrent non-sustained VT. Metabolic and electrolyte imbalances and other possible causes of rhythm disturbances have been managed. The next day, rhythm changed to junctional rhythm with episodes of bradycardia. It was then decided to activate the epicardial temporary pacemaker. Day 4 post surgery, intravenous steroids were administered. Day 7, oral theophylline was started. Day 8, the rhythm was back to AF with NVR. Day 9, TPM was switched off and by Day 11 patient was discharged without pacemaker.

Conclusion: Rhythm disturbances in postoperative cardiac conditions require a thorough investigation to find the cause. The decision for PPM implantation is determined based on the physician's clinical judgement and patient's condition.

Keywords: Bradyarrhythmia, PPM, Valve surgery

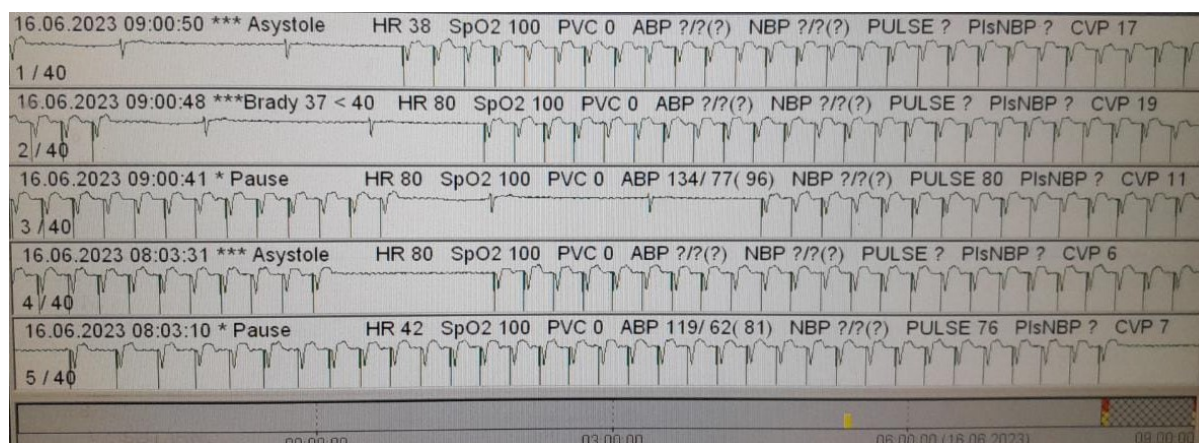


Fig.1 Electrocardiogram



Hope in Sync - Radiofrequency Ablation Restores Dilated Cardiomyopathy due to Wolff-Parkinson-White Syndrome: a Case Report

H.Jauhari¹, E.Maharani², F.Hidayati²

¹Resident of Cardiology and Vascular Medicine, Gadjah Mada University/ Sardjito General Hospital, Yogyakarta

² Staff Department of Cardiology and Vascular Medicine, Gadjah Mada University/ Sardjito General Hospital, Yogyakarta

Background: In some cases, accessory pathway-mediated ventricular preexcitation can be associated with electro-mechanical dyssynchrony which may cause eccentric ventricular activation, an asynchronous spread of ventricular depolarization, and consequently with dyssynchrony-related dilated cardiomyopathy.

Case Illustration: A 29-year-old male patient was diagnosed with dilated cardiomyopathy and was treated in an outpatient clinic with heart failure medication. Electrocardiogram showed pre-excitation with positive delta wave at V2-V6, I, AVL and negative delta wave at V1, II, III, AVF suggested as right posteroseptal accessories pathway with QRS duration 200 ms. The patient had no palpitations or documented tachycardia events. On echocardiography, we found left ventricular ejection fraction (LVEF) was decreased to 21%, left ventricle (LV) and left atrium (LA) were enlarged (left ventricular end-diastolic dimension (LVEDd) = 77 mm, left atrial volume index (LAVI) = 48 mL/m²) and there was intraventricular delay with duration of septal to posterior wall motion delay at 190 ms. Coronary CT showed normal coronary arteries. Several studies have shown that right septal accessories pathway (AP) typically has intraventricular dyssynchrony and subsequent systolic dysfunction because of early septal activation. Electrophysiology study revealed an antegrade AP ERP 320 ms and programmed atrial stimulation without drug provocation induced orthodromic AVRT. Mapping with non-irrigating ablation catheter at septal tricuspid annulus near parahisian and during radio frequency ablation (RFA), EGM showed complete separation of the atrioventricular complex and delta wave disappeared indicating successful ablation of AP with reduction in QRS length to 110 ms. Clinical evaluation after RFA revealed improved functional class and echocardiogram after 6 months showed LVEF was increased to 32% and the enlargement of LV and LA was decreased (LVEDd=71 mm, LAVI=39 mL/m²) with normal septal to posterior wall motion delay at 70 ms.

Conclusion: WPW syndrome with a right posteroseptal accessory pathway can be the cause of dilated cardiomyopathy and a disappearance of pre-excitation by RFA can result in mechanical resynchronization, reverse remodeling, and improvement in LV function.

Keywords: WPW syndrome, dilated cardiomyopathy, radiofrequency ablation

Reversible Complete Atrioventricular Block in Patient with Hyperkalemia

H. N. Jirin¹, A Rahmawati², TN wulansari³, Y Doarest⁴,

Departement of Emergency, Sungai Dareh General Hospital, Dharmasraya, Indonesia

Background: Complete Atrioventricular (AV) block is the most serious type of heart block, because complete atrioventricular block is life threatening condition if not treated immediately. They usually have a much greater risk of developing asystole, ventricular tachycardia, or sudden cardiac death. The most common causes of reversible AV block are drug-induced, metabolic and endocrine causes. One of the metabolic causes that cause AV block is hyperkalemia. Complete AV block is a rare presentation of hyperkalemia. The insertion of permanent Cardiac pacemaker is indicated for treatment complete AV block but in this case

a rhythm conversion was returned to sinus rhythm without the use of a cardiac pacemaker.

Case Illustration: A 61-year-old male patient with a history of type 2 diabetes mellitus came to the emergency department with complaints of shortness of breath and cold sweats since 1 day before. The EKG shows complete AV block in this patient. On laboratory examination found increased urea and creatinine and the presence of severe hyperkalemia. In this patient, serial correction of hyperkalemia was performed with calcium gluconate, insulin, dextrose, and conversion of complete AV block to sinus rhythm was obtained without the use of a cardiac pacemaker.

Conclusion: This case illustrates that hyperkalemia can lead to rare complete AV block, and is one of reversible causes of AV block, which can change to sinus rhythm without a pacemaker. Routine examination and correction of hyperkalemia can be considered as an alternative initial management before installing a pacemaker.

Keywords: Complete AV block, Hyperkalemia, Pacemaker



Fatal Dysfunction of Cardiac Pacemaker on Hyperkalemia Patient

H.P. Riswati^{1,2}, A. Rizal^{1,2}

¹Department of Cardiology and Vascular Medicine, Faculty of Medicine Universitas Brawijaya, Malang, Indonesia

² dr. Saiful Anwar General Hospital

Background: Hyperkalemia may induce serious cardiac arrhythmia with possible life-threatening effects. It may cause cardiac pacemaker malfunctioning due to a reduction of the electronegativity of the resting myocardial potential.

Case Illustration: A 69 years old woman with PPM implantation VVIR mode with TAVB due to degenerative was admitted for recurrent syncope. She also had history of CVA thrombosis with sequel hemiplegia dextra for 5 years. She was also being treated for congestive heart failure with furosemide, lisinopril, spironolactone, and amlodipine. The PPM mode threshold was 1.2 V, impedance 989 Ohm, Sense 19.6 mV. The generator was programmed lower rate 60 bpm, upper rate 130 bpm, amplitude 3.5 V, pulse width 0.4ms, and sensitivity 2.8 mV. Initial laboratory finding on admission found normal complete blood counts, sodium 135 mmol/L, potassium 3.35 mmol/L, chloride 98 mmol/L. CXR show cardiomegaly (CTR 71%) with oedema pulmonum and infiltrate perivascular. She get prolonged hospitalization because of the congestion didn't improved with medication. A week after admission she became hypotension 60/39mmHg. The ECG revealed no spontaneous atrial activity, bradycardia and widening of the QRS complex. We do reprogramming of PPM involve increasing the output voltage and adjusting the sensitivity. At the time, we investigated of laboratory finding follow: sodium 137 mmol/L, increased potassium became 6.51 mmol/L, chloride 100 mmol/L, BGA showed respiratory acidosis. She was managed with immediate calcium chloride, i.v 50cc 40% dextrose, 10 international unit of insulin and sodium bicarbonate infusions.

Conclusions: In patients with cardiac pacemakers, hyperkalaemia can cause disfunction of the device with serious consequences. Initially, loss of capture can occur due to increased threshold, but, as the level of potassium increases, myocardial conduction is delayed and the paced QRS complex widens. This report highlights that acute hyperkalemia should be aware especially for patient susceptible to hyperkalemia, loss capture ventricular pacing by VVIR pacemaker should not be misinterpreted as a primary or technical pacemaker malfunction.

Keywords: pacemaker, malfunction, hyperkalemia

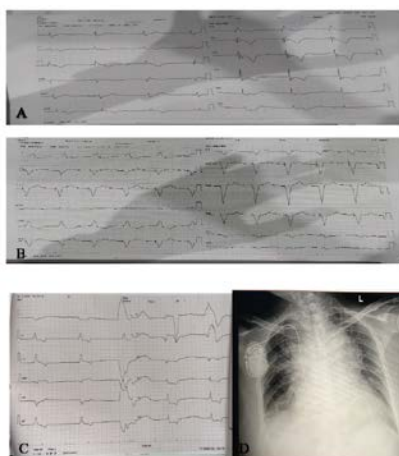


Figure 1. **A.** TAVB with ventricular escape rhythm, atrial rate 60 bpm, ventricular rate 42 bpm, FA N, HA CCWR, QRS 160ms, **B.** Pacing rhythm 67 bpm, LBBB pattern, appropriate RV apex pacing **C.** Ventricular rhythm, 30 bpm, FA N, HA N, QRS 180ms, **D.** Chest X-Ray showed pacemaker single lead hemithorax dextra with RV projection.

A Circus Player with Ectopic Atrial Rhythm: Should It be Treated?



H. T. Abdurrahman¹, M. Sundari¹, N. A. Tafriend², Haikal³, A. Harsoyo³

¹Cardiology Resident, Faculty of Medicine, Airlangga University, Surabaya, Indonesia

²Cardiology Consultant, ³Electrophysiology Consultant, Department of Cardiology and Vascular Medicine, Gatot Soebroto Army Central Hospital, Jakarta, Indonesia

Background: Heart rate regulation is driven by three key factors, such as sinus node automaticity, vagal tone, and sympathetic tone. In well trained person, there is a physiological adaptation due to vagal hypertonia that leads to ectopic atrial rhythm as an escape rhythm during resting state and converts to sinus rhythm during exercise. This case report showed vagal hypertonia in a circusplayer.

Case illustration: A 60-year-old man was referred to the arrhythmia clinic due to abnormal findings in electrocardiography (ECG) during perioperative state for left inguinal hernia surgery. He denied any cardiac symptoms such as syncope, palpitation, chest pain/discomfort nor dyspnea. His ECG showed ectopic atrial rhythm with P wave inverted in inferior leads, positive in V1 and isoelectric in lead I, PR interval 110ms, QRS dur 86ms, normal QRS axis, and neither ST segment nor T abnormalities seen. The origin of ectopic atrial rhythm was suggested from left pulmonary vein (LPV). Echocardiography showed normal LV function EF 70% with concentric LVH. Treadmill test showed ectopic atrial rhythm during pretest and sinus rhythm during exercise. A 24-hour Holter monitoring showed most of his rhythm was ectopic atrial rhythm and less sinus rhythm with PAC infrequent. He was referred to EP lab for further evaluation. EP study showed that during ectopic atrial rhythm, earliest A activation was in CS 3-4. Programmed electrical stimulation (PES) showed normal SA node intrinsic function. During Isoproterenol iv given, monitor showed mainly sinus rhythm until washout period of Isoproterenol. We conclude that the ectopic atrial rhythm was caused by vagal hypertonia with normal SA node function, no further treatment needed.

Conclusion: In well trained person, vagal hypertonia may suppress the sinoatrial node intrinsic automaticity. This condition may lead to low atrial escape rhythm. In this patient, escape rhythm was shown from left pulmonary vein area.

Keywords: Atrial rhythm, vagal hypertonia, sinoatrial node function.

**PRINZMENTAL ANGINA POST SUCCESSFUL RADIOFREQUENCY CATHETER ABLATION
IN PATIENT WITH WPW PATTERN TYPE B
(FIRST LOCAL EXPERIENCE AND THE RARE COMPLICATION)**

I. Darwis, F. Hidayati, E. Maharani

Department of Cardiology and Vascular Medicine
Faculty of Medicine, Public Health and Nursing
Universitas Gadjah Mada

Background: Radiofrequency catheter ablation is a high success rate procedure for treating Wolff–Parkinson–White (WPW) syndrome. The complication of post ablation is rare. Prinzmental angina due to coronary vasospastic can be caused by thermal injury during RFA procedure. Thermal injury complications can occur when electricity is applied to the accessory pathway areas which causes coronary vasospastic.

Case Illustration: A 35 year old male patient diagnosed with WPW pattern type B based on the results of the holter monitor obtained intermittent preexcitation. The patient underwent electrophysiology study and found WPW pattern with malignant accessory pathway at right posteroseptal side. The patient underwent catheter ablation. The total amount of radiofrequency application energy in the coronary sinus was 7200 Joule twice time from the right and left side. Finally, preexcitation was eliminated during RFA in the posteroseptal area. Six hours after the procedure, the patient felt chest discomfort, cold sweating and palpitations. An ECG evaluation showed ST segmen elevation at I, AVL and increase in cardiac troponin of 225 ng/dl. The patient was observed in the intensive care room and given diltiazem 30mg per 8 hours. During observation, the symptoms relieved and decrease in cardiac troponin to 165 ng/dl. Electrocardiography evaluation showed a back to baseline. Transthoracal echocardiography evaluation found normokinetic with an ejection fraction of 58%. An Computed Tomography Coronary Angiography examination was normal with LVEF 53% but there are superficial myocardial bridging at mid LAD coronary artery. There are segmental ST elevation at lateral. The location of the ST elevation accordance with LCx vascularization may result in vasospasm due to RFA whose position is closely to the accessory pathway area near the coronary sinus.

Conclusions: Prinzmental angina after ablation is very rare. Ablation side effects can occur directly myocardial damage or due to vasospastic coronary blood vessels as a result of thermal injury. Therefore, detailed mapping and careful ablation with low energy are needed, as well as the merits of identifying myocardial infarction after coronary sinus ablation.

Keywords: Prinzmental angina, Radiofrequency catheter ablation, WPW pattern

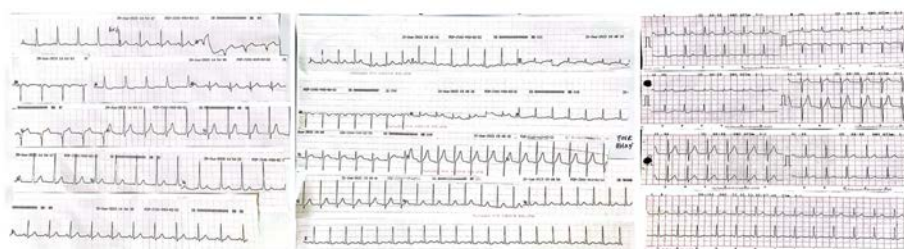


Figure 1a : Before RFA (sinus rhythm with preexcitation)

Figure 1b. After RFA (sinus rhythm without preexcitation and ST elevation I, aVL)

Figure 1 c. After RFA (sinus rhythm without preexcitation and back to baseline)



Timely use of digoxin transplacental therapy in fetal tachycardia: a case report

I. F. Arba, R.N. Rosyadi, C. C. Z. Multazam, P. P. Siahaan, W. Widiarti

Faculty of Medicine, Universitas Airlangga/Rumah Sakit Pusat Angkatan Laut Dr. Ramelan, Surabaya,
Indonesia.

Background: Fetal tachycardia (FT) is a rare and serious condition, occurring in <0.1% of pregnancies. It requires urgent cardiac and obstetric assessment, and delay of its diagnosis and management may cause serious consequences, such as fetal hydrops and intrauterine death. Here we present a case highlighting the importance of prompt digoxin transplacental therapy (TPT) in managing FT.

Case Illustration: A 28-year-old female in her third pregnancy was referred to our hospital for further investigations of FT found at 33/34wks. The fetal growth throughout the pregnancy course was normal. However, Doppler recording indicated a high risk of developing preeclampsia, leading to the administration of daily aspirin and calcium. There was no history of fever, thyrotoxicosis, or excessive caffeine intake. Although she experienced a miscarriage in her first pregnancy at 9/10wks, she delivered a healthy baby on her subsequent pregnancy. Vital signs were blood pressure 138/86mmHg and heart rate 142bpm. Cardiovascular examination was normal. The cardiotocograph showed a sustained FT of ~200bpm, without loss of fetal movement. Ultrasound examination revealed a single active fetus with normal biophysical profile, no hydrops, and normal amniotic fluid index. Since the FT persisted for more than >12hours, the absence of hydrops, and considering the gestational age, we decided to initiate TPT using oral digoxin 0.25mg bid, followed by 0.5mg intravenously. Within 2 days, the fetal heart rate significantly decreased (144-152bpm), and the TPT was discontinued thereafter. Over the course of the therapy, there was no signs of digoxin toxicity experienced by the mother, and the electrolytes, urea, and creatinine serum levels remained normal. Maternal ECG showed sinus tachycardia (136bpm), without any other abnormalities. Pre-discharge ultrasound and Doppler examination showed no compromise of fetal growth. The patient was discharged after 4 days. One-week follow-up visit showed no recurrence of FT, therefore, we decided not to administer a maintenance dose of digoxin, while closely monitoring her condition until due date. She delivered a healthy baby without any complications at 40wks.

Conclusion: Timely transplacental therapy using digoxin is effective in converting the rhythm and reducing the rate of fetal tachycardia.

Keyword: Fetal Tachycardia, Transplacental Therapy, Digoxin

23 YEARS OLD MALE MALARIA PATIENT WITH BRUGADA SYNDROME

I. Mukhtar¹, M. Amir^{1,2}, P. Tandean^{1,2}

¹. Department of Cardiology and Vascular Medicine Hasanuddin, Makassar, Indonesia

². dr.Wahidin Sudirohusodo National General Hospital, Makassar, Indonesia

Background: Brugada syndrome is a leading cause of cardiac arrest and sudden death in adolescents with normal cardiac structure. Clinical manifestations range from mild syncope to sudden death, mainly due to malignant arrhythmias. Jeong HK et al. reported that artemisinin effectively suppressed ventricular tachyarrhythmia and restored the right ventricular epicardial action potential dome in an experimental canine model.

Case Illustration: A 23-year-old man complained of palpitations with syncope for 4 months. Two week before admission, he complained of fever. About a year before his hospitalization, the patient contracted malaria in Papua, a malarious area, complained of palpitations and get artemisinin-based combination therapy. On clinical examination, this suspicion led to the diagnosis of Brugada syndrome. A provocation test was performed using 300 mg flecainide orally, a flecainide challenge test showed a positive result (Figure 1). We decided to give patients an artemisinin-based combination therapy against malaria. After administering the treatment, the patient reported no palpitations or syncope attacks.

The patients with brugada syndrome, ventricular fibrillation and polymorphic ventricular tachycardia are the most common manifestations of malignant arrhythmias. Definitive treatment for Brugada syndrome is an Implantable cardioverter defibrillator. Pharmacotherapy can help prevent arrhythmias while ameliorating channel feedback abnormalities that form the basis of brugada syndrome pathophysiology. It was decided that these patients would receive artemisinin-based combination therapy for malaria. It acts by inhibiting potassium channels, including Ito channels, and may subsequently suppress ventricular tachycardia/ventricular fibrillation.

Conclusion: Our case showed that artemisinin could be an effective treatment option for Brugada syndrome.

Keywords: Brugada syndrome, palpitation, syncope, flecainide challenge test, Artemisinin-based combination therapy

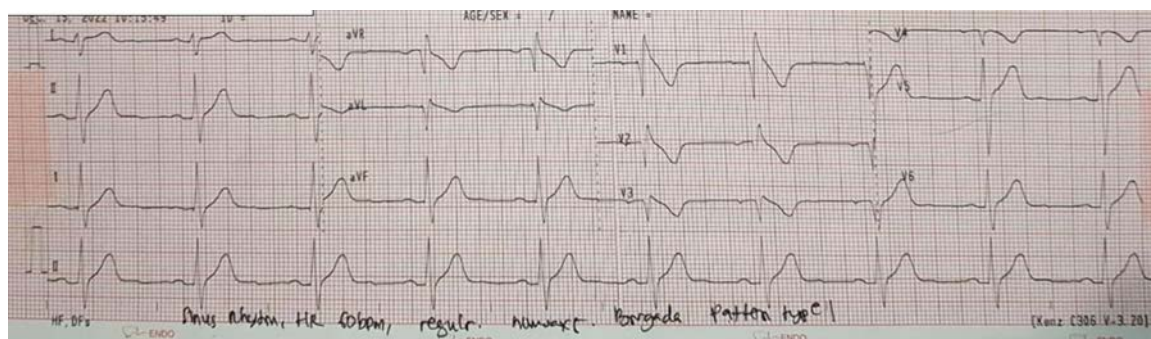


Fig 1. Brugada Pattern Type – 60 Minutes After Administration of Flecainide 300 mg orally

**Misdirected Transseptal Puncture To Muscularis Part of Interatrial Septum During Left Accessory
Pathway Ablation: To Proceed or To Withdraw?**

I. Posangi¹, W. Kwandou¹, A. L. Panda¹, B. S. Setiadi¹

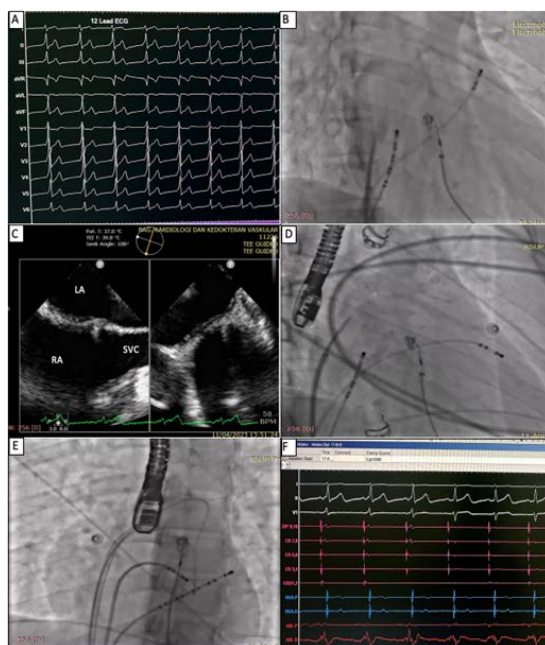
¹Department of Cardiology and Vascular Medicine, University of Sam Ratulangi,
Prof. Dr. R. D. Kandou General Hospital, Manado, Indonesia

Background: Transseptal puncture (TP) as an approach for left sided accessory pathway (AP) ablation is routinely performed in electrophysiology lab. However, not every procedure is straight forward.

Case Illustration: A 24 year old male with a preexcitation syndrome was admitted for an ablation procedure. The ECG recording showed positive delta wave on V1 and avF (figure A). Laboratory and transthoracic echocardiography (TTE) findings were unremarkable. During electrophysiology study, pacing on RV showed earliest activation on the CS 3-4, with an AP potential in between A and V signal, referring to a left sided AP with oblique course. Brockenbrough needle was advanced to superior vena cava and pulled back to interatrial septum (figure B) with fluoroscopy and TEE guiding. However, it was advanced through what seemed to be the superior muscularis part of interatrial septum on TOE (figure C). On right anterior oblique (RAO), needle tip was seen more superior than ideal, also more anterior than CS ostium (figure D). It was decided to proceed after carefully confirming that the needle landed in left atrium. Contrast injection was seen to fill left atrium and guidewire was used to anchor in pulmonary vein (figure E). Ultimately, ablation of left posterolateral AP was done successfully (figure F) without immediate complication or adverse event. After two months of follow-up, preexcitation did not reoccur and no pericardial effusion or persistent ASD were found on TTE.

Conclusion: Successful left sided AP ablation without complication is still achievable despite unideal transseptal puncture site. Cautiously investigating where the needle tip landed after puncture is crucial before taking further steps. Thorough follow up are needed to exclude long term complication.

Keyword: transseptal puncture, left accessory pathway ablation



PAROXYSMAL AF WITH REVERSION PAUSE CAN BE LIFE THREATENING: HOW TO MANAGE?

I.W. Gunawan^{1,2}, I.M.P.S. Antara^{1,2}

¹Department of Cardiology and Vascular Medicine, Faculty of Medicine Universitas Udayana, Denpasar, Indonesia

²Division of Arrhythmia and Electrophysiology, Department of Cardiology and Vascular Medicine, Prof Dr. IGNG Ngoerah Hospital, Denpasar, Indonesia

Background: Atrial fibrillation (AF) is the most common type of arrhythmia, as an important cause of cardiac syncope. Its prevalence increases by 1 to 2%. Recently paroxysmal AF has been associated with recurrent syncope with undetectable episodes of pauses.

Case Illustration: a 42-year-old man consulted with AF with a history of syncope. After a sudden fall at home for 1 hour prior to Prof Ngoerah Hospital, He had a close fracture of both mandibular. The dark vision before and then was unconscious for \pm 4 minutes already in a fallen position were complained. The focal neurologic deficit was nothing. He had a previous history of palpitations, irregular pulse, and recurrent syncope with the same duration and pattern that had been felt for 3 months. CT scan of the head showed normal, no problems in the field of neurology. CXR and TEE with normal results. First ECG with AF NVR. EKG after surgery showed sinus rhythm with unconducted PAC and 24-hour Holter monitoring revealed Paroxysmal AF with significant reversion pause and significant PACs (Figure 1). Finally, the patient underwent double chamber PPM implantation at RV mid-septal and RA appendage to prevent recurrent syncope and enable the safe administration of beta-blockers. The patient had been stable with PPM, rate control, anticoagulation based on scoring and optimal risk factor management, without AF ablation. He also had undergone cardiovascular rehabilitation and returned to work as before.

Conclusion: Many challenges in diagnosis, the need for a more detailed clinical history of recurrent syncope on reversion pause and caution for inappropriate use of beta blockers can exacerbate patient complaints and complications, which could be life-threatening.

Keywords: Reversion pause, Paroxysmal AF, cardiac syncope, PPM implantation.

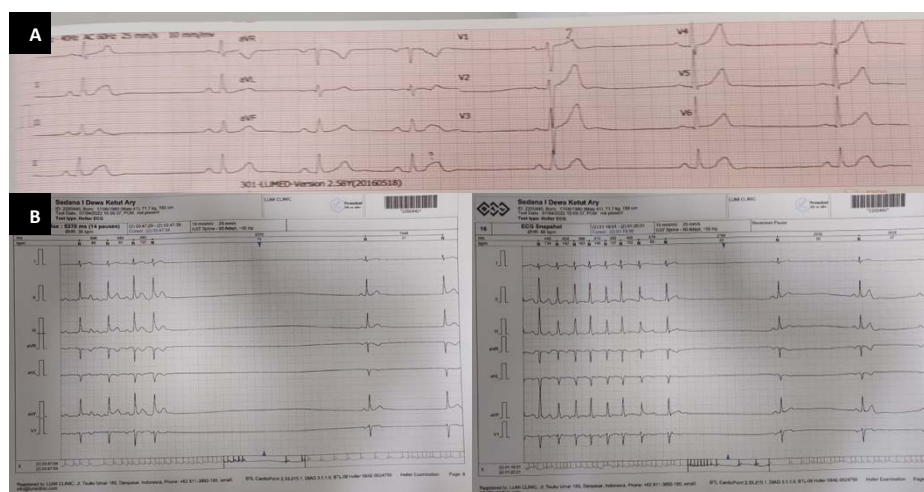


Figure 1. A. EKG: SR with unconducted PAC, B. Holter monitoring: Paroxysmal AF with significant reversion pause ($>$ 5s), Significant PACs

**His Bundle Area Pacing Using Custom Stylet-driven in Atrial Fibrillation:
A Single Centre Experienced Case Series**

J. Budiono¹, Haikal¹, A. Harsoyo¹, N. A. Tafriend¹

¹ Unit Clinical Cardiac Electrophysiology and Cardiology Intervention, Department of Cardiology
Indonesia Army Center Hospital Gatot Soebroto, Jakarta, Indonesia

Background: Performing His bundle pacing (HBP) might be technically challenging and modified pacing is often needed to identify his bundle potential. Furthermore, the identification of the His bundle potential in patients with atrial fibrillation (AF) was difficult, and some of the patients may have structural heart disease. A custom stylet-driven pacing lead (C-SDL) using a conventional pacemaker lead with high output in His bundle area, might be feasible to identify His bundle area and make a non-selective His bundle pacing.

Case illustration: All patients showed AF and underwent implantation using C-SDL from Biotronik Solia S-60 (Figure 1A). Patient 1, was a 69-year-old female who presented with dyspnea. Her echocardiogram showed severe mitral regurgitation (MR) and moderate tricuspid regurgitation (TR). Her electrocardiograms showed paroxysmal AF with QRS rate of 36 bpm. A temporary pacemaker (TPM) was inserted, and we didn't find other reversible causes of bradycardia, so she proceeded to VVIR permanent pacemaker (PPM) implantation in His bundle area. After 4 days post-implantation, her ECG showed QRSd 80 ms. The His-lead parameters were R wave = 4,7 mV, impedance = 515 Ω, NS-HBP threshold 4V @ PW 0.75 ms, RV myocardial capture threshold 0.9 V@ PW 0.5 ms (Figure 1B).

Patient 2, a former navy, was a 48-year-old male with near syncope. He underwent Holter monitoring and showed persistent AF with a pause of 3,4 sec during daytime. He had VVIR PPM implantation in His bundle area. After 4 days, post-implant follow-up ECG showed QRSd 100 ms with NS-HBP. The His-lead parameters were: R wave = 8,7 mV, impedance = 585 Ω, NS-HBP threshold = 0,8V @ 0,75 ms (Figure 1C).

Conclusion: His bundle area pacing using C-SDL can be used as one of the implantation pacing techniques, especially in atrial fibrillation patients with or without cardiac anatomy changes. High output pacing in His bundle area can predict that the tip of the pacemaker lead was near His bundle even when the operator could not see His potential due to AF.

Keywords: His Bundle Area Pacing, Atrial Fibrillation

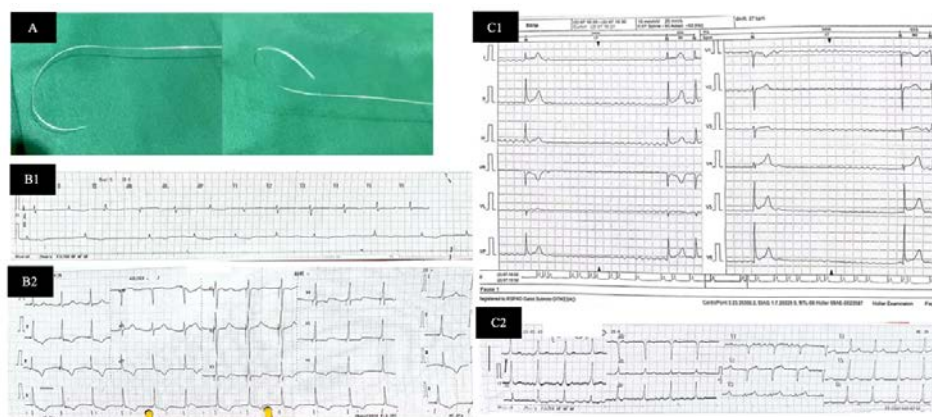


Figure 1. A: C-SDL which the operator created from conventional pacemaker lead with a curve shape and the stylet that was adjusted to His area by fluoroscopy guided during a pacemaker implantation procedure. B: Patient 1's ECG before (B1) and after (B2) implantation of his bundle area pacing. C: Patient 2's Holter and ECG before (C1) and after (C2) implantation of his bundle area pacing.



Not Just Slow, Tackling Torsades de Pointes in Bradycardia

JC. Kurniawan¹, S. Adiwinata¹, L. Wongso.¹, B. M. Setiadi¹

¹Department of Cardiology and Vascular Medicine Sam Ratulangi University

Prof. Dr. R.D. Kandou General Hospital Manado, Indonesia

Background: Torsades de Pointes (TdP) is a polymorphic ventricular tachycardia which associated with prolonged QT interval. TdP is potentially fatal tachyarrhythmia that could degenerate into ventricular fibrillation. Inverse relationship between heart rate and repolarization time makes bradycardia as one of the major factors predisposing to TdP.

Case Illustration: We reported two cases of TdP in patients with bradycardia. First, 68 years old male was admitted to our hospital due to loss of consciousness three times a day which initially preceded by palpitation. ECG showed sinus bradycardia 50 bpm with double-peaked T wave morphology and QT interval prolongation (Qtc 633 msec). Second, 86 years old female was admitted due to three episodes of presyncope within a month. ECG showed sinus bradycardia 43 bpm with 2nd degree AV block Mobitz II, with prolonged QT interval (Qtc 640 msec). Both patient had no history of taking QT-prolonging medications. Complete blood count, thyroid function test and electrolyte panel were in normal range. Echocardiography showed normal biventricular function without structural abnormalities. In hospital 24 hours Holter monitoring was done on both patients and revealed torsade de pointes with 180 bpm, and fortunately it was self-terminated. A dual chamber permanent pacemaker was implanted on both patients, and beta-blocker therapy was started. On follow up, pacing was seen >95% of the time, and QT interval shortening was noted. Both patients had no further syncope episodes.

Conclusion: Bradycardia and pauses induced prolonged QT interval might predispose to TdP. Recognition of potentially lethal ECG in bradycardia patients such as T wave notching and prolonged QT had a predictive value for TdP. Permanent pacemaker implantation combined with beta-blockers treatment could abolishes bradycardia, shorten QT interval and successfully suppressing TdP.

Keywords : Torsades de Pointes, bradycardia, pacemaker

A 35 YEARS OLD MAN WITH ATRIAL FIBRILLATION AND HYPERTROPHIC OBSTRUCTIVE CARDIOMYOPATHY: WHAT CAN WE DO?

J. Kelvin¹, Rufiat¹, M. Amir²

¹Departement of Cardiology and Vascular Medicine, Faculty of Medicine, Hasanuddin University, Makassar Indonesia

²Division of Arrhythmia and Electrophysiology, Faculty of Medicine, Hasanuddin University, Makassar Indonesia

Background: Patients with hypertrophic cardiomyopathy (HCM) are essential in controlling supraventricular arrhythmias and preventing abrupt cardiac death. Atrial fibrillation (AF) is the most prevalent persistent arrhythmia in HCM. In the HCM population, AF is known to occur 20% to 25% of the time, more frequently in elderly individuals and those who have left ventricular outflow tract obstruction (LVOTO). For the invasive therapy of LVOTO, various methods exist 1) Sequential DDD-AV pacing, 2) Septal Alcohol Ablation (SAA), and 3) Septal Myectomy. According to Wang et al., AVN ablation with his bundle pacing provides a secure and reliable way to regulate ventricular rate and maintain physiological ventricular activation in patients with persistent AF.

Case Illustration: A 35 years old man complained of shortness of breath, got worsened by activity five days before being admitted to the hospital. There was a history of intermittent shortness of breath followed by palpitation since last year. There was no history of hypertension. Physical examination showed pulses deficit, jugular venous pressure distention, rales at basal hemithorax bilateral, and murmur systolic grade 4/6 at the apex. Electrocardiography with atrial fibrillation, rapid ventricular response, left axis deviation and left ventricle hypertrophy. Transthoracic echocardiography showed symmetrical hypertrophy obstructive cardiomyopathy with dynamic left ventricle outflow tract gradient of 65 mmHg (Fig 1) and severe mitral regurgitation due to prolapse anterior mitral leaflet. The patient was stabilised in the intensive care unit, planned atrioventricular node ablation, and his bundle pacing permanent pacemaker implantation. After the procedure, there was a reduction in dynamic LVOT gradient to 36,5 mmHg (Fig 1), which improved his symptoms.

Conclusion: Although myectomy is considered the gold standard for hypertrophic obstructive cardiomyopathy (HOCM) patients with refractory symptoms but limited in some hospitals in Indonesia. This case shows AVN ablation followed by his-bundle pacing permanent pacemaker may be a safe and feasible option for treating a HOCM and Atrial Fibrillation patient.

Keywords: Atrioventricular node ablation, permanent his bundle pacing, atrial fibrillation, hypertrophic obstructive cardiomyopathy.

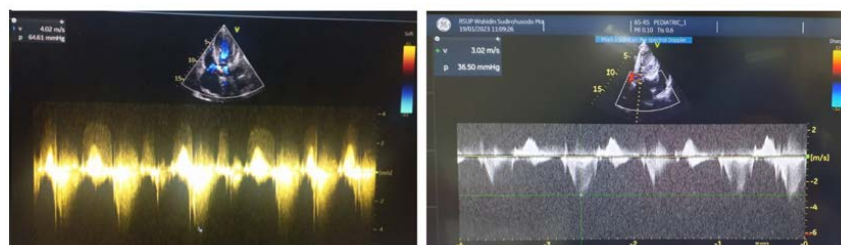


Fig. 1 Left ventricle outflow tract gradient pre (left) and post (right) intervention.

Stokes-Adams syndrome after anterior myocardial infarction: a case report

J. L. Gracia¹, J. A. Setiawan¹, S. Ng²

¹Faculty of Medicine, University of Pelita Harapan, Tangerang, Indonesia

²Department of Cardiology, Siloam Hospital Lippo Village, Tangerang, Indonesia

Background: The Stokes-Adams syndrome has been described as a syncope attack due to arrhythmias. Myocardial infarction contributes to arrhythmias development due to the ischemic of the SA node or AV node. Herein, we describe a case of Stokes-Adams syndrome due to sinus node dysfunction (SND) with recent anterior STEMI.

Case Illustration: A 41-year-old man presented to the emergency department with anterior STEMI and progressing orthopnea with NYHA II-III. He underwent primary PCI, and a stent was placed in the proximal LAD. He recovered well, received bisoprolol 5 mg, and was discharged three days later. Twelve days later, he came to the emergency room due to a syncope he experienced for the first time. Other examinations were insignificant. The Holter monitor was placed continuously, revealing a sudden sinus pause for 5.2s concurrent with another syncope (Figure 1. A). Pre- and post-syncope, rhythm returned to normal. All reversible causes were excluded. Hence, the syncope was determined as a Stokes-Adam attack. A single chamber permanent pacemaker was implanted in the right ventricle and set to VVI mode with hysteresis 40/60 bpm. The monitor captured the pacing a day after implantation (Figure 1. B). A pacemaker interrogation nine months and three years later revealed 0.2% and 0.4% pacing, respectively. He never had syncope anymore. **Conclusion:** This is a very rare case of Stokes-Adam attack after anterior STEMI. It is known that the SA node receives blood supply from the right coronary artery and left circumflex artery. However, this case displayed a possibility of SAN artery variations that might arise from the LAD, hence causing SND when anterior STEMI occurs, manifesting as Stokes-Adams syndrome. Pacemaker implantation serves as a definite therapy and can prevent future syncope episodes.

Keywords: Syncope, Stokes-Adam attack, sinus pause

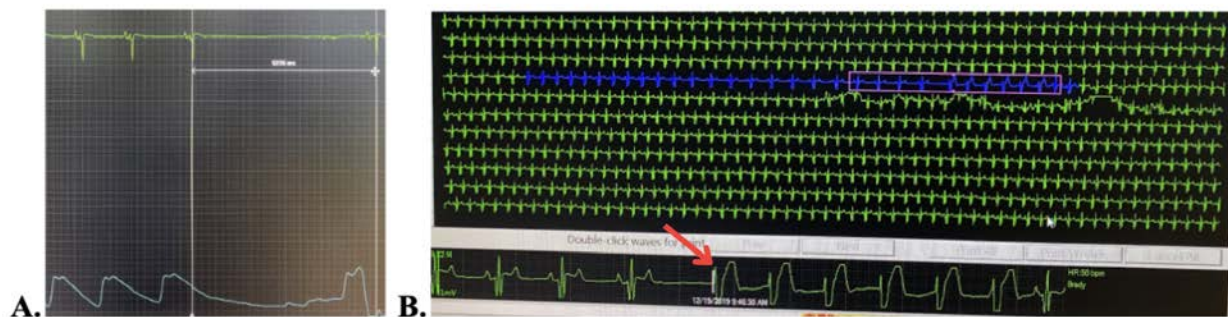

Figure 1. A. Sinus pause 5.2s B. Pacing 1 day after PPM implantation

Recurrent Preexcited Atrial Fibrillation due to Intermittent WPW Syndrome in Rheumatic Mitral Regurgitation: A Challenging Case in Rural Area

K. A. Nugraha¹, L.S. Sianipar², R.U. Setiani³

¹Samuel J. Moeda Navy Hospital, West Nusa Tenggara, Indonesia; ²Wirasakti Hospital, West Nusa Tenggara, Indonesia; ³Dr. Mintohardjo Navy Hospital, Jakarta, Indonesia

Background. Structural Heart Disease due to Rheumatic Heart Disease (RHD) can lead to arrhythmia. This paper present a case of RHD patient who concomitantly found pre-excitation Wolff-Parkinson-White (WPW) Syndrome and atrial fibrillation, thereby complicating the treatment.

Case Illustration. A 64-years-old female patient with history of rheumatic mitral regurgitation admitted to the emergency departmet due to palpitation and chest pain. On physical examination, she was fully alert, with normal blood pressure and tachycardia. Auscultation revealed a grade 4/6 pan-systolic murmur in the apex and LLSB. The ECG revealed atrial fibrillation rapid ventricular response with delta wave appearance. Patient had a recurrent rehospitalisation due to these episodes of tachyarrhythmia. After serial cardioversion up to 200 Joule the rhythm was successfully converted to sinus and patient condition was stable. Laboratory findings were within normal limit. Transthoracic echocardiography intrahospital showed enlarged left atrium, normal LV and RV function. There was thickened and calcified mitral leaflet with moderate mitral regurgitation and moderate mitral stenosis (MVA planimetry 1.5 cm², Wilkins Score 9). In our hospital, antiarrhythmic drug such as procainamide and propafenone were not available. We had a plan to refer the patient for radiofrequency (RF) ablation and mitral valve surgery, but she refused because of financial problem.

Conclusion. WPW syndrome concomitant with the presence of rheumatic mitral regurgitation is rarely found and may lead to a life-threatening preexcited atrial fibrillation. This condition could be refractory to medical therapy, so collaborative decision to perform RF ablation and surgery was needed.

Keywords : Rheumatic Mitral Stenosis, Wolff-Parkinson-White Syndrome, Atrial Fibrillation.

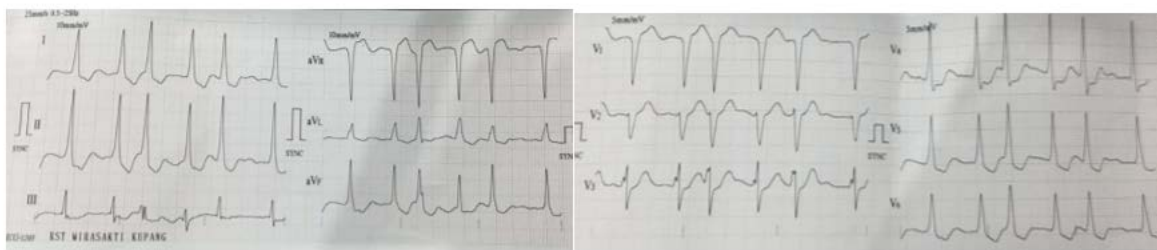


Figure 1. ECG Atrial fibrillation with delta wave appearance

Case report: Successful primary percutaneous coronary intervention in patient with ST elevation myocardial infarction, total atrioventricular block and diabetic ketosis

K. L. Kharimah¹, A. Nurizal¹

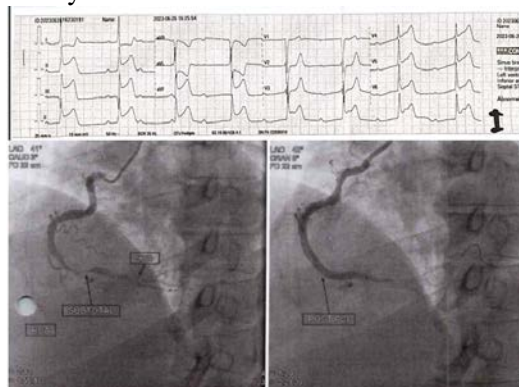
¹Hermina Depok Hospital, Depok, Indonesia

Background: Total atrioventricular block (TAVB) is a common complication of acute myocardial infarction, especially in inferior infarct location and associated with poor clinical outcomes. Primary percutaneous coronary intervention (PCI) can reduce mortality and morbidity in acute myocardial infarction patient.

Case Illustration: An 40 year old man, was referred to the emergency room department with a complaint of typical chest pain, the pain began 30 minute before hospitalization, pain is radiated to the back and accompanied by shortness of breath. The patient had no history of coronary artery disease nor diabetes mellitus, he had history of hypertension and during anti-hypertension therapy, he was an active smoker. Blood pressure was 118/79, pulse rate was 47 bpm, respiration rate was 28x/min, body temperature was 36,6C, and oxygen saturation was 99% on nasal cannula 3L/min. The electrocardiogram (ECG) of the patient showed TAVB rhythm of 50 beat per minute and inferior STEMI (Figure 1). The laboratory results were within normal limits, except that the blood glucose levels: 511 mg/dL and keton levels: 2.4 mmol/L. We diagnosed the patient with inferior STEMI, total atrioventricular block and diabetic ketosis. He was administered with aspirin and clopidogrel per oral, coronaryangiography (CAG) was performed. According to the CAG, subtotal occlusion was at the RCA (Figure 1). There was 90% stenosis in the left anterior descending artery (LAD). Besides, there were no stenosis on the left circumflex artery and the left main coronary artery. Primary PCI at the RCA was conducted using drug eluting stent (DES) and then thrombolysis in myocardial infarction (TIMI) grade 3 flow was shown at the RCA. Insulin therapy is given to treat diabetic ketosis.

Conclusion: The patient, with inferior STEMI and diabetic ketosis, complicated by total AV block, was treated with primary PCI and those were performed successfully. The complaint of ischemic chest pain was resolved, and blood glucose levels is in normal range.

Keyword: STEMI, TAVB, PCI, acute myocardial infarction



(Figure 1: ECG and angiography)



BRUGADA SYNDROME AND HYPOKALEMIA: THE DEADLY DUET

K. M. Pravdani¹

¹ Mitra Keluarga Kalideres, Jakarta, Indonesia.

Background: Brugada syndrome is a cause of sudden deaths among young adults, marked by distinct coved or saddle-shaped ST-segment elevation with T wave changes in V1-V3, accompanied by clinical symptoms and history. Here, we present a case of Brugada syndrome with severe hypokalemia leading to cardiac arrest.

Case Illustration: A 21-year-old woman presented to the hospital with weakness, profuse watery diarrhea, nausea and vomiting. Her brother had a history of sudden death at 23 years old. She had no previous syncope or palpitations episodes. She mounted a fever of 38.3°C and tetraparesis with 4/5 strength in all extremities. Other physical examinations were normal. Laboratory results showed elevated leukocytes with left shift differential count, hyponatremia, and severe hypokalemia 1.31 mmol/L. Chest radiograph showed a normal-sized heart. The ECG revealed normal sinus rhythm with RBBB-type ST elevation on V1 consistent with type 1 Brugada pattern and ST depression in V2-V6 and a long QT interval of 560ms. Her ischemic workup was normal. She was admitted to intermediate care and given intravenous fluid, potassium replacement, antibiotics, and antidiarrheal drugs, while awaiting referral for AICD placement. Within 6 hours of admission, she became unresponsive and developed ventricular fibrillation (VF). She was resuscitated and intubated. She underwent multiple cardiac arrest (4 times) within the hour with ECG showed ventricular tachycardia and asystole all over again. Despite attempted CPR including DC shock, the patient has deceased.

Conclusion: Patients with distinct Brugada pattern alongside severe hypokalemia should receive aggressive potassium replacement. At present, AICD placement is the sole effective method for averting sudden cardiac death from VT. The combination of Brugada syndrome and severe hypokalemia poses a life-threatening condition that must be treated immediately. It is crucial to give careful consideration to the limited resources and the urgency with which these cases need to be managed.

Keywords: Brugada syndrome, hypokalemia, cardiac arrest

Catastrophic Events of Concomitant Acute Coronary Embolism and Ischemic Stroke in Patient with Atrial Fibrillation: The Damage due to Oral Anticoagulant Discontinuation

K. M. Tandayu^{1,2}, Y. Aljaidi^{1,2}, M. K. Nissa^{1,2}, S. B. Raharjo^{1,2}, D. Y. Hermanto^{1,2}, D. A. Hanafy^{1,2}, Y. Yuniadi^{1,2}

¹Department of Cardiology and Vascular Medicine, Faculty of Medicine, Universitas Indonesia, Jakarta, Indonesia, ²National Cardiovascular Center Harapan Kita, Jakarta, Indonesia

Background: Persistent atrial fibrillation has a risk of stroke 3-5 times higher than the normal population. Anticoagulation is an effective treatment to prevent patients from fatal thromboembolic events, such as acute coronary embolism, ischemic stroke and acute peripheral artery disease. The benefit from anticoagulation outweighs the associated increase in the risk of bleeding. This case illustrates the importance of anticoagulation in atrial fibrillation patients undergoing cardiovascular procedures. Inadequate anticoagulant administration will increase mortality and morbidity that reduce quality of life.

Case Illustration: A 58 years old male with the diagnosis of Persistent AF CHA₂DS₂VASC 3 HASBLED 2 CAD s/p CABG (2007) was planned for LAA (left atrial appendage) closure procedure. AF ablation was no longer feasible due to huge LA dimension. Transoesophageal Echocardiography (TOE) was done previously and showed the LAA is Windsock morphology, with ostium diameter of 20-30 mm (3D) and landing zone diameter 21-23 mm (3D). There is no thrombus at LA, LAA and other cardiac structures. But spontaneous echo contrast (SEC) was observed at LA and LAA. Unfortunately, oral anticoagulation was stopped 2 days prior the TOE procedure. During LAA closure, transseptal puncture was done uncomplicatedly using a BRK-1 transseptal needle in the inferoposterior site of interatrial septum. Suddenly, the patient felt weakness on the left side of his body with decrease of consciousness. Concomitantly, patient complaint for chest pain and ECG showed ST-elevation in high-lateral lead. BP dropped to 60/30 mmHg, HR 130 bpm. Echocardiography evaluation showed no pericardial effusion was seen. In a flash, monitor ECG showed ventricular fibrillation, DC shock 200 Joule was performed. ECG converted to atrial fibrillation with rapid ventricular response. Primary PCI was planned. Heparin 400 IU was given intravenously. Ticagrelor 180 mg and aspirin 160 mg was given orally. Coronary angiography showed Total occlusion in proximal LCx, with thrombus at proximal part. Primary PCI was brought, 1 DES was implanted on proximal LCx. Angiography evaluation showed TIMI 3 flow, thrombus (-), residual stenosis (-), dissection (-). After the coronary problem was resolved, we decided to perform digital subtraction angiography (DSA) cerebrum right away, and the result displayed normal flow of cerebral artery. Unfortunately, we decided to postpone the LAA closure procedure. The patient then sent to cardiovascular care unit (CVCU) for stabilization. Bedside echocardiography showed 1.5 cm thrombus in LV. Cerebral non contrast MSCT examination showed hypodense lesion at the frontal lobe resembling non hemorrhagic CVD. Heparinization was done and bridged to oral anticoagulation. Patient was recovering, early rehabilitation was started. Patient was discharged after several days of hospitalization.

Conclusion: We presented a case of catastrophic events of consecutive acute STEMI and non hemorrhagic stroke most likely due to embolism, triggered by a short discontinuation of oral anticoagulation in patient with atrial fibrillation. This case displayed the harm of oral anticoagulation discontinuation, and the importance of thromboembolism prevention in patients with atrial fibrillation, especially with high risk score.

Keywords: Coronary Embolism, Stroke, Atrial fibrillation, Thromboembolism, Anticoagulant

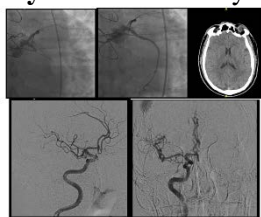

Figure 1. Concomitant acute embolism (a) total occlusion in proximal with thrombus in proximal part LCx; (b) 1DES implantation in proximal LCx; (c) hypodense lesion at the frontal lobe resembling non hemorrhagic CVD; (d&e) DSA showing normal flow of cerebral artery

Supraventricular Tachycardia Episode in a Adult Patient with Atrial Septal Defect Secundum

L. Calvrijne¹, K. Clara¹, G. Aprivita²

¹General Practitioner, Siloam Hospitals Sentosa, Bekasi, Indonesia

²Cardiologist, Siloam Hospitals Sentosa, Bekasi, Indonesia

Background : Atrial septal defect (ASD) represents a direct communication between atrial chambers, allowing shunting of blood between the systemic and pulmonary circulation. ASD represent the most common congenital heart disease diagnosed in adult-hood. One of the major sources of morbidity in the ASD patient population are atrial tachyarrhythmias (ATs) as atrial fibrillation, atrial flutter and supraventricular tachycardias. Supraventricular tachycardia (SVT) is a heterogeneous group of arrhythmias used to describe tachycardias that involve cardiac tissue at level of the bundle of His or above. SVT increases patient morbidity, particularly when symptoms are frequent or incessant, it can be life-threatening.

Case illustration : A 61 year old female was admitted to the emergency department on 2nd of June 2023 with palpitations 3 hours before admission. The patient also presented with nausea, vomiting, and pain in the epigastric region. She was fully alert and vital signs revealed blood pressure of 110/70mmHg, heart rate of 212 beats per minute, respiration rate of 24 breaths per minute, and oxygen saturation of 92% with room air. In April 2023 she was hospitalized due to an episode of Sinus Ventricular Tachycardia (SVT). Echocardiography results in April showed ASD with diameter 2.95cm. Electrocardiogram showed supraventricular tachycardia rhythm with rates of 212 beats per minute. Amiodarone 150 mg iv was administered over 10 minutes. ECG after amiodarone demonstrated atrial fibrillation with rate of 87 beats per minute. She was transferred to High Care Unit and after 5 days of treatment, the patient had no complaints and the vital signs were stable. Echocardiography on June revealed an increase in diameter of the ASD to 3.1cm, wider 0.15cm than the previous result.

Conclusions : Careful consideration is needed whether surgery (Atrial Septal Defect Closure) is necessary considering the patient's current age and history of co-morbidities. Routine medical monitoring and evaluation for life is necessary so that patients can receive optimal health services.

KEYWORD : Supraventricular Tachycardia, Atrial Septal Defect

Type II ST-Elevation Myocardial Infarction (STEMI) Induced by Anemia Presented with Cardiogenic Shock and Atrial Fibrillation with Slow Ventricular Response: A Case Report

L. Fahreza¹

¹Bintang Amin Hospital, Lampung, Indonesia

Background: While ST-Elevation Myocardial Infarction is often caused by occlusion of the coronary artery, it is not the sole cause. ST-Elevation Myocardial Infarction can also be triggered by metabolic diseases such as anemia, which occurs due to a low blood supply while in a high demand. Patients in this condition may not experience any symptoms unless they engage in activities that require greater demand on their heart. Furthermore, they may present to the Emergency Room with various symptoms.

Case Illustration: A 68-year-old Woman came to the Emergency Room because of general weakness preceded by chest pain that started 1 hour before presentation while she was praying. The chest pain was also accompanied by increased sweating. However, due to her weakness, the patient couldn't provide further details about the pain. Additionally, she appeared to have difficulty breathing. She had no history of hypertension or diabetes mellitus. Her blood pressure was 60/palpation, heart rate was 56 beats per minute with a weak and irregular pulse. During the general examination, there was irregularity in her heart rate without rales or any signs of congestion. Initial ECG on presentation (Figure 1) showed ST-Elevation in Lead II, III, and aVF with reciprocal wave in V1, V2, and V3, indicating a possible inferoposterior infarct. The ECG also showed Atrial Fibrillation with Slow Ventricular Response. Her hemoglobin was 7.7 g/dL and random blood glucose was 356 mg/dL. Furthermore, her laboratory examination revealed an elevated CKMB level one hour after the heart attack. After receiving initial treatment and being in a stable condition, the patient was transferred to a cardiologist at the referral hospital for further assesment and determine whether the patient required a transfusion or PCI (Percutaneous Coronary Intervention).

Conclusion: The underlying cause of myocardial infarction may vary among patients, and it is not always caused by an occluded coronary artery. This case report emphasizes the importance of comprehensive evaluation and a high index of suspicion for atypical presentations of STEMI, particularly in patients with known risk factors such as anemia. Moreover, this report highlights the need to address the underlying causes of STEMI to define further suitable treatment for better results.

KEYWORD: STEMI, Anemia, Cardiogenic Shock, Atrial Fibrillation

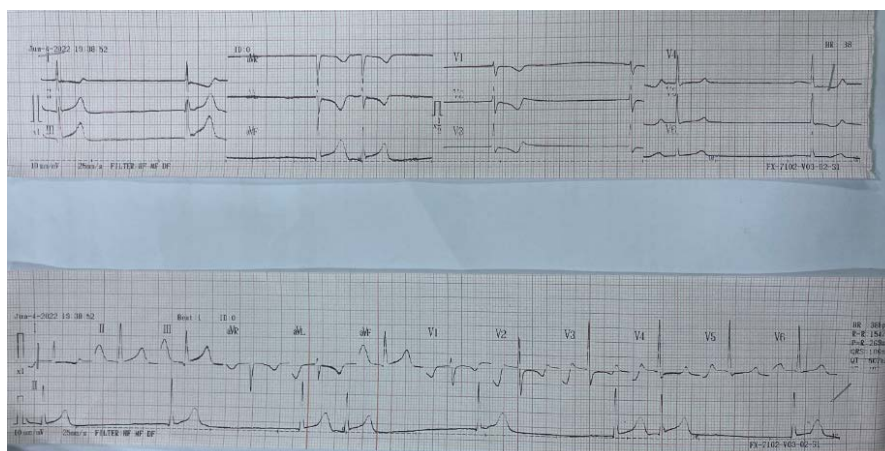


Figure 1. Initial ECG

SUPRAVENTRICULAR TACHYCARDIA IN WOLFF-PARKINSON-WHITE SYNDROME IN A PEDIATRIC PATIENT— CASE REPORT

L.H. Andira¹, D. N. Ghassani¹, M.R. Putra², R. Julario¹

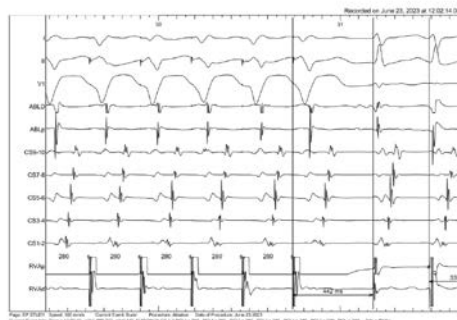
¹ Department of Cardiology and Vascular Medicine, Faculty of Medicine, Airlangga University - Dr. Soetomo General Hospital, Surabaya, Indonesia

² Faculty of Medicine, Airlangga University - Dr. Soetomo General Hospital, Surabaya, Indonesia

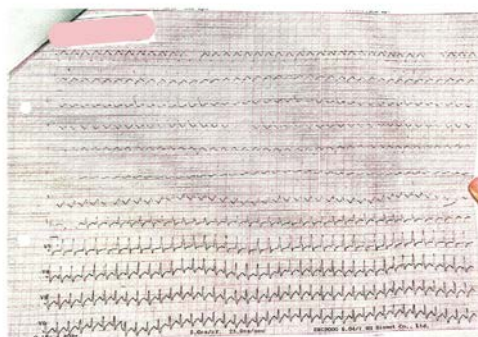
Background: Wolff-Parkinson-White (WPW) syndrome is a congenital cardiac preexcitation syndrome due to abnormal cardiac electrical conduction through accessory pathways (AP) that can result in life-threatening arrhythmias. Some accessory pathways will not manifest the described typical electrocardiogram (ECG) findings. Patients with WPW are frequently susceptible to paroxysmal supraventricular tachycardia (SVT). Atrioventricular Re-entrant Tachycardia (AVRT) is the most common cause of SVT in young children. Catheter ablation offers a potential cure for WPW syndrome.

Case Illustration: A 12-year-old boy was referred for electrophysiology opinion following the finding of documented SVT and a history of recurrent palpitation for 1 year without specific trigger. ECG showed normal sinus rhythm and echocardiogram was normal. Followingly, he underwent electrophysiology study (EPS). Ventricle overdrive pacing showed VAV pattern, PPI-TCL < 115ms and AV fusion at CS 1-2. Other pacing maneuver revealed: WP retrograde 265ms, AVN ERP retrograde 270ms, WP antegrade 340ms, AVN ERP antegrade < 290ms, and WP retrograde 275 ms. Radiofrequency ablation (RFA) is a treatment of choice when the EPS result revealed a WPW, specifically a LLAP WPW. After multiple RFA, there was AV dissociation, then we performed ventricular pacing and AV dissociation remained. We investigated SNRT and CSNRT, the results were within normal limits.

Conclusion: RFA is a highly successful approach for patient with WPW syndrome and it can prevent the risk of SCD from arrhythmia.



Top Panel: The result from ventricle overdrive pacing



Bottom panel: SVT on surface ECG

Ventricular tachycardia in a young man with symptoms of angina and an ischemic ECG: is it always acute coronary syndrome?

L.H. Zunardi¹, A. Rizal², M.S. Rohman²

¹Cardiology Resident at dr. Saiful Anwar Hospital, Faculty of Medicine Brawijaya Univeristy, Malang, Indonesia; ²Cardiologist, Cardiology and vascular department, Faculty of Medicine Brawijaya University, dr. Saiful Anwar Hospital, Malang, Indonesia

Background: Ventricular tachycardia (VT), a potentially fatal arrhythmia, is the primary cause of sudden cardiac fatalities. Ischemic heart disease is the underlying condition that most frequently causes ventricular tachycardia. Understanding the pathogenesis of VT and underlying structural heart disease is crucial for the proper management of VT and the avoidance of sudden cardiac death. The ability to differentiate between the many types and causes and to treat them correctly is a critical competency for emergency physicians.

Case illustration: A 33-year-old man, a smoker, was brought to the emergency department presenting with acute onset Angina, hypotension, cold acral and decrease of consciousness. ECG shows signs of VT. The patient was assessed as suspected of ACS. The patient was managed successfully with electrical Cardioversion, and continous with amiodarone I. Patient reverted to sinus rhythm with T inverted. patient was given O₂, IV fluid, tab Aspilet (300 mg), clopidogrel (300 mg). With these interventions used in quick succession, the patient was reversed to hemodynamic stability, did not have further episodes of VT. patient was assessed with very high-risk NSTACS criteria. The patient underwent immediate invasive coronary angiography (ICA) with minor disease.

Conclusion: Patients with clinical angina and an ischemic ECG suggestive of ACS are at high risk for VT, but the fact is that ACS or IHD are not always the cause of VT. The underlying cause must be investigated further after acute termination. Even if ICA show that coronary arteries are normal, a confirmation diagnosis may require an invasive electrophysiological examination.

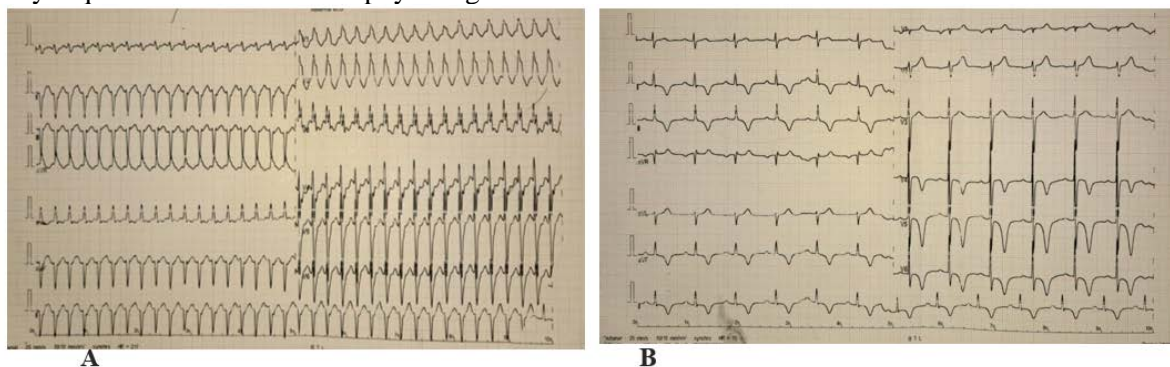


Figure 1 (A). A 33-year-old man comes to the emergency room with ECG ventricular tachycardia 217 beats per minute. (B) After cardioversion, ECG sinus rhythm with T Inversion in leads II, III, aVF, and V4–V6 was obtained.

Hyperacute T as Predictor New Onset STEMI in First Medical Contact, The Importance of Serial ECG Recording: A Case Report

M. A. Pasha¹, I. K. Susila²

¹Buleleng General Hospital, Bali, Indonesia

²Department of Internal Medicine, Division of Cardiology and Internal Medicine, Faculty of Medicine Universitas Pendidikan Ganesha / Buleleng General Hospital, Bali, Indonesia

Background: Acute coronary syndrome (ACS) is a life-threatening emergency in cardiovascular field. Rapid progressivity of the disease and life-threatening complications became the underlying causes. A properly simple history, early electrocardiography (ECG) examination following by serial ECG and cardiac marker in cases hold a significant role. In a hospital which does not have a facility for cardiac marker, serial ECG and history data can be a solution in the initial management of ACS, especially in the era of universal health coverage. This case report aims to determine benefits of a serial ECG combined with a proper history in the initial management of ACS cases.

Case Illustration: A male, 57 years old, came to the emergency department (ED) with non-radiating pain 30 minutes before admission. The pain was felt more severe with Difficulty breathing, cold sweat, and slight nausea. The medical history revealed that the patient smoked 6-8 cigarettes a day. Physical examination and vitals were stable. ECG serial recording is done below.

Conclusion: Periodic ECG recording should be performed to all patients with clinically suspected ACS to ruled out an acute sign of ACS (i.e Hyperacute T). This examination is fast, simple, and important. It can determined the clinical progressivity in early stage of the disease, increased accurately diagnose and provide early aggressive treatment especially in hospital with limited diagnostic facilities.

Keywords: Acute Coronary Syndrome; Hyperacute-T; Serial ECG

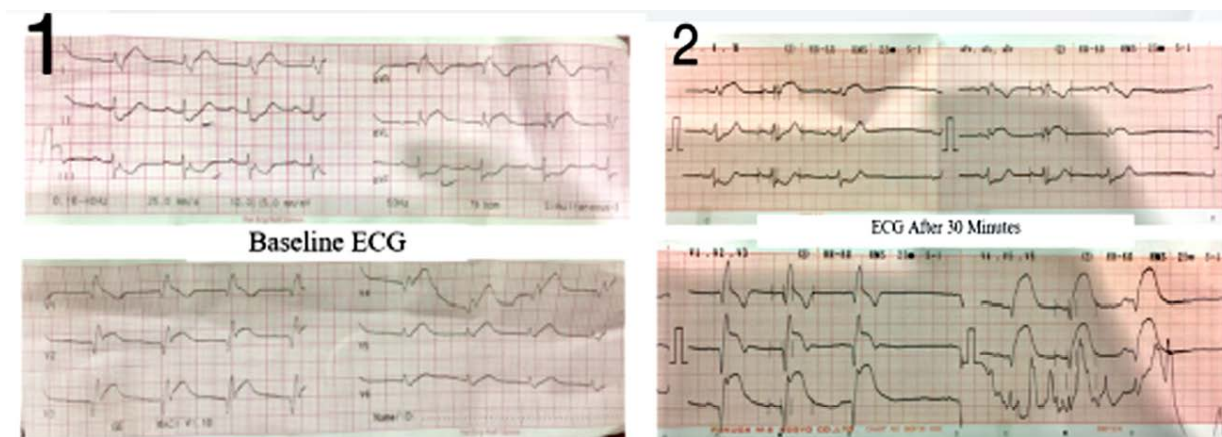


Figure 1 Electrocardiogram patient at first minutes (left) and 30 minutes after (right)
Based on the ECG recording above, it is suggested that there is a hyperacute T picture which is a marker of new onset STEMI. Furthermore, because the distance to the PCI center is more than 2 hours, it was decided to give thrombolytic therapy with 1.5 million units of streptokinase to the patient in ED.

Managing Atrial Fibrillation in The Elderly Patient in Rural Area: a Case Report

M. C. U. Aman¹

¹dr. Hendrikus Fernandez Hospital, Larantuka, Indonesia

Background: Atrial fibrillation is the most common arrhythmia found in the elderly. Its prevalence also increases with age. The morbidity of elderly patients with AF is important, as these patients show increased length of hospitalization due to heart failure, stroke, and associated side effects of antiarrhythmic therapy. However, in rural areas, some antiarrhythmic drugs are not available. It may be difficult to provide sufficient therapy for this case.

Case Illustration: A 79-year-old woman was referred to the emergency room with palpitations and mild shortness of breath. Initially, the patient complained of dizziness and weakness. Then since the last week, she has been complaining of mild shortness of breath when sleeping on her back and heart palpitations. There was no previous history of cardiovascular disease. She was fully alert with BP: 108/72 mmHg, HR: 156x/m palpable irregular, RR: 22x/m, and SpO₂: 98%. Physical examination was found normal. Blood count, electrolytes, liver function, renal function, TSH, and FT₄ test were normal. The first electrocardiogram (ECG) showed an irregularly irregular narrow complex tachycardia at a rate of 160 beats/min. A diagnosis of atrial fibrillation with a rapid ventricular response was made. Intravenous 0,5mg digoxin and 20mg furosemide were administered. A repeat ECG four hours later was obtained and showed captured beats indicative of atrial fibrillation with a normal ventricular response at a rate of 72 beats/min. Subsequently, the patient was admitted for a planned echocardiographic examination. Therapy is administered orally with digoxin and furosemide.

Conclusion: In rural areas with limited antiarrhythmic drugs and tools to control antiarrhythmic side effects, rhythm control therapy may be used as an alternative. This can help improve the success of therapy and prevent complications, especially in elderly patients without cardiovascular risk factors. However, in order to provide the best therapy, patients need to be referred to health facilities that are more complete and have cardiologists.

Keywords: atrial fibrillation, elderly patient, rural area.

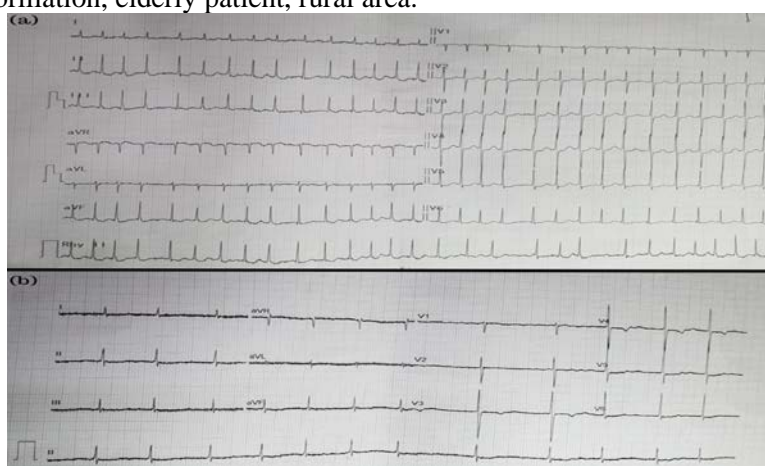


Figure 1. (a) First ECG; (b) ECG four hours after treatment.

Narrow QRS-Complex Tachycardia with Long-RP Interval : Three-Dimensional Mapping-Based Ablation

M. E. Santoso¹, T. Oktavio¹, E. J. Gunawan², A. Handayani², Johan², D. L. Munawar², B. Hartono², M. Munawar²

¹Departement of Cardiology and Vascular Medicine, Faculty of Medicine, Universitas Sam Ratulangi, Manado, Indonesia.

²Binawaluya Cardiac Center, Jakarta, Indonesia

Background: Narrow QRS complex tachycardias may present interesting diagnostic and therapeutic challenges. The differential diagnosis of a long-RP narrow QRS complex tachycardia includes atrial tachycardia, atypical AVNRT, and orthodromic AVRT using an accessory pathway that has a long VA conduction time. Advances in 3D electro-anatomic mapping-system technology allowed improve precision in the localization and ablation of target site, reducing radiation exposure without affecting success rate, complications, and recurrences.

Case Illustration: A 62-year old male with a history of palpitations. The ECG showed a regular narrow QRS tachycardia with long RP interval. Electrophysiology study revealed normal basic conduction intervals. During ventricular extra stimuli protocol a VA jump was noted at 500/450 ms. Tachycardia was induced by programmed stimulation from the ventricle. Tachycardia cycle length was 320 ms with VA interval > 70 ms, AH interval 116 ms, HA interval 192 ms. Earliest atrial activation was recorded in proximal CS. Tachycardia was entrained from the right ventricular apex at a pacing cycle length of 300 ms. The response of tachycardia upon termination of entrainment is V-A-V with PPI-TCL > 115 ms, and SA-VA > 85 ms. His synchronous ventricular extrastimulation from right ventricular apex failed to reset atrial activity. 3D anatomical mapping was performed to localize the slow pathway. Slow pathway ablation was performed at low Koch triangle until an accelerated junctional rhythm developed, with noninducibility of tachycardia beyond a single echo beat.

Conclusion: 3D anatomical mapping can assist in objective identification of the slow pathway area by mapping low voltage and late activation of the inferior triangle of Koch in sinus rhythm. It would facilitate an efficient fluorosless workflow during catheter ablation.

Keywords: Long R-P Tachycardia, 3D Ablation, Atypical AVNRT

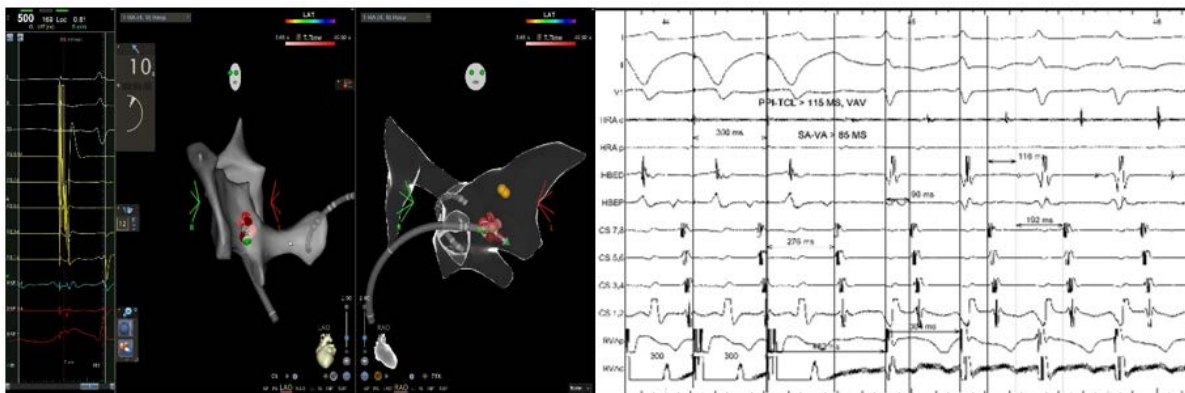


Figure 1. 3D anatomical mapping to show localization slow pathway and entrainment of the tachycardia from RV apex.

Incessant supraventricular tachycardia in a pregnant woman with atrial septal defect : A Case Report

M. F. Delong¹, F. Hidayati¹, E. Maharani¹

¹ Department of Cardiology and Vascular Medicine, Faculty of Medicine, Public Health and Nursing, Universitas Gadjah Mada – Dr. Sardjito Hospital, Yogyakarta, Indonesia

Background: Supraventricular Tachycardia (SVT) is one of the common cardiac arrhythmias with incessant tachycardia defines as tachycardia being present at least 90% of the monitored time. Women with established arrhythmias or structural heart disease are at highest risk of developing arrhythmias during pregnancy.

Case illustration: A 26 year old female with atrial septal defect (ASD) and history of SVT since three years before admission consulted to us from obstetrician because of sudden onset and persistent palpitation in her 38 weeks of pregnancy. She was put on bisoprolol and diltiazem with no recurrence while she was on these anti arrhythmics medication. Meanwhile she became pregnant, her first and second trimester were uneventful but she had a recurrence of palpitation during 35th week of pregnancy. On our examination she was conscious with heart rate of 180 per minute and blood pressure of 120/70 mmHg. The ECG showed a narrow complex tachycardia suggestive of SVT with stable hemodynamics. To terminate the SVT due to the unavailability of adenosine in our hospital the patient was given an injection of metoprolol three times. However it was unsuccessfully converted, subsequently we escalated to diltiazem. Proposed mechanisms include increased circulating levels of catecholamines during pregnancy, increased adrenergic receptor sensitivity and increased maternal effective circulating volume causing stretching of atrial wall. The therapeutic approach to arrhythmias in pregnancy is similar to that in the general patient without pregnancy. Adenosine is the drug of choice as it is safe and terminates about 90% of paroxysmal SVT. Intravenous metoprolol or propranolol should be used if adenosine is ineffective meanwhile verapamil and diltiazem is considered a third line agent for pregnant woman with SVT.

Conclusion: Episodes of SVT occur with increased frequency during pregnancy, especially in those with underlying congenital heart disease such as ASD. Acute management in pregnant patients with or without significant symptoms or hemodynamic instability is similar to non pregnant patients, with special consideration to safety issues of fetus, especially during the first trimester.

Keywords: Supraventricular Tachycardia; Pregnancy; Atrial Septal Defect

Reduce the Pulse to Prepare the Push! A Case Report on Successful Conversion of Incessant Supraventricular Tachycardia in A Pregnant Woman with Atrial Septal Defect

M. F. Delong¹, F. Hidayati², D.W. Anggrahini², L.K. Dinarti², E. Maharani²

¹Cardiology resident, Department of Cardiology and Vascular Medicine, Faculty of Medicine, Public Health and Nursing, Universitas Gadjah Mada – Dr. Sardjito Hospital, Yogyakarta, Indonesia

²Department of Cardiology and Vascular Medicine, Faculty of Medicine, Public Health and Nursing, Universitas Gadjah Mada – Dr. Sardjito Hospital, Yogyakarta, Indonesia

Background: Supraventricular Tachycardia (SVT) is one of the common cardiac arrhythmias with incessant tachycardia defines as tachycardia being present at least 90% of the monitored time. Women with established arrhythmias or structural heart disease are at highest risk of developing arrhythmias during pregnancy.

Case illustration: A 26 year old female with atrial septal defect (ASD) and history of SVT since three years before admission consulted to us from obstetrician because of sudden onset and persistent palpitation in her 38 weeks of pregnancy. She was put on bisoprolol and diltiazem with no recurrence while she was on these anti arrhythmics medication. Meanwhile she became pregnant, her first and second trimester were uneventful but she had a recurrence of palpitation during 35th week of pregnancy. On our examination she was conscious with heart rate of 180 per minute and blood pressure of 120/70 mmHg. The electrophysiology showed a narrow complex tachycardia suggestive of SVT with stable hemodynamics. To terminate the SVT due to the unavailability of adenosine in our hospital the patient was given an injection of metoprolol. However it was unsuccessfully converted, subsequently we escalated to diltiazem. However due to limitation to perform 3D mapping for atrial tachycardia ablation, the patient was planned to have electrophysiology (EP) study and ablation. After delivery we perform the EP study and the result was retrograde block, unsuccessful focal atrial tachycardia ablation with right sided focal atrial tachycardia (suspected RAA origin). Proposed mechanisms include increased circulating levels of catecholamines during pregnancy, increased adrenergic receptor sensitivity and maternal effective circulating volume causing stretching of atrial wall. The therapeutic approach to arrhythmias in pregnancy is similar to that in the general patient without pregnancy.

Conclusion: Episodes of SVT occur with increased frequency during pregnancy, especially in those with underlying congenital heart disease such as ASD. Acute management in pregnant patients with or without significant symptoms or hemodynamic instability is similar to non pregnant patients, with special consideration to safety issues of fetus, especially during the first trimester.

Keywords: Supraventricular Tachycardia; Pregnancy; Atrial Septal Defect

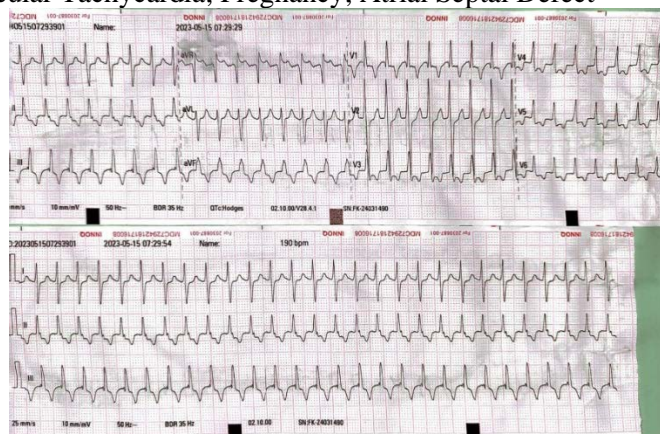


Figure I. ECG showed SVT short RP

Atrio-Fascicular Accessory Pathway: What Electrocardiography Characteristics Should We Know?

M. G. Perdana, C. L. Putra, F. Hanif, S. N. Irbah, F. Ahmad, Michael, N. S. Primaditta, N. A. Tafriend, Haikal, A. Harsoyo

Division of Electrophysiology and Device, Department of Cardiology, Gatot Soebroto Army Central Hospital, Jakarta, Indonesia

Background: Atrio-fascicular accessory pathway (AF-AP) is uncommon type of preexcitation. This accessory pathway (AP) has a decremental property and connect nodo-ventricular or a long pathway from atrial to distal right bundle branch (RBB) near moderator band. Embryologically, this pathway appears to be a duplication of atrioventricular (AV) node. There are electrocardiography (ECG) characteristics that can be used to predict AF-AP. In this case report, we try to describe the types of ECG characteristics in AF-AP.

Case Illustration: A 51-year-old man was referred to arrhythmia clinic with episode of palpitation and chest discomfort. He has a history of diabetes mellitus and smoker. ECG showed complete Left Bundle Branch Block (cLBBB) pattern and shortened PR-interval that indicates of AP. Treadmill test showed preexcitation pattern in whole procedure. Holter monitoring showed mainly sinus rhythm (SR) with preexcitation pattern. However, there was an episode of intermittent sinus rhythm without pre-excitation with normal PR-interval, notched at the terminal portion of QRS in inferior lead and rSr pattern in lead III. Echocardiography and coroangiography reveal normal results. The patient was sent for radiofrequency ablation (RFA). Electrophysiology study showed RBB potential preceding His potential and induced slow atrioventricular re-entrant tachycardia (AVRT) orthodromic that spontaneously terminated. AP potential was recorded in anterolateral tricuspid valve (TV) annulus. Multiple ablations at anterolateral TV area directly diminishes AP and no arrhythmia could be induced. Post ablation ECG showed SR with normal PR-interval and diminished notch in terminal portion of QRS in inferior lead.

Conclusion: The recognition of AF-AP from ECG was challenging. A short PR-interval and cLBBB pattern suggest preexcitation using AF-AP. Holter monitoring might be used to identified intermittent preexcitation and it useful to determine slurring or notching in end terminal of QRS complex in inferior lead during sinus rhythm with no preexcitation. RFA in AF-AP showed a high successful rate.

Keyword: Atrio-fascicular accessory pathway, electrocardiography

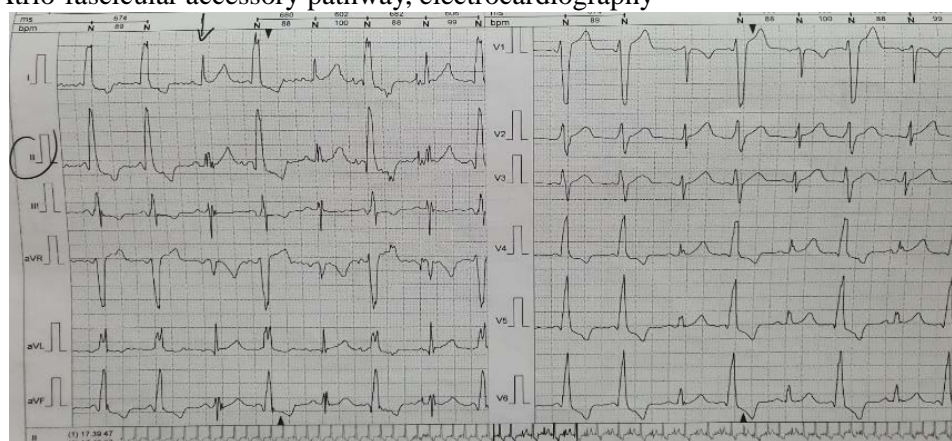


Fig 1. Holter monitoring showed cLBBB pattern, shortened PR-interval and episode of sinus rhythm. When sinus rhythm, it showed normal PR-interval, LBBB pattern, left axis deviation, rSr pattern in lead III and absence Q waves in precordial lead.

Electrolyte Imbalance Unveiling Ventricular Bigeminy: A Comprehensive Case Report of Hypokalemia-Induced Cardiac Arrhythmia

M. H. Baswedan¹, H. Attamimi¹

¹Department of Cardiology and Vascular Medicine,
Central Java Province, Pekalongan, Indonesia.

Background: Hypokalemia is a common electrolyte imbalance known to cause various clinical manifestations, including cardiac arrhythmias. Ventricular bigeminy, a rare and potentially life-threatening cardiac arrhythmia characterized by premature ventricular contractions alternating with normal sinus beats, is a rare but potentially life-threatening arrhythmia. This case report aims to provide a comprehensive analysis of a patient with hypokalemia-induced ventricular bigeminy, focusing on the diagnostic challenges, management strategies, and clinical outcomes.

Case Illustration: A 66-year-old female presented with chest discomfort and palpitations. She had a history of hypertension but no diabetes. The patient experienced vomiting and decreased appetite in the preceding 5 days and denied any diarrhea or misuse of laxatives or diuretics. Electrocardiogram (ECG) findings revealed sinus rhythm with ventricular bigeminy and a prolonged QT interval. No abnormality was observed in the ST-T segment. Further investigations unveiled hypokalemia (serum potassium level: 2,5 mmol/l), establishing hypokalemia as the underlying cause of cardiac arrhythmia. Prompt initiation of potassium intravenous and oral potassium supplements, accompanied by close monitoring of cardiac function led to the disappearance of ventricular bigeminy, as confirmed by a subsequent ECG.

Conclusion: This case report highlights the importance of recognizing and addressing electrolyte imbalances, specifically hypokalemia, in patients presenting with cardiac arrhythmias. The resolution of ventricular bigeminy following potassium supplementation underscores the role of hypokalemia as a causative factor. Early detection and appropriate management of electrolyte disturbances are essential for restoring normal cardiac rhythm and preventing potential complications.

Keywords: Hypokalemia, ventricular bigeminy, cardiac arrhythmia, electrolyte imbalance, potassium supplementation



**Diagnostic Modalities in Electrophysiological Disorder Secondary to Inflammatory
Cardiomyopath in Limited Facilities: A case series**

M.I. Rialdy¹, A.C. Lubis², S.K. Khaidirman³, C.A. Andra⁴

^{1,3} Cardiology Resident at Cardiac Center H. Adam Malik Hospital, Faculty of Medicine Universitas Sumatera Utara, Medan, Indonesia ^{2,4} Cardiologist at Cardiac Center H. Adam Malik Hospital, Faculty of Medicine Universitas Sumatera Utara, Medan, Indonesia

Background: Inflammatory cardiomyopathy is defined as occurrence of inflammation in heart muscle which can lead to impaired function or cardiac conduction with varying symptoms. The etiology of inflammatory cardiomyopathy is very varied. CMR and endomyocardial biopsy are still the key to make definite diagnosis. However, these examinations are not widely available in Indonesia. This study presents a series of cases how to utilize diagnostic challenges in patients with electrophysiological disorders related to inflammatory cardiomyopathy with variable facilities.

Case Illustration: Three patients came to Adam Malik Hospital with suspicion of heart rhythm disturbance associated with inflammatory cardiomyopathy. The first patient was 55 years old came to the emergency department with chief complaints is palpitation with serial ECG showing LBBB rhythm (Intermittent LBBB). The patient had undergone stress test, laboratorium test, coronary angiography and EP study with normal results however during stress test an LBBB rhythm was found and not exercise related. Echocardiography showed RWMA and decreased GLS; indicating early stage left ventricular dysfunction. We decided to refer patient for CMR which successfully revealed micro inflammatory and non-ischemic scar suggested a chronic myocarditis. The next patient, 47-year-old female, came with presyncope and ECG showed TAVB, frequent PVCs, and episode of polymorphic VT (TDP). The patient underwent echocardiography with no significant abnormalities found. Due to her complicated presentation, patient underwent endomyocardial biopsy which showed multiple fibrosis, which is more common in acute myocarditis. The used of steroid was successful to revert her rhythm back to sinus. Last patient, 51-year-old male with fatigue and ECG showed TAVB. The patient underwent echocardiography with no significant abnormalities found, including normal coronary by angiography. Patient underwent CT-Scan thorax The result was fibrosis lines with multiple calcified nodules in both lungs measuring several mm 1.7 cm, depicting calcified tuberculoma. Bullae in the upper lobe of the left lung measuring +/- 1.7 cm with suspicion of sarcoidosis. After pacemaker implantation, a plan to perform extra-cardiac biopsy was made, however the patient refused to proceed.

Conclusion: The diagnosis of inflammatory cardiomyopathy is difficult, challenging and requires various modalities. Establishing the etiology of electrophysiological disorder related to inflammatory cardiomyopathy is essential to provide a definite management.

Keywords: Inflammatory cardiomyopathy, electrophysiology disorders

Tabel 1: Patients' Demographics and Characteristics

	Patient 1 (AR)	Patient 2 (S)	Patient 3 (DMS)
Demographics			
Age (years)	51	47	55
Gender	M	F	F
Symptoms and vital sign			
Chief Complaint	Fatigue since 4 months ago	Presyncope since 12 hours ago	Palpitation since 3 years ago
Other symptoms	Dizziness and presyncope	Dizziness and seizure	Dizziness
BP (mmHg)	155/65 mmHg	110/60	100/70
Admission HR (beats per min)	30 bpm	38	82
Physical examination and Routine testing			
Physical Examination	Within Normal Limit	Within Normal Limit	Within Normal Limit
CXR findings	AO dilatation	Normal	Normal



ECG findings	TAVB, QRS rate 30x/i	TAVB, QRS rate 30x/I with documented polymorphic VT (Torsade de pointes)	Sinus rhythm with documented sinus rhythm with LBBB
TMT	None	None	LBBB without any symptom at low workload
Laboratory result	Within normal limit	Within normal limit	Within normal limit
Echocardiography	<ul style="list-style-type: none"> • Good LV systolic function • Global normokinetic • No myocardial hypertrophy or sparkling. • Good GLS, does not show cherry on top picture 	<ul style="list-style-type: none"> • Good LV Systolic Function • MR mild d/t functional • TR mild d/t functional 	<ul style="list-style-type: none"> • Good LV systolic function, with decrease GLS (-9.3) • LV concentric remodelling • MR mild d/t functional
Holter	None	None	<ul style="list-style-type: none"> • ECG at rest: SR and LBBB with no PAC found. There were 2 basic rhythms in the patient, namely sinus rhythm and sinus rhythm with LBBB in the patient. Sinus rhythm + LBBB was found during holter for 565 minutes (39.2%).
EP Study	None	None	<ul style="list-style-type: none"> • Sinus rhythm with LBBB that is not associated with symptoms • No arrhythmia is triggered and the cardiac conduction system within normal limits.
Coronary angiography	Normal coronary arteries	Normal coronary arteries	Non-significant lesion
Additional testing			
CT Scan Throax	<ul style="list-style-type: none"> • Lines of fibrosis with multiple calcified nodules in both lungs, depicting calcified tuberculoma. • Bullae in the upper lobe of the left lung measuring +/- 1.7 cm. • Cardiomegaly with a pacemaker attached with the distal end in the right ventricle. 	<ul style="list-style-type: none"> • Multifocal consolidation in the posterior lower lobe of the right-left lung. • Ground glass in the upper lobe of the left lung, depicting pneumonia. 	None
Cardiac Magnetic Resonance	None	None	<ul style="list-style-type: none"> • Normal LV and RV chamber dimension and function. • Microinflammatory and non-ischemic scars were found in several regions, suggested with chronic myocarditis.
Endomyocardial Byopsy	None	Multiple fibrosis, which is more common in acute myocarditis	None



Intermittent Left Bundle Branch Block Assessment: Benign or Harmful Condition?

M.I. Rialdy¹, A.C. Lubis², S.K. Khaidirman³, C.A. Andra⁴

^{1,3} Cardiology Resident at Cardiac Center H. Adam Malik Hospital, Faculty of Medicine Universitas Sumatera Utara, Medan, Indonesia ^{2,4} Cardiologist at Cardiac Center H. Adam Malik Hospital, Faculty of Medicine Universitas Sumatera Utara, Medan, Indonesia

Background: Prevalence of Left Bundle Branch Block (LBBB) in general population is very rare. LBBB can be caused by reversible cardiomyopathy that causes decreased left ventricular function, so called LBBB induced cardiomyopathy (LIC). Asynchronous electrical and mechanical activation in LBBB cause prolonged activation of the left ventricle. LIC is suspected in cardiomyopathy patients with chronic LBBB (LBBB > 5 years with good left ventricle systolic function (LVEF > 50%) accompanied by a progressive decrease of LVEF to <40%, worsening NYHA class and no other cause of cardiomyopathy found. In general, mild LV dysfunction is an early sign of LIC.

Case Illustration: A 55 year old female patient came with complaints of palpitation and history of fainting for the past 3 years without any evidence of tachycardia episode. Her ECG showed sinus rhythm while her serial ECG revealed a LBBB. The patient undergone coronary angiography with non-significant lesion. Holter monitoring was performed and showed sinus rhythm with intermittent spontaneous initiation and termination of LBBB which not related to her heart rate; LBBB burden was 39%. Trans-thoracic echocardiography showed normal left ventricular ejection fraction (LVEF) however the GLS (-9.3) was reduced. Furthermore the patient undergone the electrophysiology study with normal basic intervals and no arrhythmias inducible At this stage we conclude this patient with intermittent LBBB and early stage LV systolic dysfunction, however the etiology remained unclear. CMR examination showed normal chamber dimension with good LV dan RV systolic function. Microinflammatory and non-ischemic scars were found in several regions, suggested with chronic myocarditis. Patient is planned to undergone resynchronization therapy to improve asynchronous electrical and mechanical activation.

Conclusion: The occurrence of LBBB is an abnormality that closely related to cardiomyopathy in patients with naive or pre-existing heart failure. It is important to recognize LBBB early and managed properly.

Keywords: LBBB, induced Cardiomyopathy

Ablate or not to Ablate? : A Case of Parahisian Premature Ventricular Complex (PVC)

Michael¹, N.S. Primaditta¹, R. Wahyuni¹, E. Mariska¹, R.S. Ayuningtyas¹, S. Hidayatullah¹, Haikal²,
N.A Tafriend², A Harsoyo²

¹ General Practitioner, Gatot Subroto Indonesia Army Central Hospital, Jakarta

² Cardiologist, Gatot Subroto Indonesia Army Central Hospital, Jakarta

Background: Radiofrequency catheter ablation (RFCA) of PVC from parahisian area can be frequently challenging due to high risk of complete AV block and lower long term successful rate than other location. Combination of RFCA and pharmacological therapy should be considered to improve clinical outcome.

Case Illustration: A 56 years old man came to arrhythmia clinical with palpitation. His electrocardiogram (ECG) showed frequent PVC with inferior axis, LBBB pattern with positive deflection in lead I, R in aVL and early precordial transition in V2 suggest originating from parahisian. 24 hours holter monitoring showed 40% PVC burden mainly from parahisian area. He had history of hypertensive heart disease, type II diabetes mellitus, and non haemorrhagic stroke. The patient was then scheduled to undergo 3D ablation. Local activation time (LAT) mapping showed that earliest site was found in basal anteroseptal septal near His area with -37ms with recorded His potential at proximal pole, while unipolar recording showed slurred QS morphology. Pacemap showed 12/12 morphology similarity. Multiple ablation using irrigated ablation and long sheath was attempted using RF titration 10-30W, and impedance of 110-130 ohm at this site frequently induced accelerated junctional rhythm and vanished PVC transiently but then persisted later and suppressed. ECG monitor showed complete RBBB (cRBBB). The earliest site in LAT point was already ablated, however there were still large area of His potential recorded, the procedure was decided to be stopped. Holter evaluation showed significant improvement in PVC burden, from the previous 40% to 12%. Antiarrhythmic class IV was added which significantly relief his symptom.

Discussion: RFCA of PVC originated from parahisian region could be challenging due to high risk of iatrogenic atrioventricular block. It is paramount to avoid ablation over relatively close from proximal His. RFCA combination with pharmacological therapy can carry a good clinical outcome.

Conclusion: RFCA due to PVCs in Parahisian area is treatable. Procedure should performed carefully due to its potential of causing further complications. RFCA and pharmacological therapy should be considered to improve patient symptoms and reduce PVC burden.

Keywords: Parahisian PVC, radio frequency catheter ablation, pharmacological therapy

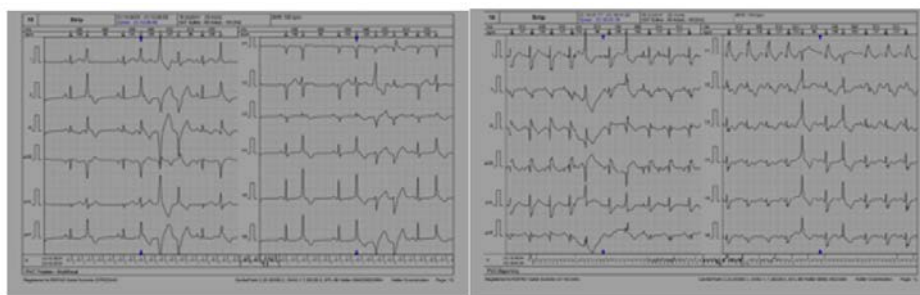

Figure 1. ECG before 3D ablation (left) and after 3D ablation (right)

Concealed Wolff-Parkinson-White Syndrome Unfolded by Induced Tachycardia: Case Report

M.J.N. Nasution¹, A.C. Lubis²

¹Faculty of Medicine, Universitas Sumatera Utara, Medan, Indonesia

²Departement of Cardiology and Vascular Medicine, Faculty of Medicine, Universitas Sumatera Utara, Medan, Indonesia

Background: Wolff–Parkinson–White (WPW) syndrome is a conduction disturbance in which atrial impulses are transmitted to the ventricles by an accessory pathway instead of the normal atrioventricular conduction. This results in classical delta waves, shortened PR interval and widened QRS complex. However, these electrocardiogram (ECG) abnormalities caused by accessory pathway may not be found in patients presenting with sinus rhythm. These patients symptoms only occurred when tachycardia presents. Thus, a further electrophysiology study is needed to confirm patients with concealed WPW.

Case illustration: A female, 56 years old was referred with history of haemodynamic instability during tachycardia. During admission, her ECG shown sinus bradycardia without pre-excitation (Fig. 1a). During EP procedure, a concentric coronary sinus activation was found in sinus rhythm (Fig. 1b). Interestingly, an eccentric coronary sinus activation appeared during tachycardia (Fig. 1c). Further mapping and diagnostic maneuvers confirmed an antidromic Atrioventricular Re-entry Tachycardia (AVRT) using left lateral accessory pathway. Catheter ablation by trans-septal successfully abolished the pathway. Concealed WPW occurs when the accessory pathway blocks antegrade transmission of electrical impulses, allowing only the normal AV conduction pathway to function during normal sinus rhythm. However, when reentrant tachycardia was produced by AV node, the accessory pathway can conduct retrogradely, showing the distinctive ECG abnormalities linked to WPW syndrome.

Conclusion: Abnormal activation from accessory pathway may only present in certain circumstances, understanding accessory pathway mechanism is essential for diagnosis and treatment.

Keywords: Wolff-Parkinson-White syndrome, tachycardia, AVRT, antidromic, concealed

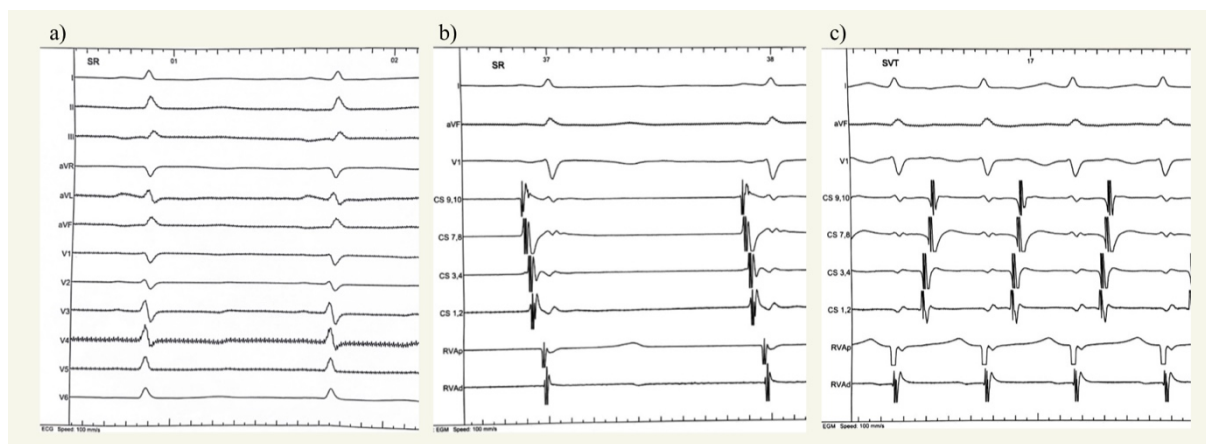


Figure 1. a) ECG during sinus showing bradycardia without pre-excitation. b) EGM during sinus showing concentric coronary sinus activation. c) EGM during induced tachycardia, showing eccentric coronary sinus activation.

Left Bundle Branch Area Pacing : an Emerging Role in Ventricular Pacing

M.J.N. Nasution¹, A.C. Lubis²

¹Faculty of Medicine, University of North Sumatera, Medan, Indonesia

²Departement of Cardiology and Vascular Medicine, Faculty of Medicine, University of North Sumatera, Medan, Indonesia

Background: Conduction system pacing (CSP) is a technique of pacing that involves implantation of permanent pacing leads directly into sites of the cardiac conduction system, such as His bundle or left bundle branch area pacing (LBBAP). This method is believed to offer more benefit as a treatment on various arrhythmia cases compared to conventional biventricular pacing (BVP). In this case report, the authors show the result of latest LBBAP procedure at their center.

Case Illustration: A 57 years old male patient was referred by cardiologist with history of dizziness since this past month. Complaints of chest pain and shortness of breath were denied. Patient is currently diagnosed with heart failure with preserved ejection fraction (HFpEF) with on going routine medication. The electrocardiogram (ECG) shown a slow irregularly irregular rhythm with no isoelectric baseline, interpreted as atrial fibrillation with slow ventricular response (AF SVR) (Fig. 1a). Considering his condition and co-morbidities, a decision to implant conduction system pacing with left bundle branch area pacing was made. The procedure was performed under deep sedation, Right ventriculography was used to mark atrioventricular border. An imaginary line was drawn to predict the location of left bundle branch between His bundle and right ventricular apex. Pacing was done in the location and W pattern was found, indicating the location of left bundle branch area (Fig. 1b). The lead was then drilled into left bundle branch at the chosen location and connected to generator. The generator was implanted in a pocket at left thoracal region. After procedure, the ECG shown sinus rhythm with normal rate (Fig. 1c).

Conclusion: Conduction system pacing is becoming preferred method in ventricular pacing method due to its more physiological activation, lower cost, better inter-ventricular resynchronization and better prognosis.

Keywords: Conduction system pacing, atrial fibrillation, left bundle branch area pacing

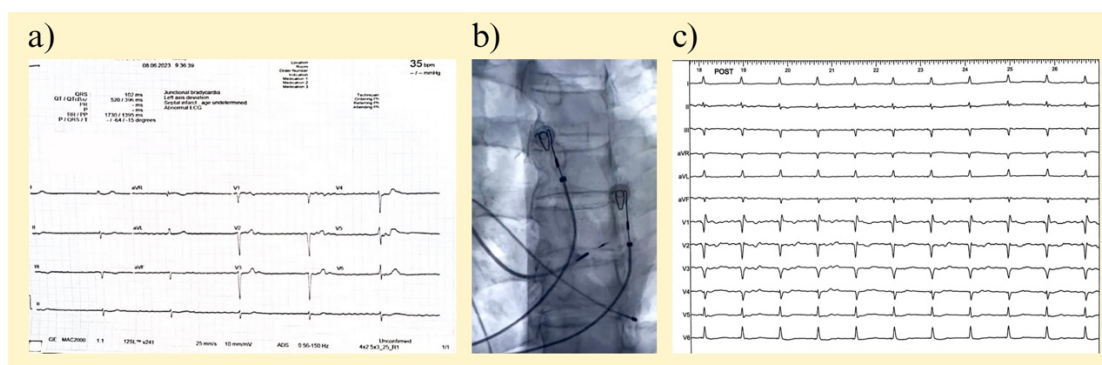


Figure 1. a) ECG showing atrial fibrillation with slow ventricular response. b) Right ventriculography showing lead drilled into left bundle branch area. c) ECG after procedure showing sinus rhythm with 70 beats per minute rate.

The Tachy-Brady Syndrome in 68 Years Old Male With History of Inferior Infarct : A Case Report

M. Mohamad¹, R. Ayuningtyas², A. Ciptasari², S. Inayasari², L. Pribadi³, M. G. Suwandi³

¹Internship General Practitioner, RSPAU dr. Suhardi Hardjolukito, Yogyakarta, Indonesia

²General Practitioner, RSPAU dr. Suhardi Hardjolukito, Yogyakarta, Indonesia

³Cardiologist, RSPAU Dr. Suhardi Hardjolukito, Yogyakarta, Indonesia

Background: Tachy-brady syndrome is defined by bradycardia alternating with paroxysmal supraventricular arrhythmias. It affects 50% patients with sinus node dysfunction.¹ A sinoatrial artery narrowing can lead to impairment of the sinus node function leading to sinus node dysfunction. Almost all such cases are present in inferior myocardial infarction.²

Case Illustration: A 68-years-old male came to ER with history of syncope 5 hours prior. At the moment the patient felt weak and lightheaded; he had 3 episodes of syncope preceded by dizziness, nausea and vomiting. After syncope he got burn sensation in his chest. The ISDN has been taken after burn sensation, but the symptom did not relieve. He has two times acute coronary syndrome history, 2 and 3 years ago. The vital sign showed alteration of heart rate from bradycardia, 47 times per minute (TPM), to tachycardia 121 TPM. In Physical examination there was cardiomegaly and minimal rales in 1/3 basal pulmonary. The first 12-lead electrocardiogram (ECG) showed sinus bradycardia with Q pathologies in lead II, III, aVF. Then the monitor ECG was performed and showed alternating rhythm from supraventricular tachycardia to sinus paused then became sinus bradycardia. This examination indicated impairment of sinus node that could be the complication of right coronary artery occlusion which happened two times before. The patient was diagnosed with inferior old myocardial infarct with tachy-brady syndrome. The patient was hospitalized and received heparin for 3 until 5 hours, fondaparinux 2.5mg, aspilet 80mg, clopidogrel 75mg, rosuvastatin 20mg, candesartan 4mg. Echocardiography and holter examination was planned.

Conclusion: Sinus node is perfused by the sinoatrial nodal artery, which arises from the right coronary artery in 60 % of the time. The occlusion of this artery can lead to sinus node dysfunction which almost all such cases are present in inferior myocardial infarction.² In this case, the patient got inferior myocardial infarction twice that perfused by right coronary artery. The SND could be the complication of the past cardiac events, aggravated with patient's lack of medication compliance hence the ongoing chronic ischemia.

Keywords: Tachy-brady syndrome, SND, Inferior infarct, arrhythmia

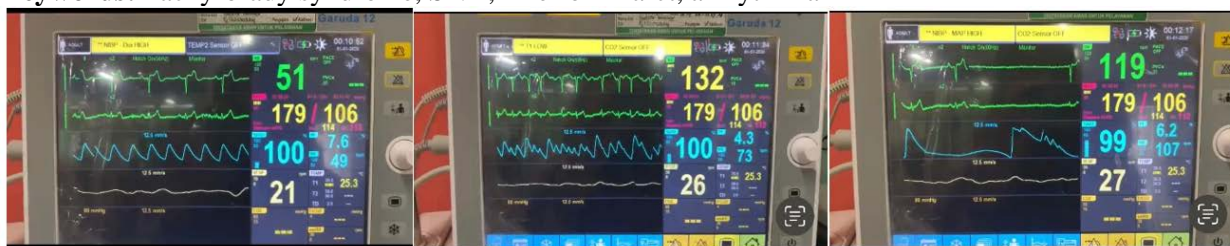

Image 1. Altered Rhythm



The Ultimate Phenomenon of Ebstein's Anomaly With Coexistence of Preexcitation Syndrome A Serial Rare Cases

M.R. Felani¹, M.I. Tuasikal¹, D.Y. Hermanto², S.B. Raharjo², D.A. Hanafy², Y. Kurniawati³, Y. Yuniadi²

¹Resident of Cardiology and Vascular Department, Medical Faculty of Universitas Indonesia, National Cardiovascular Center Harapan Kita (NCCHK), Jakarta, Indonesia

²Staff of Arrhythmia Division, Cardiology and Vascular Department, National Cardiovascular Center Harapan Kita (NCCHK), Jakarta, Indonesia

³Staff of Pediatric Cardiology and Congenital Heart Disease, Cardiology and Vascular Department, National Cardiovascular Center Harapan Kita (NCCHK), Jakarta, Indonesia

Background: Ebstein's anomaly is an uncommon congenital cardiac malformation accounting for fewer than 1% of congenital heart defects. Pathological abnormalities in Ebstein's Anomaly provide substrate for development of both supraventricular and ventricular tachyarrhythmias. Preexcitation and Wolff-Parkinson-White (WPW) syndrome are more frequently associated with this anomaly than any other congenital heart defect. Electrophysiology study is the gold standard of diagnostic to demonstrate the accessory pathway, and radiofrequency catheter ablation is the main therapeutic approach for these patients. The purpose of the case report is to review the tachyarrhythmia phenomena in Ebstein's anomaly patients and its management.

Case Illustration: Case #1: A 18-year-old man with chief complaint of palpitation and an evidence of narrow QRS complex tachycardia from electrocardiogram, and echocardiography findings revealed Ebstein's anomaly and moderate tricuspid regurgitation. The patient underwent 3D ablation and the result was successful ablation of concealed accessory pathway at the posterolateral site of atrialized right ventricular. Case #2: A 45-year-old woman with chief complaint of palpitation and dyspnea on exertion, echocardiography findings revealed Ebstein's anomaly, bidirectional shunt of secundum atrial septal defect, and severe tricuspid regurgitation. Electrocardiogram showed Atrial flutter 2:1 conduction with delta wave seen in all leads. The patient underwent 3D ablation and the result was successfully ablation of cavo-tricuspid isthmus (CTI) and right posteroseptal accessory pathway.

Summary: The association of supraventricular arrhythmia in patient with Ebstein's anomaly and accessory pathway is high in accordance to the case report. In addition of concealed accessory pathway in case #1 and concomitant atrial flutter in case #2, both patients underwent successful radiofrequency catheter ablation as the definitive treatment approach.

Keywords: Ebstein's Anomaly, Wolff-Parkinson-White Syndrome, Atrial Flutter, Radiofrequency Catheter Ablation



A Rare Case Presentation

Wolff-Parkinson-White Syndrome and Pre-excitation Induced Cardiomyopathy: Is It a Causal or Casual Relationship?

M.R. Felani¹, D.A. Hanafy², D.Y. Hermanto², S.B. Raharjo², Y. Yuniadi²

¹Resident of Cardiology and Vascular Department, National Cardiovascular Center Harapan Kita (NCCHK), Jakarta, Indonesia

²Staff of Arrhythmia Division, Cardiology and Vascular Department, National Cardiovascular Center Harapan Kita (NCCHK), Jakarta, Indonesia

Background: Patients with Wolff-Parkinson-White (WPW) syndrome, presence of an accessory pathway (AP), results in palpitation symptom most commonly due to Atrioventricular Reciprocating Tachycardia (AVRT). The mechanism for the development of left ventricular (LV) dysfunction in patients with pre-excitation syndrome has not yet been fully elucidated, and its prevalency in Indonesia is not fully well known. The eccentric ventricular activation via AP, may arise in right-sided AP, could result in an asynchronous spread of ventricular depolarization, then leads to LV mechanical and electrical dyssynchrony that could worsened LV dysfunction, known as Pre-excitation Induced Cardiomyopathy (PIC). Our objective in the case report is to review the impact of right AP of pre-excitation Syndrome resulting in PIC and to discuss the result of successful right AP ablation for LV systolic function improvement of our patient in NCCHK.

Case Illustration: A 12-year-old female patient with WPW Syndrome accompanied by chronic heart failure symptom came to NCCHK. Echocardiography revealed a suggesting non-ischaemic cardiomyopathy with 18% of initial LV ejection fraction (EF) and global hypokinetic. 12-lead electrocardiography (ECG) showed right anterior side of pre-excitation pattern. During the radiofrequency ablation (RFA), the AP was found in the right anterior location, in accordance with the ECG analysis. The right anterior AP ablation procedure was done successfully. One year after successful AP ablation, patient's LVEF was gradually increased to 41%.

Conclusion: The cardiomyopathy in this patient was presumably due to LV dyssynchrony from marked ventricular pre-excitation. The right anterior AP of the patient had successfully ablated with no significant heart failure symptom were recognized by the patient until now. Long-term follow-up, especially on clinical and echocardiographic results, still needs to be done routinely. By far, the patient's LVEF improvement has been excellent without remaining symptoms.

Keywords: WPW Syndrome, Cardiomyopathy, LV Dyssynchrony

CISPLATIN-INDUCED TOTAL ATRIOVENTRICULAR BLOCK FOLLOWING CHEMOTHERAPY IN A PATIENT WITH LARYNX CARCINOMA: A CASE REPORT

M. S. Dhani¹, D. J. Pesireron², A. Y. A. B. Mochtar², P. Ardianto²

¹Faculty of Medicine Diponegoro University, Semarang, Indonesia

²Departemen Cardiovascular, Central General dr Kariadi Hospital, Semarang, Indonesia

Background: Cardiotoxicity induced by cisplatin is rare, especially in case of total atrioventricular block and its pathophysiology is unclear. Electrolyte imbalance, nephrotoxicity, nausea and vomiting are more common adverse event in patient with this chemotherapeutic drug. We have reported a case of complete total atrioventricular block following cisplatin based-chemotherapy that required a pacemaker placement.

Case Illustration: A 77 years old man with larynx carcinoma admitted to emergency department with general weakness. The patient had received a cisplatin-based chemotherapy for 3 months He had history of diabetes and hypertension, but no history of structural heart disease and normal ECG results before the chemotherapy. The patient developed general weakness and symptomatic bradycardia after the fourth cycle infusion of cisplatin. The ECG showed total atrioventricular block, without chest pain or infection-related symptoms. The laboratory findings revealed normal serum electrolyte and troponin level. Echocardiography revealed normal left ventricular systolic function with global normokinetic. We assumed that cisplatin directly caused the total atrioventricular block. The patient underwent a permanent dual chamber pacemaker placement due to irreversible persistent total atrioventricular block. Follow up electrocardiogram revealed a good atrial sensing ventricular pacing.

Conclusion: Total atrioventricular block is a rare but life threatening arrhythmia that should not be neglected in a patient with admission of chemotherapeutic drug, including cisplatin based-chemotherapy. Electrocardiogram routine monitoring is highly recommended in patient with long term cisplatin-based chemotherapy.

Keywords: total atrioventricular block, cisplatin, chemotherapy, pacemaker

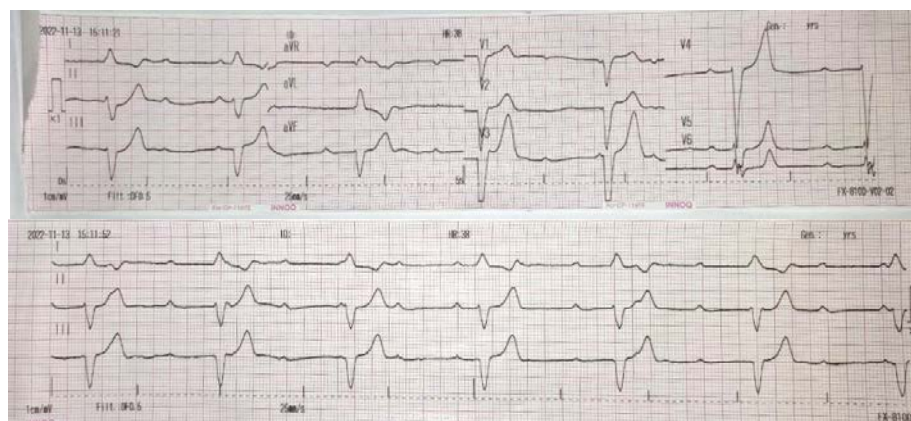


Figure 1. Total Atrioventricular Block Recorded at 12 leads ECG

**Third Degree Atrioventricular Block in Multiple Myeloma Patient Treated with Thalidomide:
Degenerative or Induced?**

M. Syahriza¹, F. Hidayati², E. Maharani²

¹Cardiology resident, Department Cardiology and Vascular Medicine, Faculty of Medicine, Public Health, Nursing Universitas Gadjah Mada - Yogyakarta; ²Department Cardiology and Vascular Medicine, Faculty of Medicine, Public Health, Nursing Universitas Gadjah Mada - Yogyakarta

Background: Had been withdrawn due to devastating teratogenic effect in 1961, thalidomide exhibited efficacy and obtained FDA-approval in 1998 for the treatment of multiple myeloma patient. However, the used of this antineoplastic agent revealed the more frequent cardiac side-effect involve heart conduction and rhythm.

Case Illustration: A 75-year-old male was referred to emergency room of Dr. Sardjito Hospital due to hypotension, total atrioventricular block and the history of undocumented ventricular tachycardia. The patient was diagnosed with multiple myeloma that confirmed by bone marrow puncture and immunoserology test in 2019 and undertaken thalidomide agent 10 mg twice a day with the absence of cardiotoxicity monitoring. The patient has also been being a transfusion-dependent refractory anaemia since then. The patient with a comorbid of insulin dependent diabetes mellitus for the last one year, underwent temporary pacemaker implantation and discontinued thalidomide. An ECG demonstrated a third degree atrioventricular block with a ventricular rate of 50 beat per minute and bigeminy ventricular premature contraction and a documented standstill on the ECG evaluation (Fig. 1). This condition could be related to the mechanism of over activity of parasympathetic caused by inhibition of TNF- α in the dorsal motor neurons of vagus nerve. Presenting thrombocytopenia and leucocytosis, normal electrolyte and increase of creatine on the admission and significant worsening of thrombocytopenia and leucocytosis to $48 \times 10^3 \mu\text{L}$ and $28.7 \times 10^3 \mu\text{L}$, respectively in the following day, the implantation of permanent pacemaker was postponed as a result of clinical conference across medical speciality regarding the undesirable outcome of the patient within the current clinical state. On the fourth day of the admission, patient felt in to septic shock and mental alteration with blood gas revealed a metabolic acidosis state with the sign of severe hypoperfusion, the patient proceeded to mechanical ventilator. Over all the condition, the patient beyond all help on the fourth day of admission with the cause of death was septic shock.

Conclusion: It is important to monitor patients taking thalidomide for signs and symptoms of bradycardia or higher degree AV block, especially in those with concomitant medications affecting cardiac conduction. Early detection of conduction delay might help to modify therapy before symptomatic clinical events occur.

Keywords: Thalidomide, Multiple myeloma, Atrioventricular block, drug induced

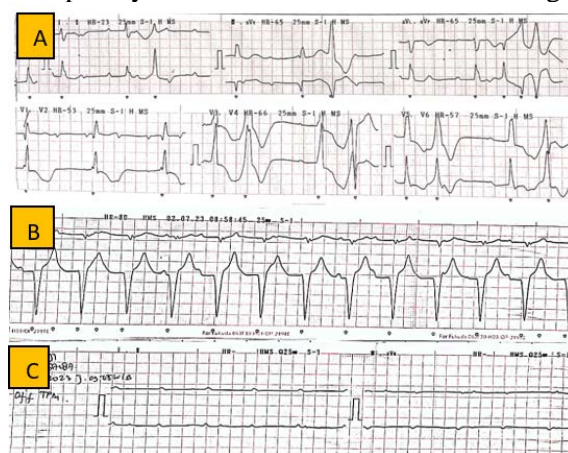


Figure: A. TAVB with bigeminy ventricular premature contraction; B. ECG indicates right ventricular stimulation of temporary pacemaker; C. ECG indicates standstill during off TPM



The Modified Valsava Maneuver for the Treatment of Supraventricular Tachycardia, Is It Really Effective?

N. A. A. Pratama¹, W. A. Mufida¹, A. S. Santoso²

¹General Practitioner, SLG General Hospital, Kediri, Indonesia

²Cardiologist, SLG General Hospital, Kediri, Indonesia

Background: Supraventricular Tachycardia (SVT) is a cardiac emergency that requires prompt treatment to prevent morbidity and mortality. Its prevalence is estimated to be 2.25 in every 1,000 people in the general population. In the setting of SVT patients with stable hemodynamics, vagal maneuvers are highly recommended as a first-line treatment. However, the Modified Valsava Maneuver (MVM) has shown a much better success rate of sinus rhythm conversion at the first minute than Standard Valsava Maneuver (SVM) and Carotid Sinus Massage (CSM).

Case Illustration: A 43-year-old man came to our emergency department with a chief complaint of palpitations 30 minutes earlier. He also experienced nausea, chest discomfort, and diaphoresis. He was an active smoker and had a history of uncontrolled hypertension but no history of stroke or transient ischaemic attack. On physical examination, he was alert (BP 147/129 mmHg, HR 191-214 beats per minute), and there were no carotid bruits. His initial ECG showed a regular and narrow QRS complex and a heart rate of 213 beats per minute. A diagnosis of SVT with stable hemodynamics was made. CSM was performed twice. However, his heart rate remained at 199–217 beats per minute. Then MVM was performed, and his heart rhythm was converted to sinus at 71 beats per minute. The laboratory examinations were all within normal limits. He was sent to the intensive cardiovascular care unit for observation and further evaluation. After three days of hospitalization, he was discharged without any complaints.

Conclusion: MVM is effective for the treatment of hemodynamically stable SVT. General practitioners should know how to perform MVM correctly, especially those in primary health care and rural hospitals, to get better outcomes and an improved prognosis.

Keyword: Modified Valsava Maneuver (MVM), Supraventricular Tachycardia (SVT), Rural Hospitals.

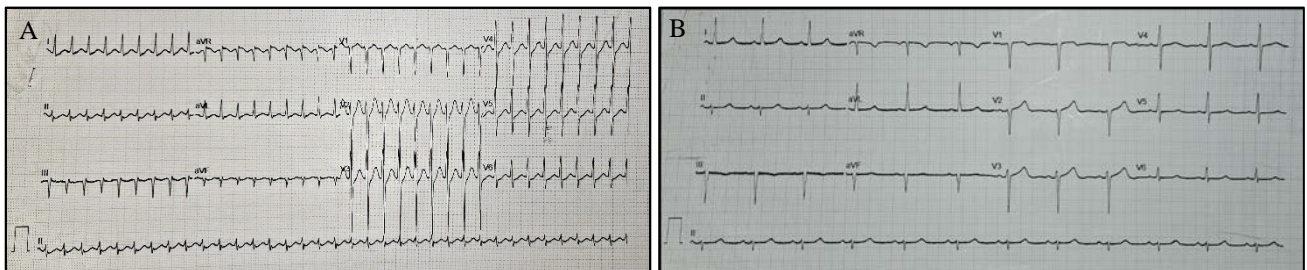


Figure 1. (A) Initial ECG upon arrival at Emergency Department. (B) ECG after termination of SVT with MVM.



Bradycardia in Grave's Disease: A Rare Case Report

N. K. Sumbung¹, M. Fahimi², T. Setiadi³,

¹General Practitioner, Cilandak Marine Hospital, Jakarta, Indonesia

²Internist, Department of Internal Medicine, Cilandak Marine Hospital, Jakarta, Indonesia

³Cardiologist, Department of Cardiology, Cilandak Marine Hospital, Jakarta, Indonesia

Background: Hyperthyroidism is a condition that highly affect the cardiovascular system. The increase of thyroid hormone has been seen to induce changes in both structure and function of the cardiac cells, which leads to electrical remodelling, causing tachyarrhythmia. However, in several reports, a rare occurrence of bradycardia has been described in patient with hyperthyroidism.

Case Illustration: This case depict a 30-years old male who presented with atypical chest pain, palpitation, and shortness of breath. The patient had been diagnosed with hyperthyroidism and paroxysmal atrial fibrillation 3 months prior the current onset of symptoms and underwent treatment using propylthiouracil and propranolol. The physical examination showed a typical appearance of impending thyroid storm secondary to Grave's disease with bradycardia (52 beats per minute). The electrocardiogram result confirmed the presence of sinus bradycardia. Laboratory result exhibited hypokalemia. The use of propranolol was then immediately stop, and the patient underwent treatment for the impending thyroid storm and hypokalemia. The electrocardiogram series during treatment showed the improvement of the heart rate. However, upon the hospital discharge, the final electrocardiogram still resulted in sinus bradycardia.

Conclusions: Despite its rarity, bradycardia is a condition that might occur in patient with hyperthyroidism. The use of drugs, particularly anti-hyperthyroid treatment is considered as one of the possible cause of bradycardia in hyperthyroidism. Furthermore, there is still no consensus on the treatment of bradycardia in hyperthyroidism, except on hyperthyroidism cases that exhibit a severe case of bradyarrhythmia and thus requiring the use of permanent pacemaker.

Keywords: bradycardia; hyperthyroidism; Grave's disease



Serial Case of Resynchronization Therapy with Left Bundle Branch Area Pacing in Complete LBBB and HFrEF patients

N. N. Shabrina¹, G. Karwiky², M. Iqbal², C. Achmad²

¹Cardiology Resident, Department of Cardiology and Vascular Medicine, Padjadjaran University, Bandung, Indonesia

²Electrophysiology and Arrhythmia Division, Department of Cardiology and Vascular Medicine, Padjadjaran University, Bandung, Indonesia

Background:

Electromechanical dyssynchrony of the ventricular contractions might potentially contribute to adverse remodeling, which can lead to reduction of left ventricular ejection fraction (LVEF). As an alternative to biventricular pacing (BVP), left bundle branch area pacing (LBBAP) is used to conduct cardiac resynchronization therapy.

Case Illustration: Case 1. A 67-year-old woman was admitted to our hospital due to near syncope. ECG showed left bundle branch block (QRS duration of 168 ms) with intermittent total degree AV block. Echocardiography examination revealed left ventricular end-diastolic diameter (LVEDd) of 62 mm and LVEF of 34%. LBBAP was performed. Paced QRS duration narrowed with LBBAP with QRSd of 114 ms.

Case 2. A 71-year-old woman presented with weakness admitted to hospital with incomplete LBBB (QRSd of 120 ms) and episode of high degree AV block 2:1. Echocardiography examination showed LVEDd of 53 mm and LVEF of 29%. LBBAP was chosen with an aim to restore synchronization. With LBBAP, the paced QRSd was reduced to 95ms.

Conclusion: LBBAP provided a great electrical and mechanical resynchronization in patients with left bundle branch block. In patients with LBBB, LBBAP has been shown to substantially shorten QRS duration and prevent the deterioration of cardiac function in HFrEF

Keywords: left bundle branch area pacing, heart failure, cardiac resynchronization therapy



Shocked! Inappropriate ICD shocks due to Lead Fracture in Type I Brugada Syndrome: A case report

N.S. Primaditta¹, Michael¹, R. Wahyuni¹, E. Mariska¹, R.S. Ayuningtyas¹, S. Hidayatullah¹, Haikal², A Harsoyo²

¹ General Practitioner, Gatot Subroto Central Army Hospital, Jakarta

² Cardiologist, Gatot Subroto Central Army Hospital, Jakarta

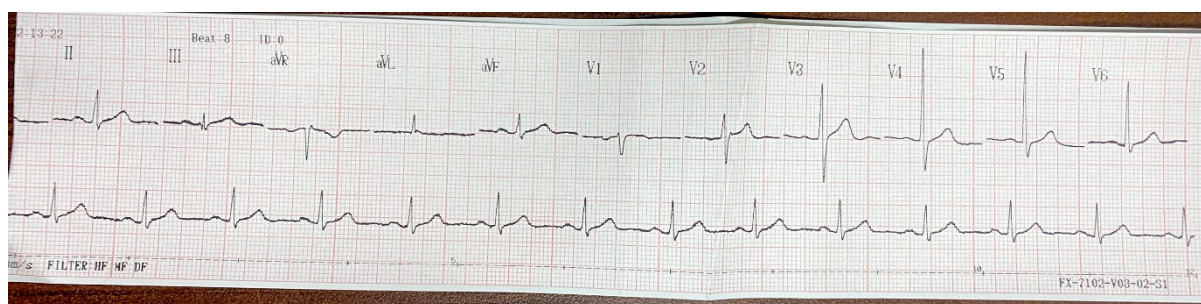
Background: Implantable Cardioverter Defibrillator (ICD) is recommended as primary prevention to prevent sudden cardiac death in Brugada Syndrome patients. However, studies had discovered that nearly a fifth of patients with ICDs reported inappropriate shocks (IS) over the course of time.

Case Illustration: A 70 year old man came for monthly follow up at the outpatient clinic with complaint of sporadic shocking sensations around his chest and left arms. The symptom began few weeks prior and felt after any type of movements on the upper body. He had history of syncope due to VT episodes and Brugada Syndrome Type 1, on which an ICD had been implanted 4 year ago for primary prevention. He was then scheduled to undergo extraction, followed with implantation of new ICD system through axillary approach. Lead measurement after implantation showed low R wave (2.5mv), high threshold (>7V), and high impedance (>3000 Ω) with both lead and generator in position. The lead was cleaned and reconnected to the generator, and yet still showed high impedance and low R wave. It was decided to add more screw in lead pin-generator connection in the septal apex. Re-evaluation of the lead showed good results. Following the procedure, the patient was released in good condition and showed up at his next follow up without any complaint.

Several etiologies such as oversensing, supraventricular tachycardia, and lead fracture had been known to contribute to the occurrence of IS. High lead impedance (>2500 ohm) during device interrogation also warrants the suspicion of lead fracture, rather than connection problem according to Swerdlow et al. Previous reports revealed that IS has a higher prevalence in patients with Brugada Syndrome, of up to 20 to 31% during a 2-years follow up. Brugada Type 1 was associated with appropriate shock delivery, while the presence of other arrhythmia was predictive of IS.

Conclusion: Lead fracture represents a possible device-related complication in a chronic settings, that manifested as IS regardless of rhythm. Routine follow up, device monitoring, and patient awareness are key to manage this complication the earliest.

Keywords : pacemaker, brugada type 1, inappropriate shock, ICD, arrhythmia



Gambar 1. EKG



Simultaneous conduction disturbance of an atrioventricular nodal pathway after a mitral valve replacement: A case report

O. S. Hasan^{1,2}, M. Amir^{1,2}, J. Kusumanegara^{1,2}

¹Faculty of Medicine, University of Hasanuddin, Makassar, Indonesia; ²RSUP Dr. Wahidin Sudirohusodo, Makassar, Indonesia

Background: Atrioventricular Node Reentrant Tachycardia (AVNRT) is most common cause of regular narrow QRS tachycardia. The type “slow-fast” reentry circuit is found in 90% of patient with AVNRT. Ablation of the slow pathway is a simple procedure used to cure AVNRT. Although postsurgical atrioventricular (AV) block is a well-known complication of cardiac surgery, a simultaneous conduction disturbance of an AV nodal is not common, especially when concomitant with thyroid disorder.

Case illustration: We reported a 49 year old male patient came to Emergency Room with palpitations since one week ago, worsening within 2 hours. One week ago, the ECG shown atrial fibrillation rapid ventricular response and treated with medication. Three weeks before admission, the patient underwent mitral valve replacement surgery with mechanical prosthetic. The patient also had history of uncontrolled hyperthyroid. Upon admission, the HR was 150 bpm with narrow QRS complex on monitor, then surface ECG shown typical atrioventricular nodal reentrant tachycardia. The tachycardia was refractory to stimulation of vagal manuevres (carotid sinus massage), then antiarrhythmic agent was admitted. Electrophysiology study and ablation were performed with successful result.

Conclusion: Postsurgical arrhythmia presenting as supraventricular tachycardia is sometimes varied. Dramatic concomitant other co-morbid such as hyperthyroid leads this case to be more challenging. With prompt recognition and ablation, those are important things to do with optimal management strategy.

Keywords: AVNRT, hyperthyroid, mitral valve replacement.

Origin Site Discrepancy Between Electrocardiogram (ECG) and Cardiac Magnetic Resonance (CMR) in Arrhythmogenic Right Ventricular Cardiomyopathy (ARVC) Patients: Ablate or ICD?

P. A. Trisnasari, E. Maharani, F. Hidayati

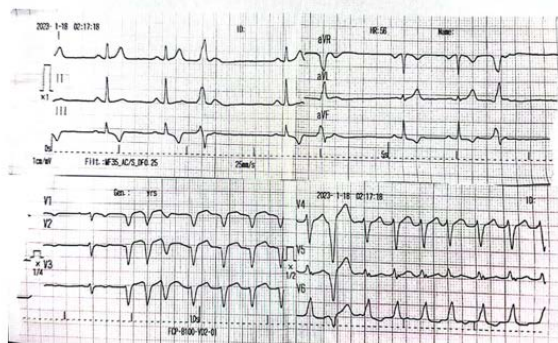
Faculty of Medicine, Universitas Gadjah Mada, Yogyakarta, Indonesia

Background: Arrhythmogenic right ventricular cardiomyopathy (ARVC) is rare inherited disease characterized by progressive fibrofatty replacement of the right ventricular myocardium that lead to ventricular tachycardia (VT) and sudden cardiac death (SCD). As the primary prevention of SCD and recurrent VT, intracardiac defibrillator (ICD) is highly desirable, but currently catheter ablation become an emerging issue as one of therapeutic options. Padua score used as new diagnostic criteria to diagnose ARVC, but there was no clear statement about what choice do we have to treat patient with discrepancy of ARVC origin site between ECG and CMR.

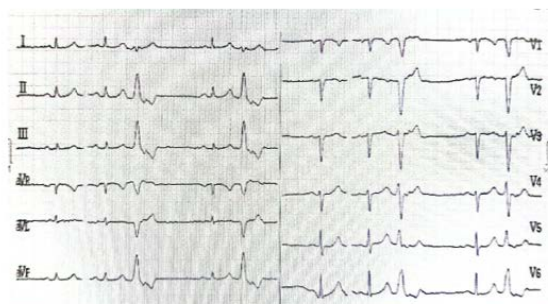
Case Illustration: First case, a 26 year-old male with chief complaint was palpitations and history of unstable ventricular tachycardia event. He had PVC with LBBB morphology, inferior axis, R in AVL, and transitional zone in >V4 that maybe from free wall or septal origin site. Echocardiogram showed positive criteria for ARVC with bulging at mid septal RV. CMR result was positive for RV bulging at basal free wall and mid wall fibrosis at mid septal. Second case, a 64 year-old male with the same complaint with no history of VT. The ECG was PVC with LBBB morphology, inferior axis, negative in I, transitional zone in ≥ V3 that maybe from anterior RVOT. Echocardiogram showed no sign of ARVC. The CMR result support major criteria of ARVD with fibrosis and RV bulging at apical RV. Both patients are suitable for ICD implantation. First patient was refused to ICD implantation. Instead of ICD, the second patient had ablation and no VT or recurrent symptom appear until today.

Conclusions: Treatment option in Arrhythmogenic right ventricular cardiomyopathy still become a dilemma. Future works are needed to elucidate the role of ICD and catheter ablation.

Keywords: Arrhythmogenic right ventricular cardiomyopathy, ARVC, ICD, Catheter ablation



First case ECG



Second case ECG



Misleading Causality Between Complete Heart Block and Acute Kidney Injury: Rarely, It's Other Way Round

L. P., Elias M., Untu B., Setiadi B.M.

Department of Cardiology and Vascular Medicine, Faculty of Medicine, Sam Ratulangi University,
Manado

Background: Complete heart block is a life-threatening condition in which at some cases explained as manifestation of acute kidney injury (AKI), whereas the reports of contrariwise case are very limited. We report a case of AKI due to a complete heart block which was never diagnosed before.

Case Presentation: A 67-years old man presented in emergency ward with dizziness for two weeks. Electrocardiography showed complete heart block with ventricular rate 26 bpm. He was then proceeded for urgent temporary pacemaker (TPM) insertion. Creatinine level was 5.1 mg/dL and potassium 7.2 mEq/L though the patient has no history of renal disease with baseline creatinine level 1.3 mg/dL. After TPM insertion the creatinine level decreased to 1.7 mg/dL and potassium to 5.0 mEq/L. Electrophysiology study was performed several days after in which 440 ms incremental atrial pacing showed prolonged HV intervals, confirming the block site is on the infra-Hissian area. The patient was planned for permanent pacemaker. Arrhythmia may reduce cardiac output temporarily, thereby attenuating kidney perfusion once renal autoregulation fails. Complete heart block is a life-threatening condition and acute kidney injury (AKI) which is usually caused by renal hypo-perfusion is associated with adverse outcomes. Patients with AKI resulted from complete heart block are likely to recover once pacemaker was implanted.

Conclusion: Acute kidney injury (AKI) induced by complete heart block is a rare condition and sometimes the general comprehension between AKI and complete heart block causality might lead to a mistreatment. The renal injury could recover after the pacemaker implantation.

Keywords: acute kidney injury, complete heart block, pacemaker implantation



Why It is Important to Recognise Symptomatic Brugada ECG Pattern (BrS): A Case Report in Young Woman

P.N. Permatasari¹, I. Handirosiyanto²

¹General Practitioner, Baptis Batu Hospital, Malang, Indonesia

²Cardiologist, Baptis Batu Hospital, Malang, Indonesia

Background: Brugada Syndrome (BrS) is a rare condition caused by a mutation in sodium channel genes. The most severe clinical symptom is sudden cardiac death (SCD) due to VT/VF. Predominantly men have 5.5 times the risk of SCD than women. The mean age is 41 years old. First-line therapy for BrS is Implantable Cardioverter-Defibrillator (ICD). This case report showed SCD in 29 years old young woman caused by type 1 BrS.

Case Illustration: A 29-year-old woman with general weakness, nausea, and vomiting came by ambulance to Emergency Department (ED) after recreation in Batu Secret Zoo. She had asthma and no family history of CAD. BP:130/80 mmHg, HR:84 x/minute, SaO₂:95%. No rhonchi or wheezing, and no abnormality of the heart sound. She was diagnosed with dyspepsia syndrome. When observed in ED, suddenly, she had a general seizure and cardiac arrest. After resuscitation, the ECG demonstrated a coved-type of ST-segment elevation in V1-2. This ECG was compatible with type 1 BrS. After a few days in ICU with maximum support; ventilator, inotropic, vasoconstrictor, and other supporting drugs, she did not respond to sound or pain, and her eyes did not respond to light and dilated pupils. She had a brain stem death. After re-anamnesis with the family, she had a family history of SCD. The patient had inherited abnormal genetic; sodium channelopathy. Nausea and vomitus made imbalance electrolyte induced VT/VF. The ECG when she had a seizure could not be monitored. It could be VT/VF. There were abnormal laboratory findings; metabolic acidosis, hypocalcemia, hyperglycemia, leucocytosis, increase serum transaminase and increase creatinine serum. She was diagnosed with post-cardiac arrest, type 1 BrS, shock condition, septic condition, ARDS, and MODS.

Conclusion: BrS is a rare condition because of sodium channelopathy. Awareness and prompt recognition of Brugada ECG pattern in symptomatic patients are needed because of high incident SCD such as in this case.

Keywords: *Brugada Syndrome, ECG, SCD, young woman.*

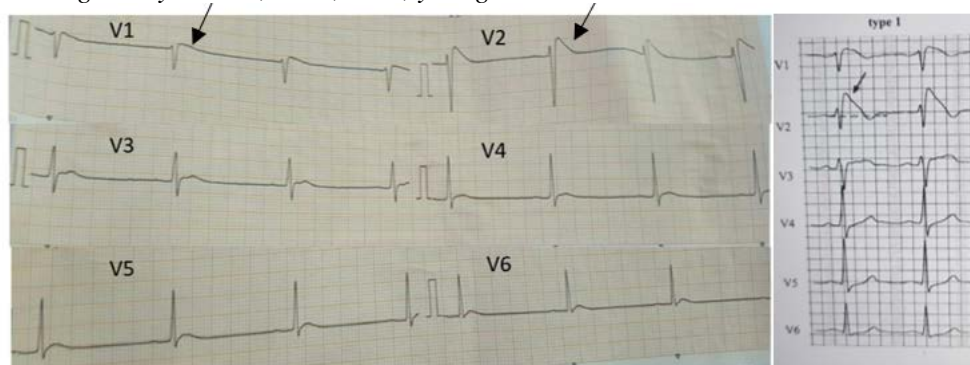


Figure 1: ECG post-ROSC in ED; type 1 BrS.



**Syncope patient, should PPM be implanted? a Case report of Sinus Arrest with Junctional
Escape**

N.F Hanifah¹, P. Wulandari², D. Ariyanti², Suryono², A.S Maulana²

¹ Faculty of Medicine, Universitas Jember; ² RSD dr Soebandi Jember

Background: Sick sinus syndrome (SSS), also known as sinus node dysfunction, is a group of syndromes with a disturbance in the spur and efferent functions of the sinoatrial node (SAN). This disorder causes abnormalities in the formation of impulses in the sinus node, which results in the onset of chronic arrhythmias and causes the blood supply to be unable to adequately perfuse the heart, brain, kidneys, and other organs. Clinical symptoms in SSS patients will gradually worsen from mild fatigue, insomnia, memory loss, and transient vertigo to syncope. Cerebral hypoperfusion is the most common manifestation and about 50 percent of patients with SSS experience fainting or syncope.

Case Illustration: In this case report, a 57-year-old man complained of fainting several times after work. He also feel weakness, chest pounding and dizziness. At the referrer hospital, ECG examination showed the presence of 1st degree AV Block but at the emergency room of the referral hospital we found sinus rhythm ECG. The following day, the results of the ECG examination showed sinus arrest with a junctional rhythm. Based on the indication of clinical symptoms and electrocardiographic analysis, we implanted Permanent Pace Maker (PPM) as definitive management.

Conclusion: This case report concluded that patient with Sick Sinus Syndrome (SSS), which established based on clinical symptoms of the patient and an electrocardiogram examination was successfully treated with PPM.

Keywords: Sick sinus syndrome, Sinus Arrest, fainting, Permanent Pace Maker (PPM)

Orthodromic atrioventricular reciprocating tachycardia and periodic sinus arrest as manifestation of acute digitalis toxicity: a case report

R.A.Nugraha¹, B.P.D.Khrisna¹, T.S.Putra¹, M.R.Amadis², R.Julario², B.B.Dharmadjati²,
Y.H.Oktaviono³

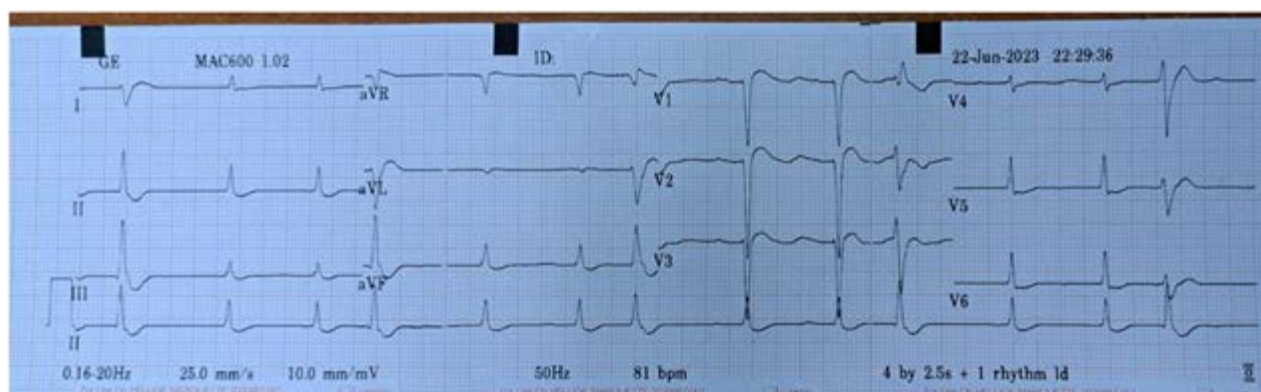
¹ Department of Cardiology and Vascular Medicine, Faculty of Medicine, Universitas Airlangga, Surabaya, Indonesia; ² Division of Arrhythmia and Electrophysiology, Department of Cardiology and Vascular Medicine, Dr. Soetomo General Hospital, Surabaya, Indonesia; ³ Division of Interventional Cardiology, Department of Cardiology and Vascular Medicine, Dr. Soetomo General Hospital, Surabaya, Indonesia

Background: Digoxin is one of the oldest cardiovascular drugs for heart failure. Since the publication of the DIG trial in 1997, digoxin use has declined significantly. However, digoxin is still currently prescribed to hundreds of thousands of people in Indonesia. Poisoning with digoxin can occur with acute over-ingestion of medication and exacerbated with decreased of renal clearance, especially in the older patient.

Case Illustration: We present a case of acute digitalis toxicity precipitated by self-medication in 73 years old retired physician who presented to our hospital with alleged history of consumption of 2 mg of digoxin tablets due to his palpitation. Upon admission, his BP was 170/64, HR 40 bpm. Echocardiogram revealed severe aortic stenosis, moderate mitral regurgitation (restricted PML), and mildly reduced ejection fraction (EF 42%). Laboratory examination revealed anemia (Hb 7.4) hypokalemia (potassium 3.2), hypoalbumin (2,8) and elevated serum creatinine (2.6; eGFR 25ml/min/1.72m²). His first ECG showed periodic sinus arrest and ECG 1 hour later was orthodromic atrioventricular reciprocating tachycardia.

Conclusion: While digoxin is prescribed less commonly, physicians need to maintain a high index of suspicion of digitalis toxicity. In case of digitalis toxicity, it is important to distinguish each electrocardiogram characteristic, such as orthodromic atrioventricular reciprocating tachycardia which mimics bidirectional ventricular tachycardia in the setting of digitalis toxicity.

Keywords: *digitalis toxicity, orthodromic atrioventricular reciprocating tachycardia, sinus arrest*





Intermittent Wolff-Parkinson White Syndrome (WPWs): Hide and Seek

R. Fernandes¹, AA Lukito¹, S Chandra¹, H Hutabarat¹

¹Department of Cardiology Faculty of Medicine Pelita Harapan University, Siloam Hospital Lippo Village, Tangerang, Indonesia

Background: WPWs is an uncommon multifaceted disorder that ranges from asymptomatic to a potentially lethal arrhythmias. WPWs is classically described as a shortened PR intervals <120 milliseconds, a widened QRS >110 milliseconds and a delta wave. However, these classical findings might be veiled in the case of intermittent WPWs. Several subtypes of SVT such as orthodromic AVRT which accounts up to 95% of reentrant tachycardias in WPWs; and an antidromic AVRT which accounts 5% in WPWs cases could puzzled clinician leading to an undiagnosis or misdiagnosis. Thus its incidence might be underreported. Several modalities such as serial ECGs and 3-days holter monitoring in a post tachyarrhythmias event should be considered to ensure the suspicion toward disguised intermittent pre-excitation syndrome.

Case Illustration: A 54 years-old active lifestyle women without any comorbidities was referred to our emergency department with an unresolved palpitation, and chest discomfort after an oral beta-blocker and amiodarone administration, which then resolved after amiodarone infusion. Physical examinations revealed BP of 97/58 mmHg, HR 61 bpm. ECG in the other hospital revealed SVT, 164 bpm and SB post amiodarone infusion. On admission in our hospital, ECG revealed SR, 61 bpm. No remarkable findings in the laboratory results, and chest x-ray, unless a borderline LA enlargement in echocardiography. Continues noradrenaline infusion was given to maintain the BP, and a 3-days holter monitoring was planned. The patient was then transferred to the HCU for further investigation. Subsequently, an intermittent WPWs was found during daily ECGs and an unremarkable 3-days holter monitoring. Eventually the diagnosis of intermittent WPWs was confirmed without any medication prescribed, and an electrophysiology study was planned.

Conclusion: A thorough examination and a suspicion for intermittent pre-excitation after an episode of tachyarrhythmia should always be considered to prevent a further adverse effects. Referral to electrophysiologist cardiology is essential in such cases.

Keywords: Wolff-Parkinson White Syndrome (WPWs), Intermittent WPWs, SVT, Tachyarrhythmia

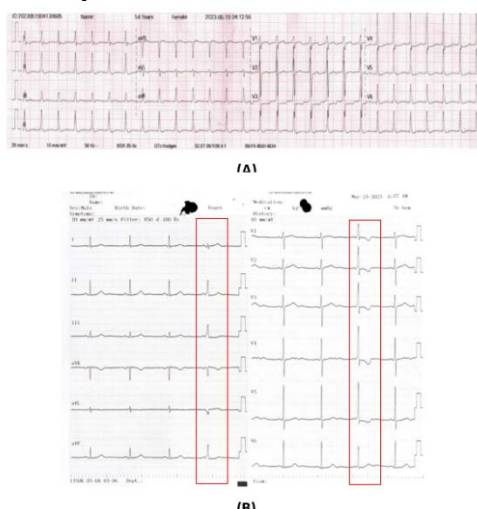


Figure 1. (A) ECG showing SVT, 164 bpm (In other hospital); (B) ECG showing an Intermittent WPWs (During Inpatient)



Conduction Abnormality in Acute Myocardial Infarction: Addressing a Diagnostic Challenge in The Field of General Practitioner

R.A.S. Wiharja¹, H. Isnaniyah²

¹General Practitioner, Pasar Rebo Regional Hospital, Jakarta, Indonesia

²Cardiologist, Pasar Rebo Regional Hospital, Jakarta, Indonesia

Background : Conduction abnormalities, such as the left bundle branch block (LBBB), sometimes found in patients with chest pain of acute coronary syndrome (ACS). The challenge to establish the correct diagnosis can be overcome by guided anamnesis, a proper and careful interpretation of ECG, and biomarker test. General practitioner (GP) needs to be able to determine an acute coronary syndrome based on ECG, especially one that does not show changes in a typical ST-T wave. In present case, a patient of ACS with LBBB who was negative any Modified Sgarbossa criteria, but later had confirmed of myocardial infarction (MI).

Case Illustration: A 70-year-old male patient with diabetic comorbidity reported a complaint of unexplainable suffocating chest pain accompanied by diaphoresis, preceded by epigastric pain and nausea with an onset of 10 hours. His history of cardiac or lung disease were denied. The vitals were stable and the cardiovascular system examination was unremarkable. A ECG showed sinus tachycardia at 126 bpm and incomplete LBBB but did not meet the modified Sgarbossa criteria for a myocardial infarction. However, Serum troponin I was strongly elevated at >10.0 ng/mL which indicate of acute myocardial injury. The patient was given initial therapy in the Emergency Room in the form of oxygenation, sublingual ISDN, loading dose of Aspilet and Clopidogrel, also administered Fondaparinux as an anticoagulant therapy for 3 days.

Conclusion: Conduction abnormality, such as LBBB, complicates ECG interpretations in the diagnosis of acute MI because of repolarization abnormalities hiding ST segment changes consistent with myocardial ischemia. This patient was treated appropriately with the diagnosis of acute MI, confirmed with highly elevated serum Troponin I as a biomarker myocardial injury. This case is a reminder that high index of suspicion for atypical clinical presentations and good clinical judgement as GP in emergency room should never replace any diagnostic algorithm.

Keywords: Left Bundle Branch Block, Acute Myocardial Infarction, Modified Sgarbossa Criteria.

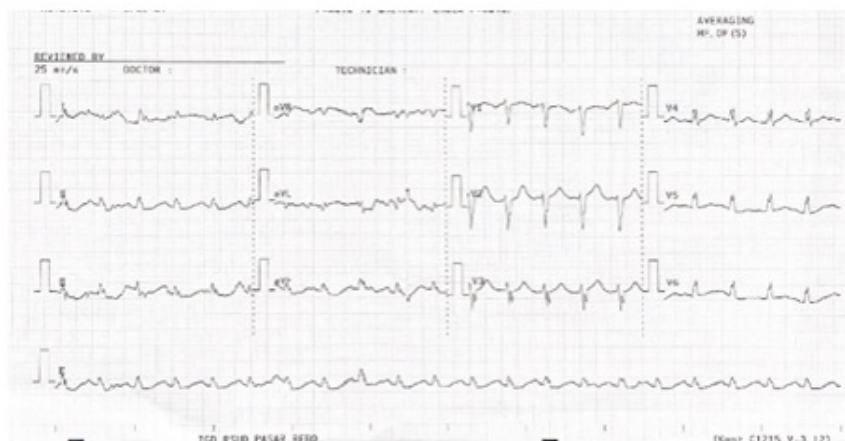

Figure 1. A 12-lead electrocardiogram (ECG) of the patient



IDENTIFYING AND DIFFERENTIATING IDIOPATHIC RIGHT AND LEFT-SIDED OUTFLOW TRACT VENTRICULAR ARRHYTHMIAS: CASE SERIES

R. B. Wicaksono¹, R. A. Nugraha¹, R. Julario², B. B. Dharmadjati²

¹ Department of Cardiology and Vascular Medicine, Faculty of Medicine Universitas Airlangga – Dr. Soetomo General Academic Hospital

² Division of Arrhythmia and Electrophysiology, Department of Cardiology and Vascular Medicine, Faculty of Medicine Universitas Airlangga – Dr. Soetomo General Academic Hospital

Background: Idiopathic ventricular tachycardia is a ventricular arrhythmia that occurs in the absence of structural heart disease and most commonly originates from the ventricular outflow tract. Due to the focal nature of the tachycardia, outflow tract ventricular arrhythmia is often treated by radiofrequency ablation if medical therapy is ineffective or not desired.

Case Illustration: We report 2 cases of 46 y.o. and 30 y.o females with palpitation and diagnosed with frequent premature ventricular contraction (PVC). Surface ECG suggestive that both patients have a different origin of PVC, one from the right ventricular outflow tract and another from the left ventricular outflow tract. A bigeminy PVC was found with an LBBB-shaped PVC morphology in patient A's case. In this case, the PVC precordial transition is located at V4. We calculated the R wave duration index and R/S wave amplitude (values <0.5 and <0.3) and QRS PVC duration divided by QRS sinus rhythm (value <1.9), which shows the Septal area of the RVOT. In the case of patient B, multiple PVCs were found with PVC morphology in the form of LBBB, but the transition zone in patient B occurred before V3, which supports the PVC source originating from the aortic valve. The precordial transition occurs in lead V3 and probably originates from the RCC. The 3D mapping results support the PVC source from the aortic valve, namely RCC. Three dimensions of intracardiac mapping support the origin of the PVCs are from the RVOT and LVOT, and radiofrequency ablation successfully decreased the frequency of PVC.

Conclusion: Determining the etiology and location of the ventricular outflow tract arrhythmia can improve the efficacy of ablation. Using the electrocardiography catheter ablation algorithm, left-sided and right-sided ventricular outflow tract arrhythmias can be accurately identified.

Keywords: ventricular arrhythmia, outflow tract, radiofrequency ablation

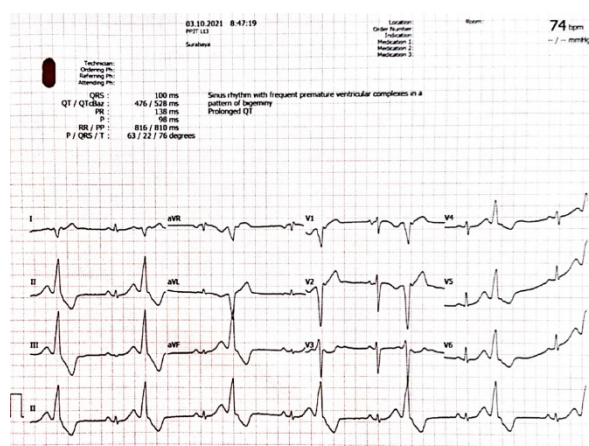


Figure 1 - Surface electrocardiogram for patient A



**THE OLDEST ANTIARRHYTHMIC DRUG AS AN ALTERNATIVE STRATEGY FOR THE
MANAGEMENT OF ELECTRICAL STORM IN LIMITED RESOURCES SETTINGS:
THREE CASES SERIES**

R.D. Karmia¹, H.E. Rasyid²

¹ Resident of Cardiology and Vascular Department, M. Djamil Padang Hospital, Faculty of Medicine,
Universitas Andalas, Padang, Indonesia

² Electrophysiologist of Cardiology and Vascular Department, M. Djamil Padang Hospital, Padang,
Indonesia

Background: Electrical storm (ES) is a medical emergency characterized by repetitive episodes of sustained ventricular arrhythmias (VAs) in a limited amount of time (at least 3 within a 24-h period). It is associated with increased mortality and requires urgent medical care, include 3D radio frequency ablation (RFA) and implantation of implantable cardioverter defibrillator (ICD) in addition to correcting the causes of VA itself. The evolving literature supporting the routine use of intravenous beta blockers and 3D RFA for acute management of ES that are not available in our hospital. So, in this case series, we discuss about the strategies for the management of acute ES in hospital with limitation of antiarrhythmic drugs (AAD) and supporting examinations.

Case Illustration: We describe three patients presenting with ES in various conditions: (1) a 50-year-old man with refractory sustained ventricular tachycardia (VT) that developed 2 days after primary percutaneous coronary intervention in ST-elevation myocardial infarction; (2) a 31-year-old man who developed refractory sustained monomorphic VT due to arrhythmogenic right ventricular cardiomyopathy (ARVC) with history of 3D RFA two times; and (3) a 27-year-old man who developed refractory monomorphic sustained VT without known underlying heart disease. The management that we can do for these patients include electrical cardioversion, intravenous amiodarone, lidocaine, and oral metoprolol, but ES still occurs. Finally, ES was converted to sinus rhythm by administering high dose of oral propranolol at 4x40mg, because the other AADs failed to eliminate the ES.

Conclusion: Propranolol, despite being one of the oldest AAD, sometimes may be effective as an alternative strategy for the ES treatment, especially in the limited resources settings.

Keywords: electrical storms, propranolol



**Performing Permanent Pacemaker Implantation Without Programming Device
During Pandemic Era, Is It Possible?**

R. Ermawan

Medical Faculty of Mataram University, West Nusa Tenggara, Indonesia

Background: Symptomatic brady-arrhythmia is a life-threatening condition that requires advanced treatment such as permanent pacemaker implantation. With an average of 15 procedures each year, there were quite a lot of permanent pacemaker implantations in West Nusa Tenggara. However as a rural area, West Nusa Tenggara had so many limitations in performing the procedure, which it did not have its own programming device. Usually, if the procedure were going to be performed, the programming device and the technician had to be brought in from capital cities like Jakarta or Surabaya. The situation became even more complicated when the climax of the Covid-19 pandemic forced the regional flights to stop operating, while life-threatening cases continued to arrive.

Case Illustration: Under the emergency situation, we were compelled to implant single-chamber permanent pacemaker without programming device in 4 patients with life-threatening total AV block. Instead, we used the generator of temporary pacemaker to guide the implantations, allowing us to measure the amplitude threshold and R wave values, and direct the placement of intravenous lead in the suitable high septum site. Those implantations were obviously not ideal due to the lack of width and impedance measurements that only could be carried out by using programming device. We relied on the default setting of the permanent pacemaker generator up to several months later. After the flight was recovered, we brought in the programming device to re-analyze and adjust the generator setting. So far, there had been no clinical problems in patients while waiting that moment.

Conclusion: Under the emergency situation, performing permanent pacemaker implantation without programming device is possible with several limitations.

Keywords: Permanent Pacemaker, Implantation, Without Programmer.



Second Degree Atrioventricular Block in an Accessory Pathway Related to Wolff-Parkinson-White Syndrome and Atrioventricular Node Dysfunction

R.I. Gunadi¹, R. Rizkiawan², R. Julario³

1,2 Faculty of Medicine, Universitas Airlangga, Surabaya, Indonesia; 3Soetomo General Hospital, Surabaya, Indonesia

Background: Syncope related to an accessory pathway and atrioventricular (AV) dysfunction is a rare condition. This condition is usually related to conduction capacity along the accessory pathway, which sometimes necessitates immediate ablation. Proper electrophysiology study (EPS) may contribute to determining the best management.

Case Illustration: A 64-year-old woman with a preexcited QRS consistent with Wolff-Parkinson-White (WPW) syndrome type A was hospitalized for syncope. Her electrocardiogram (ECG) monitoring also displayed a second-degree heart block with a fixed ratio of P waves: QRS complexes (2:1), which occurred inconsistently (Figure 1). An Electrophysiology Study (EPS) was indicated to identify her syncopal origin, and revealed a total blockage was found in the AV Node, with the conduction system being completely taken over by the accessory pathway. A permanent DDD pacemaker was implanted without accessory pathway ablation

Conclusion: In patients with syncope due to bradycardia with a delta wave on their ECG, practitioners must be alert that the causal may be originating from the AV node or accessory pathway. Hence, EPS has a crucial role in decision-making process to determine the appropriate management for these patients.

Keywords: atrioventricular block, accessory pathway, Wolff-Parkinson-White, syncope

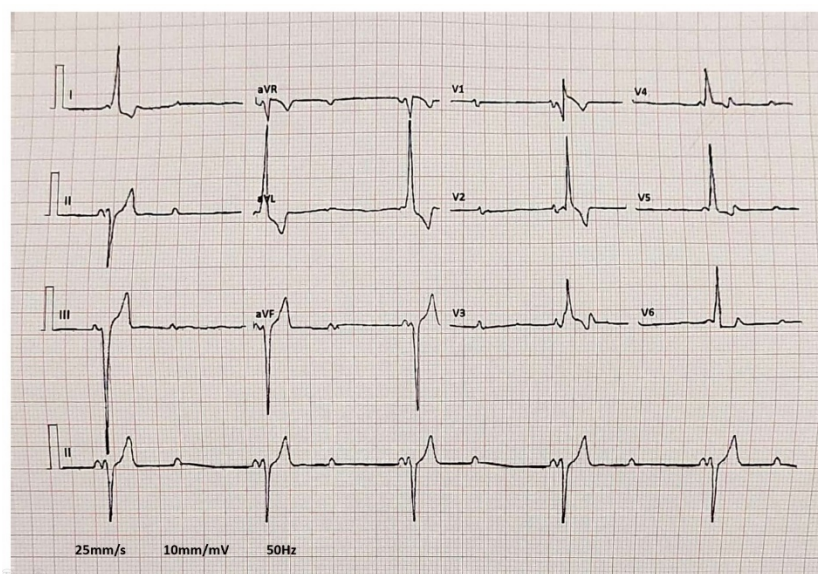


Figure 1. The ECG showed sinus rhythm with WPW type A and second-degree heart block with a fixed ratio of P waves: QRS complexes (2:1)

Atrial Fibrillation in Wolff-Parkinson-White Syndrome : How to deal with it in Rural Setting

R.M. Simangunsong¹, D.R.R. Saragih¹, M.I. Tuasikal²

¹ General Practitioner, Dr. Johannes Leimena Central General Hospital, Ambon, Indonesia

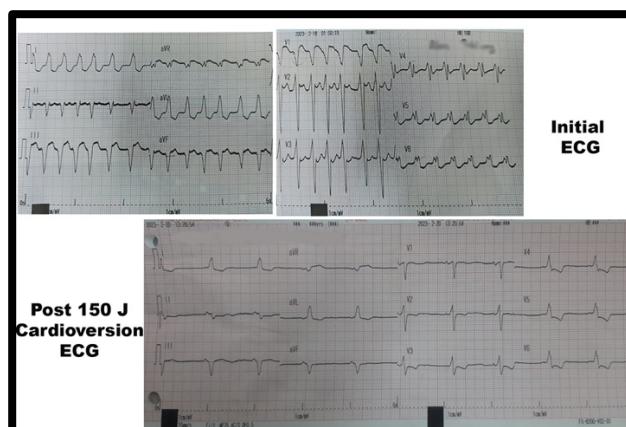
² Cardiologist, Dr. Johannes Leimena Central General Hospital, Ambon, Indonesia

Background : Wolff-Parkinson-White (WPW) syndrome first described in 1930 by Wolff, Parkinson and White, is a syndrome consist of short PR interval with bundle branch block on ECG findings and clinically manifested as paroxysmal tachycardia. Paroxysmal atrial fibrillation (PAF) develops in up to a third of patients with WPW syndrome. Once PAF occurs in a patient with WPW syndrome, it can be life-threatening when an extremely rapid ventricular response develops into ventricular fibrillation.

Case Illustration: We Report a case of 68 years old Male, admitted to Emergency Department with dyspnoe as a chief complaint. He also had severe palpitation since an hour before admission. He had no fever, nauseous or vomited. Examination in Emergency Departement revealed fully concious with Blood pressure 72/52 mmHg, heart rate 160-180 bpm irregular, Respiratory rate 28/min, SpO2 94% Room air. Heart Auscultation revealed irregular heart rate, with no murmur and gallop. Initial ECG showed Atrial Fibrillation with a rapid pre-excited ventricular response. We assesed the patient as an Unstable Atrial Fibrillation . We decided to give 150 J cardioversion with premedication. After cardioverison The ECG showed synus rythm with WPW posteroseptal rate 60/min, hemodinamically stable with dyspnoe and palpitation was reduced. The patient admitted to the Intensive Cardiovascular Care unit for observation. After 4 days hospitalization, the patient discharged with Propafenon 150 mg (if necessary), and referred for ablation.

Conclusion: Atrial Fibrillation in WPW syndrome can potentially evolve into ventricular fibrillation leading to cardiac arrest. The long term teraphy in this case is catheter ablation. In rural setting, providing the treatment to this patient was challenging due to many limitation. However, it can be handled first with electrical cardioversion.

Keyword: Atrial Fibrillation, Woff-Parkinson-White Syndrome, Rural Area



Inappropriate ICD Therapy Revealed in Cardiac Rehabilitation Programs

R.Muliawan¹, E.Maharani², F.Hidayati², I.A.Arso³, A.B.Hartopo³

¹Resident of Cardiology and Vascular Medicine, Sardjito General Hospital, Yogyakarta

²Arrhythmia Staff of Department of Cardiology and Vascular Medicine, Sardjito General Hospital Yogyakarta

³Cardiac Rehabilitation Staff of Department of Cardiology and Vascular Medicine, Sardjito General Hospital Yogyakarta

Background: Cardiac rehabilitation (CR) is a multidisciplinary intervention. The European Heart Rhythm Association (EHRA) reported in 2017 that 105.730 ICD implants were made across Europe. As a result, ICD is present in sizable fractions of patients taking part in CR programs. So, the proper settings are needed in this program.

Case Illustration: A 34-year-old basketball player and police officer had an ICD implanted due to sudden cardiac arrest with monomorphic ventricular tachycardia (VT) during a marathon. He was then referred to the cardiac rehabilitation department for comprehensive management. Initial assessment of the functional capacity of the heart using a 6-minute walk test showed high-risk classification. He then underwent endurance-type exercise programs, using repetitive movements using an ergo-cycle and treadmill with electrocardiography (ECG) monitoring. Initial heart rate (HR) target, HR peak, VO₂ peak, and HR reserve were set on light intensity exercise with maximum HR 160 bpm (10 bpm below the patient's ICD anti-tachycardia pacing (ATP) activation). After two training sessions and psychological support, the patient's confidence increased. Considering that he had good clinical presentation, training load was then increased. After a total of eight exercise sessions, evaluation using treadmill test (TMT) resulted in good fitness class (13 METs). However, the ICD ATP was active at HR 171 bpm, thus TMT was discontinued. The ICD interrogate yielded inappropriate ATP, so the ICD was reprogrammed by raising the HR limit to 176 bpm, prolong tachycardia detection zone to 40 intervals of the VT-1 zone and activating the VT ICD discrimination system by activating the stability interval, sudden onset (onset delta 100ms) and re-collecting wavelets to improve morphological criteria. Another eight practice sessions were continued, with the patient's functional capacity result from TMT examination being around 14.78 Mets. So that the patient can continue his career as a police officer and basketball player.

Conclusions: Cardiac rehabilitation of patients with ICD requires appropriate exercise prescription formulas, cross-disciplinary collaboration, and psychological support. It's not only to optimize medical treatment, exercise capacity, and clinical condition but also to supervise the correct functioning of the device.

Keywords: *cardiac rehabilitation, implantable cardioverter-defibrillator, anti-tachycardia pacing*

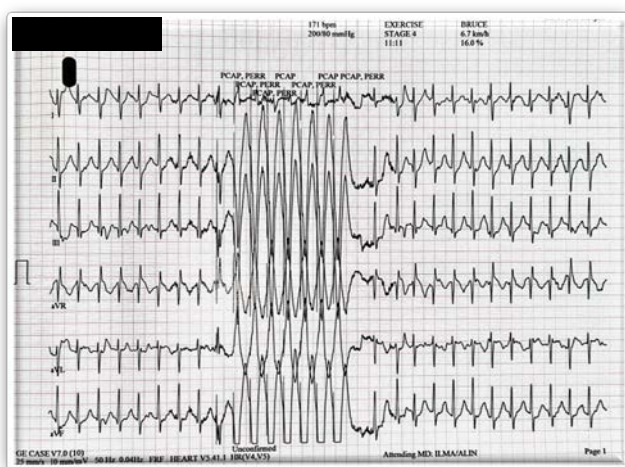


Figure 1. The patient TMT ECG showed ATP activation at a heart rate of 171 beats/minute



**Clinical Conundrum Case Series Congenital Atrioventricular Block (AVB) in Pregnancy:
Pacemaker or Conservative?**

R. Muliawan¹, E. Maharani², F. Hidayati², D. W. Anggrahini²

¹Resident of Cardiology and Vascular Medicine, Sardjito General Hospital, Yogyakarta

²Staff of Department of Cardiology and Vascular Medicine, Sardjito General Hospital Yogyakarta

Background: Complete or high-degree AVB during pregnancy is uncommon but can be a major issue. Permanent pacemaker implantation (PPM) is one of the main therapeutic options for patients with symptomatic bradycardia. However, employing fluoroscopy radiation during the implantation procedure itself can be harmful to the fetus.

Case Illustration: Case 1: A 25-year-old 35 weeks primigravida woman has had syncope in the past during physically demanding activities, but not this pregnancy. The holter ECG showed sinus rhythm with the lowest heart rate (HR) 31 beats per minute (bpm), average HR 65 bpm, narrow QRS complex, AVB 2:1 with conducted PR interval 320 ms and paroxysmal ventricular contraction (PVC) burden <1%. She had a normal ejection fraction and a nonconclusive atropine sulfates test. The zero-fluoroscopy electrophysiology study guided 3-dimensional mapping and cardiocography monitoring was performed. It shows A-H interval 279 ms, H-V interval 45 ms, and A not followed with H. Those concluded that the site of AV block was located at suprahisian. Hence, the implantation of a PPM decided to be postponed. Case 2: A 35-year-old 36 weeks multigravida woman with a history of syncope at 8 weeks of gestation. The holter ECG showed a sinus rhythm with the lowest HR 31 bpm, average HR 41 bpm, total AV block with a narrow QRS complex and PVC burden <1% with good ejection fraction function. She will be fitted with a PPM before delivery by placing an apron on the mother's back and abdomen. The intervention involves anesthesiologist for pain control and an obstetrician for fetal monitoring. Finally, the patient was implanted with a dual chamber pacemaker DDD mode. Both patients eventually gave birth with satisfactory maternal and fetal circumstances.

Conclusions: Determining the appropriate justification for PPM implantation during pregnancy is crucial for mother's and fetus's safety.

Keywords: *atrioventricular block, pregnancy, pacemaker*

Challenging Diagnosis of Supraventricular Tachycardia in Elderly Patient: Unmasking the Enigma of Horizontal ST Depressions

R. R. Eri¹

¹General Practitioner, Bagas Waras General Public Hospital, Klaten, Central Java, Indonesia

Background: Supraventricular tachycardia (SVT) comprises a group of arrhythmias with rapid, regular heart rates originating above the ventricles. The differential diagnosis includes atrial fibrillation, atrial flutter, atrioventricular nodal reentry tachycardia (AVNRT), atrioventricular reentry tachycardia (AVRT), and sinus tachycardia, presenting with overlapping features. Diagnosing SVT in elderly patients poses challenges, particularly with language barriers and limited history-taking. Upsloping ST depression, instead of horizontal ST depression, is often observed in SVT cases, further complicating the interpretation of electrocardiography (ECG) findings.

Case Illustration: An 81-year-old with a history of congestive heart failure and atrial fibrillation presented with 7-day chest pain, dyspnea, and a heart rate of 160 bpm. The initial ECG suggested possible AVNRT with subendocardial ischemia, featuring narrow QRS complexes, irregular P wave visibility, incomplete left bundle branch block (LBBB), and horizontal ST depression in leads I, aVL, V5, and V6. Elevated troponin-I levels of 4.6 ng/mL were also detected. The patient received aspirin, clopidogrel, nitrate, and digoxin. Subsequently, the ECG showed a heart rate of 80 bpm, irregular R-R intervals, barely visible P waves, incomplete LBBB, and remarkable resolution of the ST depressions. In this case, the differential diagnosis of SVT became more complex due to the patient's history of congestive heart failure, atrial fibrillation, slightly elevated troponin-I levels, and challenges posed by language barriers and limited history-taking. The presence of rarely seen horizontal ST depression raised concerns of subendocardial ischemia. However, the notable resolution of ST depression after digoxin administration suggests that the initial ST depression may have primarily resulted from the rapid heart rate associated with SVT, rather than indicating subendocardial ischemia. Furthermore, in the local language of Central Java, people commonly use the term "dada ampeg" to describe various cardiac symptoms, such as chest pain, dyspnea, or palpitations. This cultural aspect further complicates the differentiation of specific symptoms in this particular case.

Conclusion: This case report highlights the complexities involved in diagnosing SVT in elderly patients, particularly when language barriers and cultural nuances impact the diagnostic process. A comprehensive approach integrating clinical findings, ECG changes, elevated biomarkers, and cultural awareness is crucial for an accurate diagnosis and guiding appropriate treatment strategies.

Keywords: Supraventricular tachycardia, subendocardial ischemia, elderly patient

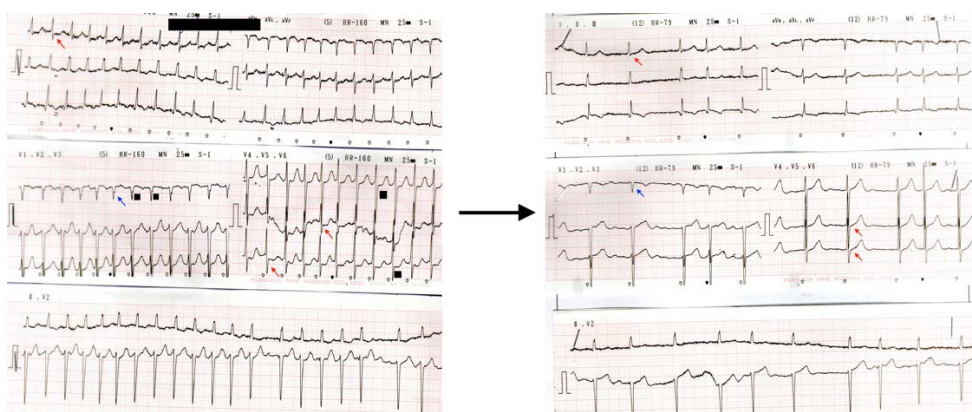


Figure 1. Serial ECG.



**Oral Aminophylline for Complete Heart Block in Inferior ST-Elevation Myocardial Infarction:
A Case Series of Emergency Management**

R. R. Eri¹, F. S. A. Pradana², S. Zahrani³

¹General Practitioner, Bagas Waras General Public Hospital, Klaten, Central Java, Indonesia

²Cardiologist, Bagas Waras General Public Hospital, Klaten, Central Java, Indonesia

³Medical Student, Faculty of Medicine, University of Indonesia

Background: Inferior ST-elevation myocardial infarction (STEMI) can result in complete heart block, necessitating urgent intervention to enhance perfusion. Aminophylline, a bronchodilator utilized in lung conditions, exhibits potential in stimulating atrioventricular (AV) conduction. This case series examines the use of aminophylline as an emergency treatment for complete heart block in patients with inferior STEMI, particularly in settings where immediate transcutaneous pacing is not readily available.

Case Illustration: Two patients, a 61-year-old male and a 74-year-old male, presented with symptoms suggestive of inferior STEMI, including chest pain, dyspnea, nausea, syncope and headache. Electrocardiography revealed ST-segment elevation in leads II, III, aVF, along with unsynchronized P waves and QRS complexes indicative of complete heart block. Initial treatment with sulphas atropine yielded unsatisfactory results. Subsequently, both patients received 400 mg of aminophylline, resulting in a significant increase in heart rate (from 42 and 35 beats per minute to 88 and 82 beats per minute, respectively) and the complete heart block was reversed prior to their referral to the referred hospital. Both patients safely reached the referred hospital and received fibrinolytic therapy for reperfusion.

Aminophylline is primarily used as a beta-2 agonist in respiratory diseases. It releases theophylline into the bloodstream, which acts as an adenosine receptor antagonist. Although the precise mechanism of action is not fully understood, a clinical trial is currently underway at the National Institute of Cardiovascular Diseases in Pakistan. It is believed that aminophylline may stimulate the AV node to enhance the conduction of electrical signals from the atria to the ventricles. This, in turn, increases heart rate and aims to provide sufficient perfusion until further treatment can be administered.

Conclusion: In situations where immediate transcutaneous pacing is unavailable, aminophylline could be considered as an adjunctive treatment for complete heart block in inferior STEMI patients. Although aminophylline's primary indication does not specifically target AV block, its ability to modulate cardiac conduction warrants further research and clinical studies to establish its efficacy and safety in emergency settings.

Keywords: Aminophylline, complete heart block, ST-elevation myocardial infarction

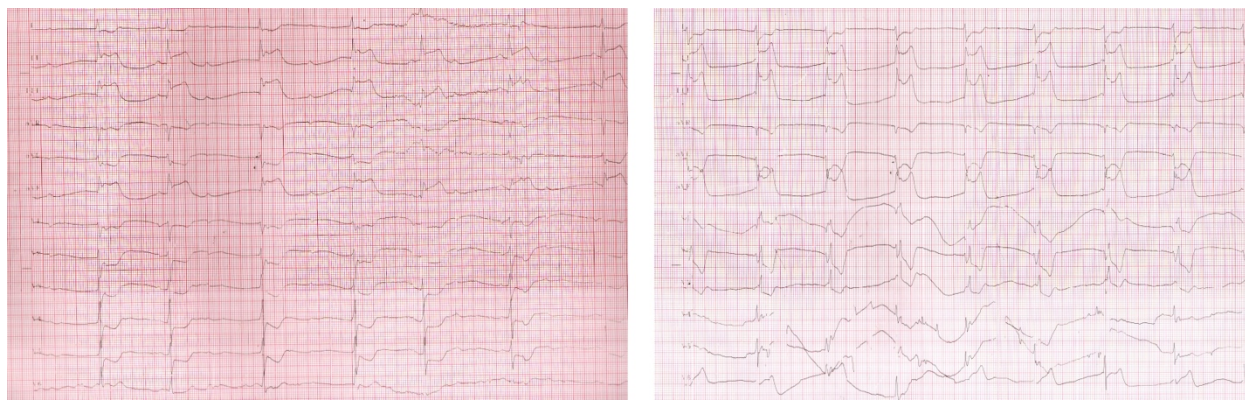


Figure 1. ECG of both patients, showing complete heart block

The Vicious Cycle of BRASH (Bradycardia, Renal Failure, Atrioventricular Nodal Blocker, Shock, and Hyperkalemia) Syndrome : Serial Challenging Case from General Practitioner in Emergency Room

R. Ramadhani¹, D.A. Ikeningrum²

1. Emergency Department, Kanjuruhan General Hospital, Malang, Indonesia
2. Cardiovascular Department, Kanjuruhan General Hospital, Malang, Indonesia

Background: BRASH (Bradycardia, Renal Failure, Atrioventricular Nodal Blocker, Shock, and Hyperkalemia) Syndrome is an emerging clinical entity caused by the synergistic effect between hyperkalemia and atrioventricular (AV) nodal blocker agent which induces vicious cycle of profound bradycardia and shock. If not managed adequately, it will progress into multiorgan dysfunction syndrome and elevates mortality risk for our patient. In this case report, we will deliver two cases of BRASH Syndrome in our emergency room.

Case Illustration: Case 1: 68-year-old woman came to emergency room with chief complaint of general weakness and shortness of breath. She had history of hypertension, diabetes, and renal failure with routine consumption of amlodipine, furosemide, spironolactone, and ramipril for 5 months. Physical examination revealed low blood pressure with poor peripheral perfusion, low heart rate, and infected wound on the right ankle. ECG showed junctional escape rhythm 32 beats per minute. Laboratory results showed elevated kalium, ureum, and creatinine. Hemodynamic stabilization was achieved with dual combination of inotropic and vasopressor agents, aggressive kalium correction with drugs combination and hemodialysis, also infection control with regular wound care and antibiotics. She recovered at first but due to worsening metabolic condition, she died several days later. **Case 2:** 48-year-old man came to emergency room with chief complaint of sudden decrease of consciousness and weakness due to excessive vomiting. He had history of acute hepatic and kidney injury with routine consumption of propranolol, furosemide, and spironolactone for 4 months. Physical examination revealed low blood pressure with poor peripheral perfusion also low heart rate. ECG showed severe sinus bradycardia with tall T wave 27 beats per minute. Laboratory results showed elevated kalium, ureum, and creatinine. Hemodynamic stabilization was achieved with adequate fluid therapy, combination of inotropic and vasopressor agents, also aggressive kalium correction with drugs combination and hemodialysis. Patient recovered, but he got discharged against our medical advice.

Conclusion: Emerging case of BRASH Syndrome should increase our clinician awareness because early detection with adequate therapy may improve patient's outcome. Addressing each patient's profile and precipitating factors is an important key to manage each case.

Keywords: BRASH Syndrome, Hyperkalemia, Renal Failure, AV Nodal Blocker

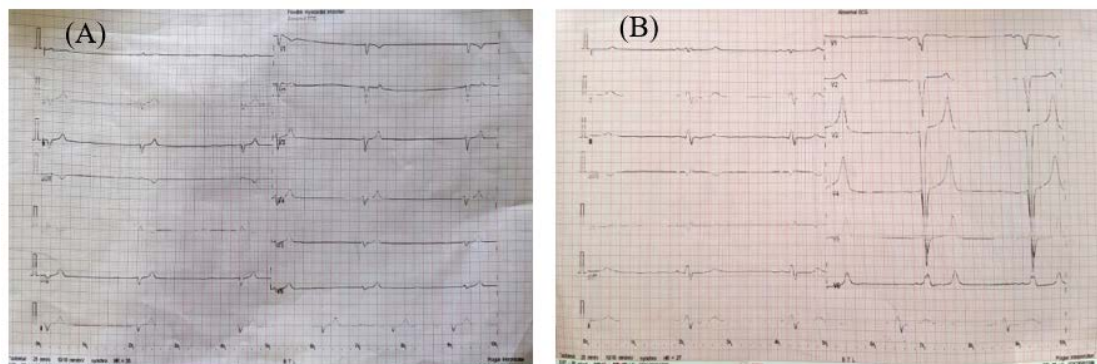


Figure 1. ECG (A) from case 1 showed junctional escape rhythm with rate 32 bpm while ECG (B) from case 2 showed sinus bradycardia with tall T wave rate 27 bpm

**WHEN THE INTERSECTION IS A BLINDSPOT: A 2D-ABLATION OF PARA-HISIAN
ACCESSORY PATHWAY FINDING CASE IN CHILD**

R. Rohmatussadeli¹, L. B. A. Praha¹, Y. Suryadilaga¹, A. Y. B. Mochtar¹, P. Ardhianto¹

¹Department of Cardiology and Vascular Medicine, Diponegoro University, Semarang, Indonesia

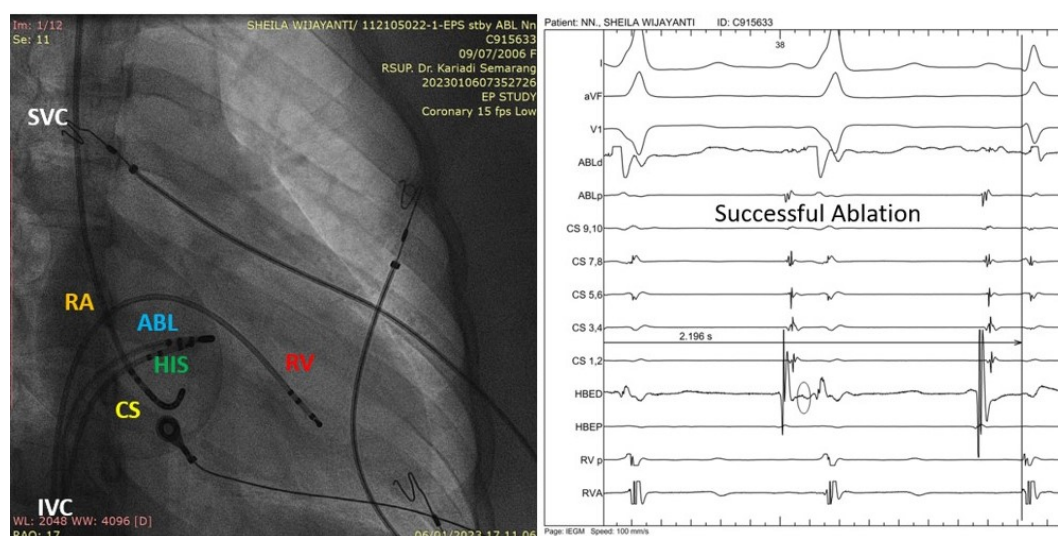
Background: Accessory pathway (AP) is indicate either a "tract" which bypasses the AV node but inserts into the specialized conduction can make a tachyarrhythmia, one of the interesting findings is the Para-Hisian finding case which we can predict by the ECG; positive delta waves at inferior leads and early transition of delta wave in the precordial lead. The case prevalence of Para-Hisian AP is about 7% from all cases of accessory pathways. The procedure of catheter ablation in Para-Hisian AP has a high risk of complications because of its location adjacent to the cardiac conduction system, and here we presenting a rare case of 2D ablation modality in Para-Hisian finding case in a child.

Case Illustration: A 16 years old female complaining of recurrent palpitations and syncope in the past 3 years. The ECG showed a positive delta wave at inferior leads and an early transition of delta wave in precordial leads, in which indicated an anteroseptal AP. The Holter monitoring revealed ventricular pre-excitation still manifest at faster heart rates. An electrophysiology study found Para-Hisian AP and its evidence of AP Potential near His catheter. During certain ablation trials, a junctional accelerated rhythm was discovered, leading to the suggestion that the ablation point was close proximity to the perinodal origin. Even though, non-complicated *Radiofrequency* ablation had done successfully from the inferior vena cava with normal energy output and shorter duration (*Figure 1*). Follow-up after a month, it was showing improvement in whether the ECG performed normal sinus rhythm and no episode of palpitation or syncope.

Conclusion: Radiofrequency ablation on WPW syndrome patient with Para-Hisian AP is a well-established, safe, and effective treatment in eliminating AP if performed with appropriate protocol and strategy, and regular follow-up patient to ensure the long-term effectiveness of the treatment is needed.

Keywords: Para-Hisian Accessory Pathway, 2D-Ablation, Child

Figure 1:





Implantable Cardioverter Defibrillator in J-Wave Syndromes - Balancing the Tightrope between Sudden Cardiac Death and Cost-Effective Intervention

R. Triasnawati¹, F. Hidayati², E. Maharani²,

¹Resident of Cardiology and Vascular Medicine, Sardjito General Hospital, Yogyakarta

²Staff of Department of Cardiology and Vascular Medicine, Sardjito General Hospital Yogyakarta

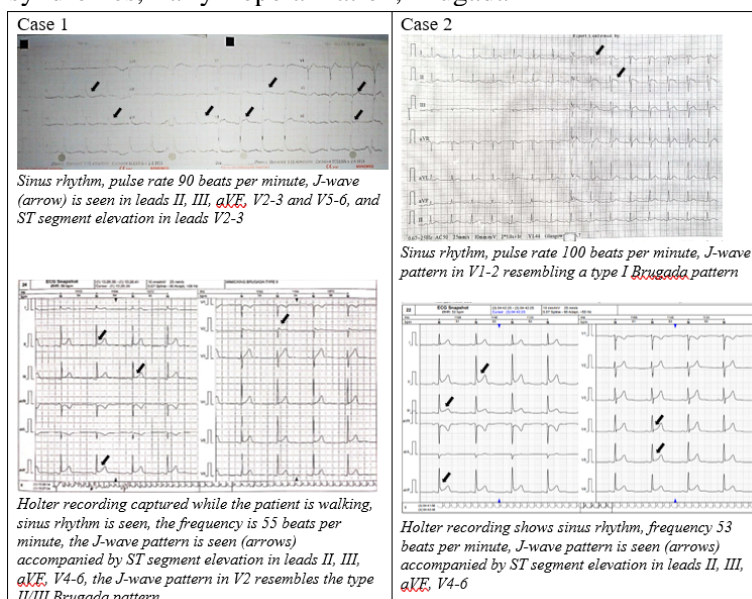
Background: The J-wave syndromes (JWSs), consisting of Brugada syndrome (BrS) and early repolarization syndrome (ERS). JWSs has evolved from a benign electrocardiographic (ECG) abnormality to a proarrhythmic state, becoming a significant cause of idiopathic ventricular fibrillation responsible for sudden cardiac death. J-waves are observed in inferior (II, III, aVF) or lateral (V4, V5, V6) leads, whereas in BrS, they are prominent in right precordial leads (V1-V3).

Case Illustration: Case 1: A 40-year-old male patient presented at the emergency room with cardiac arrest ventricular fibrillation (VF) mode. The patient had two events of fainting with convulsions at ages 30 and 39. No family history of similar complaints or related events. ECG showed J-waves in leads II, III, aVF, V2-3 and V5-6, as well as ST segment elevation in V2-3. Echocardiography showed functionally normal heart with left ventricular ejection fraction (LVEF) of 57% and mild mitral regurgitation (MR), not fulfilling ARVC criteria. Treadmill test result was no negative ischemic response and no arrhythmias. Holter recording captured J-wave pattern accompanied by ST-segment elevation in leads II, III, aVF, V4-6. The J-wave pattern in V2 resembles the Brugada type II/III pattern. Coronary MSCT results showed non-significant coronary artery disease (CAD) with calcification in the proximal part of the LAD. Patient received implantable cardioverter-defibrillator (ICD) considering cardiac arrest history with JWSs findings in ECG and Holter.

Case 2: A 34-year-old man hospitalized due to Dengue fever was presented with localized chest pain and palpitations. No family history of similar complaints or related events. Inpatient ECG captured Brugada type 1 pattern in V1. Holter recording captured J-wave pattern accompanied by ST-segment elevation in leads II, III, aVF, V4-6. Echocardiography showed dilation of all heart chambers with eccentric left ventricular hypertrophy, LVEF71%, and moderate MR, not fulfilling ARVC criteria. Cardiac MRI showed normal heart tissues with no area of fibrosis or fulfilling ARVC criteria.

Conclusion: Morphological features of benign and malignant/proarrhythmic variety of JWSs have been well characterized. Certain ECG patterns carry higher proarrhythmic risk. Patients recovering from VF requires ICD, but there is no consensus on therapy for other cases.

Keywords: J-wave syndromes, Early Repolarization, Brugada





Implantable Cardioverter Defibrillator in J-Wave Syndromes - Balancing the Tightrope between Sudden Cardiac Death and Cost-Effective Intervention

R. Triasnawati¹, Z.H. Ismail¹, F. Hidayati¹, E. Maharani¹,

¹Department of Cardiology and Vascular Medicine, Faculty of Medicine, Public Health, and Nursing, Universitas Gadjah Mada, Yogyakarta, Indonesia

Background: The J-wave syndromes (JWSs), consist of Brugada syndrome (BrS) and early repolarization syndrome (ERS). JWSs has evolved from a benign electrocardiographic (ECG) abnormality to a proarrhythmic state, becoming a significant cause of idiopathic ventricular fibrillation responsible for sudden cardiac death. J-waves are observed in inferior (II, III, aVF) or lateral (V4, V5, V6) leads, whereas in BrS, they are prominent in right precordial leads (V1-V3).

Case Illustration: Case 1: A 40-year-old male patient presented at the emergency room with cardiac arrest ventricular fibrillation (VF) mode. The patient had two events of fainting with convulsions at ages 30 and 39. No family history of similar complaints or related events. ECG showed J-waves in leads II, III, aVF, V2-3 and V5-6, as well as ST segment elevation in V2-3. Echocardiography showed functionally normal heart with left ventricular ejection fraction (LVEF) of 57% and mild mitral regurgitation (MR), not fulfilling ARVC criteria. Treadmill test result was no negative ischemic response and no arrhythmias. Holter recording captured J-wave pattern accompanied by ST-segment elevation in leads II, III, aVF, V4-6. The J-wave pattern in V2 resembles the Brugada type II/III pattern. Coronary MSCT results showed non-significant coronary artery disease (CAD) with calcification in the proximal part of the LAD. Patient received implantable cardioverter-defibrillator (ICD) considering cardiac arrest history with JWSs findings in ECG and Holter.

Case 2: A 34-year-old man hospitalized due to Dengue fever was presented with localized chest pain and palpitations. No family history of similar complaints or related events. Inpatient ECG captured Brugada type 1 pattern in V1. Holter recording captured J-wave pattern accompanied by ST-segment elevation in leads II, III, aVF, V4-6. Echocardiography showed dilation of all heart chambers with eccentric left ventricular hypertrophy, LVEF71%, and moderate MR, not fulfilling ARVC criteria. Cardiac MRI showed normal heart tissues with no area of fibrosis or fulfilling ARVC criteria.

Conclusion: Morphological features of benign and malignant/proarrhythmic variety of JWSs have been well characterized. Certain ECG patterns carry higher proarrhythmic risk. Patients recovering from VF require ICD, but there is no consensus on therapy for other cases.

Keywords: J-wave syndromes, Early Repolarization, Brugada

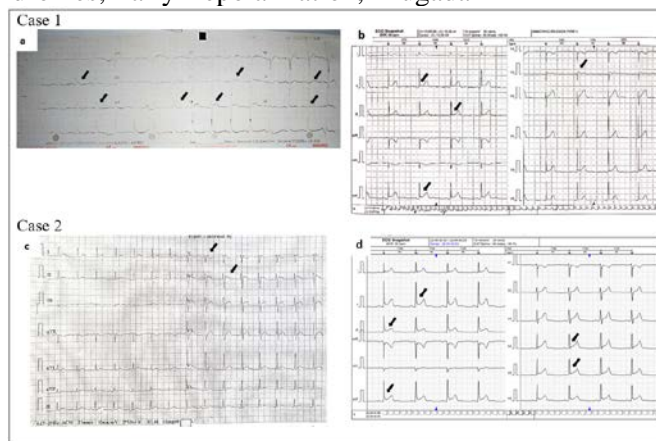


Figure. Case 1 : **a.** Sinus rhythm, pulse rate 90 beats per minute, J-wave (arrow) is seen in leads II, III, aVF, V2-3 and V5-6, and ST segment elevation in leads V2-3. **b.** Holter recording captured while the patient is walking, sinus rhythm is seen, the frequency is 55 beats per minute, the J-wave pattern is seen (arrows) accompanied by ST segment elevation in leads II, III, aVF, V4-6, the J-wave pattern in V2 resembles the type II/III Brugada pattern

Case 2 : **c.** Sinus rhythm, pulse rate 100 beats per minute, J-wave pattern in V1-2 resembling a type I Brugada pattern. **d.** Holter recording shows sinus rhythm, frequency 53 beats per minute, J-wave pattern is seen (arrows) accompanied by ST segment elevation in leads II, III, aVF, V4-6

Thyroid Storm and Supraventricular Tachycardia



R. Wulandari¹, A. Nurizal²

Hasanah Graha Afiah General Hospital, Depok, Indonesia

Background: In thyroid storm, supraventricular tachycardia is an uncommon presentation, only 2-20% of cases.

Case Illustration: A 50-year-old woman was brought to our emergency department because of chest pain. She has a complaint of a swollen and enlarged feeling of her cervical mass for a year. Supraventricular tachycardia were noted on electrocardiographic monitoring and reverted to sinus tachycardia after giving of digoxin and taking of propylthiouracil. On presentation, she was tachycardic to 160 bpm, tachypnea to 27 breaths per minute, hypertension to 158/98 mmHg. Her Glasgow coma scale was 15. On examination, She was agitated and acutely anxious but still awake, alert and oriented. She was diaphoretic with no jugular venous distention, no peripheral oedema and clear breath sounds on lung examination. Most notably, she has thyromegaly and exophthalmos. Initial complete blood count, electrolyte, glucose, renal function were all normal. The patient's thyroid function tests were : thyroid stimulating hormone < 0,005 μ IU/mL , free thyroxine 7.77 ng/dL. A cardiac ultrasound was LV systolic function decreased, 47%. On the Burch et al diagnostic point scale for thyroid storm, our patient score 55. By this scoring system, a score higher than 45 is suggestive of thyroid storm. She was treated as a case of thyroid storm. Our patient was successfully treated promptly for an emergency and thereafter he was referred for further evaluation of cause of thyromegaly and late onset anteroseptal STEMI.

Conclusion: Thyroid storm is rare case in emergency department and It has high mortality at 20 to 30% although with early diagnosis and aggressive treatment. Recognition of both typical and atypical presentations of the disease is mandatory. Further studies regarding the relationship between the thyroid gland and supraventricular tachyarrhythmia are needed.

Keywords: thyroid storm, burch-wartofsky point scale, supraventricular tachycardia

Left Bundle Area Pacing with Manual Approach in Pediatric Patients : Case Series

S.A Manurung, Y. Yuniadi, F. Ahmad, R. Chandara, D.Y. Hermanto, S.B Raharjo, D.A Hanafy

Division of Arrhythmia, Departement of Cardiology and Vascular Medicine Universitas Indonesia/
Harapan Kita National Cardiac Center

Background: Conduction system pacing (CSP) has arisen to be the standard in achieving physiologic conduction for permanent pacing indication. Long term deleterious effects of RV pacing are the intra LV conduction delay, and LV mechanical dyssynchrony which lead to profound myocardial disarray and cardiomyopathy. Studies have shown that permanent CSP is safe and feasible in patients with CHD and congenital TAVB although implant technique is complex. Due to high overall costs, CSP are limited in developing countries, such as Indonesia. We present 3 cases of post operative congenital heart disease and congenital TAVB with manual approach (figure 1).

Case Illustration: 5 y.o boy (13,5 kg) with double outlet right ventricle, subaortic VSD, secundum ASD underwent surgical DORV repair and ASD closure. Unfortunately TAVB developed afterwards. TPM was performed. We performed left bundle branch pacing (LBBP) using manual approach. Intrinsic QRS duration before implantation was 132 ms, after LBBP we achieved QRS duration 109 ms with RPWT 77 ms.

Second case 2 y.o boy (10 kg) with previous PDA ligation, epicardial PPM in 2021 has gone to elective replacement indicator (ERI). We performed LBBP using the same methods resulted in QRS duration of 106 ms, and RPWT 55 ms.

Third case 4 y.o boy (15 kg) with recurrent syncope and seizures due to congenital TAVB. Patient underwent TPM procedure and planned for PPM. LBBP was performed with the same techniques. We obtained QRS duration of 100 ms, and RPWT 60 ms.

Conclusion: Conduction system pacing, in this case LBBP is feasible with manual approach using modification of standard delivery stilet (we name it “Yogayun” stilet). This manual approach is worth to consider if cost seems to be the limitations with favorable good results.

Keywords: Conduction system pacing, left bundle pacing, congenital heart disease, manual approach

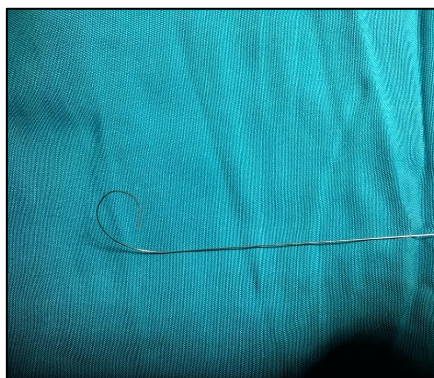


Figure 1. Manual approach using modified standard delivery stilet



Detrimental Effect of Oral Anticoagulation Cessation During LAA Closure

S.A Manurung, Y. Yuniadi, F. Ahmad, R. Chandara, D.Y. Hermanto, S.B Raharjo, D.A. Hanafy
Division of Arrhythmia, Departement of Cardiology and Vascular Medicine Universitas Indonesia/
Harapan Kita National Cardiac Center

Background: Patients with non-valvular atrial fibrillation who are undergoing chronic oral anticoagulant therapy (OAC) treatment occasionally require interruption of OAC treatment, in spite of that, oral anticoagulation is not a contraindication for performing transoesophageal echocardiography (TEE), therefore no interruption of OAC is needed. In this case we present deleterious effect of OAC cessation 7 days before TEE and proceeded to left atrial appendage (LAA) closure.

Case Illustration: 58 y.o.man with permanent long standing AF, history of CABG at 2005 is planned for LAA closure. Rivoraxaban 20 mg was discontinued 7 days before TEE until LAA closure procedure. TEE showed LAA windsock morphology, with ostium diameter of 20-30 mm, landing zone diameter of 21-23 mm, there was no thrombus found. Heparin was given after the transeptal procedure. After a while, patient felt chest discomfort abruptly, echocardiography showed no pericardial effusion, ECG showed ST elevation changes in high lateral leads. Ventricular fibrillation occurred and 200 joule DC shock was given. Coronary angiography showed total occlusion at left circumflex coronary artery with thrombus seen in the proximal part. Predilatation with 2,0 x 15 mm balloon and followed by 3,5 x 2-0 mm drug eluting stent at the proximal of LCx. Afterwards patient felt left side weakness. Digital subtraction angiography (DSA) showed normal flow of cerebral artery. Hence LAA closure procedure was postponed.

Conclusion: This case described deleterious effect of oral anticoagulation discontinuation in total of 7 days before TEE and LAA closure. ST elevation MI followed by transient ischemic stroke arised as a consequence of interruption of rivoraxaban. In GARFIELD-AF study the rate of discontinuation was 15%. Discontinuation for ≥ 7 consecutive days was associated with significantly higher all-cause mortality, stroke/SE, and MI risk. Caution should be exerted when considering any OAC discontinuation beyond 7 days.

Keywords: *Atrial fibrillation, oral anticoagulant, discontinuation, myocardial infarction, stroke*



Successful Ablation of Scar-related Ventricular Tachycardia using Decremental Evoke Potential Mapping in Patient with Ischemic Cardiomyopathy

S.A. Manurung, S.B Raharjo, R.Chandara, F.Ahmad, D.Y. Hermanto, D.A Hanafy, Y.Yuniadi
Division of Arrhythmia, Department of Cardiology & Vascular Medicine, Faculty of Medicine
Universitas Indonesia/ National Cardiovascular Center Harapan Kita

Background: Decremental evoke potential mapping (DeEP) is a new mapping approach to improve the sensitivity of isochronal late activation mapping (ILAM) during VT ablation in structural heart diseases. Here we report a case of VT ablation in ischemic cardiomyopathy that could not be mapped by a simple ILAM method.

Case Illustration: 60 y.o man with recurrent palpitation and syncope. Previous CABG procedure in 2001. Holter examination obtained frequent 30% PVC with 17 VT episodes with 4 minutes of total VT duration. Echocardiography showed decrease LV function of 50%. Coroangiography showed patent bypass grafts. LV geometry with ILAM and DeEP methods was done, decelerated zone and fractionated area found at posteroseptal area. Voltage mapping showed low voltage area at posterior, posteroseptal from basal to mid area. LAT mapping was performed while VT. Earliest activation was found at posteroseptal area. RF ablation was performed at posteroseptal area. Two frequent PVC found at posterolateral area were also ablated. Aggressive ventricular pacing did not induce any ventricular tachyarrhythmias. Patient was discharged. Holter monitoring afterwards showed no episodes of VT and significantly decreased frequency of PVC to 7%.

The concept of DeEP mapping is the initiation of a re-entrant VT circuit is dependent on decremental conduction through a critical zone of tissue. If this slow conduction occurs alongside site of unidirectional block, then a re-entrant circuit may develop. Decremental evoke potential mapping identifies the components of diseased myocardium that are more likely to be critical in maintaining the VT circuit. This is achieved by delivering an extra stimulus and comparing the local activation delay during steady-state conditions (S1) and after the extra stimuli (S2). This functional assessment of the VT substrate adds to the conventional mapping of local abnormal EGMs during VT ablation.

Conclusion: Decrement evoke potential mapping adding strategies in substrate identification to more directed VT ablation. Early activation mapping, voltage mapping and more ILAM are combined to achieved better results in VT ablation.

Keywords : *Ventricular tachycardia ablation, ILAM, decremental evoke potential mapping*



Drug Resistant Supraventricular Tachycardia in Infants

R. Soekardi¹, S. Chalid¹

¹Faculty of Medicine, Universitas Indonesia-Cipto Mangunkusumo General Hospital, Jakarta, Indonesia

Background: Accessory pathway-mediated tachycardia constitutes 80 % tachyarrhythmias during infancy. When infants experience continuous medically unresponsive supraventricular tachycardia (SVT), alternative treatment methods must be considered to resolve the issue.

Case Illustration: The patient, a 1-month-16 days old female, presented to our emergency room with tachycardia. Initial assessment shows heart rate 250 bpm, blood pressure 88/42 mmHg (p50-99), no dyspnea, and oxygen level 99% without oxygen support. Consequently, the patient was admitted to Pediatric Intensive Care Unit (PICU). Previously, when the patient was 11 days old, she came in to another ER for dyspnea, pallor, repeated seizures, and tachycardia. An electrocardiogram (ECG) examination at that time indicated SVT, which later progressed to SVT with aberrancy dd ventricular tachycardia (VT). In the PICU, the patient was administered bisoprolol and amiodarone; however, her blood pressure dropped to p5-50, resulting in the discontinuation of amiodarone. Cardioversion was performed, and lidocaine was administered, but there was no response. The ECG showed wide QRS tachycardia with AV dissociation, which the echocardiography showed dilated cardiomyopathy. Subsequently, the patient was diagnosed with focal junctional ectopic tachycardia and an accessory pathway from the atrioventricular (AV) node to the fascicular. A modified ablation procedure was performed on the accessory pathway, which yielded positive results and resolved the tachycardia. Junctional ectopic foci were not ablated due to the risk of total av block. Post-operative, the patient remains hemodynamically stable. However, there is still a very high risk of tachyarrhythmia arising from the junction, so our EP team made a medical plan for rate control.

Conclusion: Transcatheter ablation was effective for infant with arrhythmias that persist after multiple failed attempt with medical management

Keywords: Accessory pathway; Focal junction ectopic tachycardia; Supraventricular tachycardia; Transcatheter ablation



Drug Resistant Supraventricular Tachycardia in Infants

S. Chalid¹, R. Sukardi², Tartila¹, I. Yuniar¹, S. Salim³, A. Pramudita³, M. Yamin³

¹Pediatric Emergency and Intensive Care Division, Faculty of Medicine, Universitas Indonesia-Cipto Mangunkusumo General Hospital, Jakarta, Indonesia

²Cardiovascular Centre, Cipto Mangunkusumo General Hospital, Jakarta, Indonesia

³Cardiovascular Division, Internal Medicine, Faculty of Medicine, Universitas Indonesia-Cipto Mangunkusumo General Hospital, Jakarta, Indonesia

Background: Accessory pathway-mediated tachycardia constitutes 80 % tachyarrhythmias during infancy. When infants experience continuous medically unresponsive supraventricular tachycardia (SVT), alternative treatment methods must be considered to resolve the issue.

Case Illustration: The patient, a 1-month-16 days old female, presented to our emergency room with tachycardia. Initial assessment shows heart rate 250 bpm, blood pressure 88/42 mmHg (p50-99), no dyspnea, and oxygen level 99% without oxygen support. Consequently, the patient was admitted to Pediatric Intensive Care Unit (PICU). Previously, when the patient was 11 days old, she came in to another ER for dyspnea, pallor, repeated seizures, and tachycardia. An electrocardiogram (ECG) examination at that time indicated SVT, which later progressed to SVT with aberrancy and ventricular tachycardia (VT). In the PICU, the patient was administered bisoprolol and amiodarone; however, her blood pressure dropped to p5-50, resulting in the discontinuation of amiodarone. Cardioversion was performed, and lidocaine was administered, but there was no response. The ECG showed wide QRS tachycardia with AV dissociation, which the echocardiography showed dilated cardiomyopathy. Subsequently, the patient was diagnosed with focal junctional ectopic tachycardia and an accessory pathway from the atrioventricular (AV) node to the fascicular. A modified ablation procedure was performed on the accessory pathway, which yielded positive results and resolved the tachycardia. Junctional ectopic foci were not ablated due to the risk of total AV block. Post-operative, the patient remains hemodynamically stable. However, there is still a very high risk of tachyarrhythmia arising from the junction, so our EP team made a medical plan for rate control.

Conclusion: Transcatheter ablation was effective for infant with arrhythmias that persist after multiple failed attempts with medical management

Keywords: Accessory pathway; Focal junction ectopic tachycardia; Supraventricular tachycardia; Transcatheter ablation



The “Perfect Time” Pacemaker Implantation for Bifascicular Block (Alternating BBB with Mobitz type 2) at Elderly Patient

S. Chandra¹, A. A. Lukito¹, R.A.P. Fernandes¹, H. Hutabarat¹

¹Department Cardiology and Vascular Medicine, Siloam Hospital Lippo Village, Tangerang, Indonesia.

Background: Bifascicular block is a conduction disturbance with reported prevalence 1-1,5% with up to 25% of adult patients presenting with syncope, also there was asymptomatic patient. Bifascicular block, a pattern when normal physiologic activation in the His-Purkinje system is interrupted. Interruptions in conduction may result in RBBB, LAFB, or LPFB, with bifascicular block resulting when two of these three are identified from the ECG. The perfect time pacemaker implantation based on symptoms and ECG results also age of patients.

Case Illustration: A male 82 years old came to OPD with low blood pressure 109/50, no fatigue or syncope. History of coronary artery disease complete revascularization and hypertension. Exercise everyday walking 30 minutes, no complaint after exercise. On physical examination, BP 128/68 mmHg, pulse 63 bpm regular. ECG result AV block 2nd degree (type 2) with LBBB, rate 63 bpm. After comparison ECG before, 2 months was change from sinus rhythm without bundle branch block, until 1 month later the ECG changes to RBBB until now AV block 2nd degree (type 2) with LBBB. Treadmill stress test result was negative ischemic response, appropriate elevated heart rate. Fortunately, on echocardiography result was improving wall motion and improving LV ejection fraction. Based on this ECG, educated to patient for awareness for dizziness and pre-syncope symptoms, and plan to pacemaker.

Conclusion: Pacing is indicated when bifascicular block is associated with the following: complete block and symptomatic bradycardia, alternating bundle branch block, intermittent type 2 second degree block with or without related symptoms, symptoms suggestive of bradycardia and an HV interval greater than 100 ms on invasive electrophysiology study. Permanent pacemaker implantation is not indicated for BBB without symptoms, with the exception of alternating BBB because of these patients will develop AVB (1-2% per year). The risk of pacemaker implantation and long-term transvenous lead complications are higher than the benefits of pacemaker implantation. But in this patient had alternating bundle branch block, that will progress rapidly toward high degree AVB. Therefore, a pacemaker should be implanted as soon as the alternating BBB with AVB type 2 is detected even in the absence of symptoms.

Keywords: Bifascicular-block, Alternating-BBB, Pacemaker, Elderly.

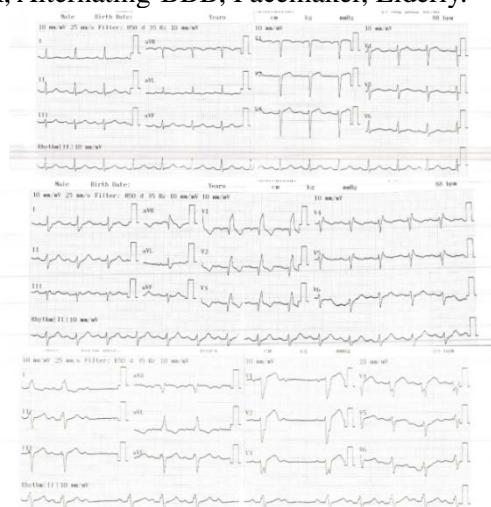


Figure 1. Dramatic ECG changes



Epicardial Pacing: Insight of Late Superior Vena Cava Thromboembolism Induced Pacemaker Lead Fracture in A Young Woman

S. Fong, S. Adiwinata, B. M. Setiadi

Department of Cardiology and Vascular Medicine, Faculty of Medicine, Sam Ratulangi University,
Manado, Indonesia

Background: Delayed superior vena cava (SVC) thromboembolism after pacemaker implantation is a rare but fatal outcome. We present a case of SVC thromboembolism induced pacemaker lead fracture in young woman resulted in implantation of epicardial pacing.

Case Illustration: A 35-years old woman presented with presyncope. Patient's had pacemaker implanted for 10 years which never been interrogated as she felt asymptomatic. Heart rate was 35 beats/minute, blood pressure at 108/66 mmHg. Electrocardiogram showed uncaptured total AV Block, echocardiography showed normal heart function and structures. Pacemaker malfunction was suspected as culprit. During attempted urgent permanent pacemaker replacement procedure, the pacemaker lead was found fractured and the wire failed to cross SVC, the procedure then aborted. Later, patient's CTA (computed tomography angiography) scan showed near total occlusion at SVC with collateral flow from chest wall veins and intra lumen thrombus at right proximal jugular vein. Epicardial pacing placement and extraction of old pacemaker through thoracostomy was performed. Post procedure, patient was stable without complaint.

Pacemaker implantation may cause venous endothelial injury releasing coagulation factors, hence, venous thromboembolism. Development of collateral flow decreases flow in the affected venous segment which extent the thrombus formations causing lead fracture induced pacemaker malfunction. Epicardial pacing is the choice in venous occlusion as presented in this case.

Conclusion: Routine control of pacemaker device and early screening for thrombus is a must. Epicardial pacing can be done in venous access occlusion case.

Keywords: epicardial pacing, superior vena cava thromboembolism, pacemaker lead fracture

ATHLETE'S HEART IS A PROARRHYTHMIC HEART: FACT OR MYTH?

S. Haidar¹, F. Hidayati², E. Maharani²

¹Resident of Cardiology and Vascular Medicine, Gadjah Mada University/ Sardjito General Hospital, Yogyakarta

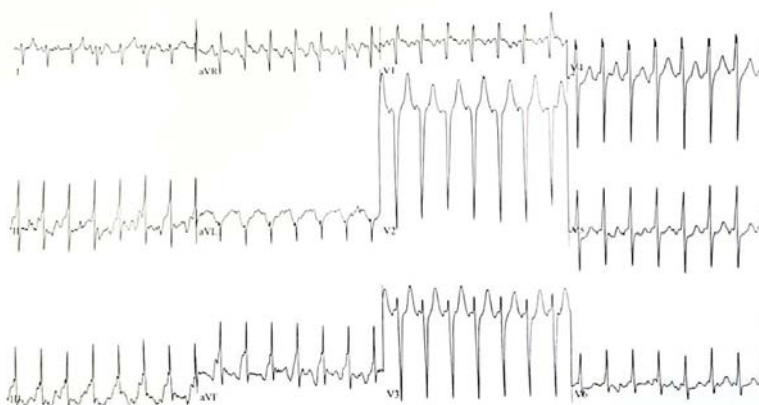
²Staff Department of Cardiology and Vascular Medicine, Faculty of Medicine, Public Health and Nursing Gadjah Mada University Sardjito General Hospital, Yogyakarta

Background: Athlete's heart is known for its marvellous adaptation on extreme physical exercise and paradoxically at rest. However, arrhythmias are still a concern with magnitude varying from benign (e.g. sinus bradyarrhythmia) to malignant (e.g. ventricular arrhythmia and sudden death). Conceptually, the relation between sports and arrhythmias can be considered along three lines. First is sports as trigger of arrhythmia. This is the most widely accepted view that athletes may have an underlying condition and the physical exercise simply trigger arrhythmia to occur. Second is sport as a substrate promotor. Physical exercise may promote development of an underlying arrhythmic substrate, which accelerates occurrence of arrhythmic event. Third, sport as a substrate inducer. Natural remodelling caused by systematic training induce a substrate of arrhythmia, even in the absence of underlying genetic predisposition. Understanding possible mechanisms of the arrhythmia is essential to determine further work up and management, including eligibility of the athlete to continue exercise.

Case Illustration: An asymptomatic 50 year marathon runner came to our hospital for medical check-up. His treadmill test revealed non-sustained atrial tachycardia during peak exercise (stage 2) without any symptoms, the ischemia response could not be evaluated with normal hemodynamic. Further testing using Holter monitoring for 24 hours detected sustained ventricular tachycardia. Echocardiography showed LV concentric remodelling with normal LV systolic function, good LA function, and normokinetic. CMR report showed subendocardial fibrosis at mid anterior and apical segment of LV with a transmural index 50% (could not exclude ischemic cause of fibrosis nor infiltrative disease). Patient is planned for coronary evaluation using CCTA to exclude ischemia.

Conclusion: Recognizing athlete's heart as a proarrhythmic heart is a crucial step in managing arrhythmia in athletes. Evaluation should take into account electrical, hemodynamic and structural assessment. Analysing findings can provide insights on management and guiding athletes' on subsequent training.

Keywords: Athlete's heart, atrial tachycardia, ventricular tachycardia, subendocardial fibrosis





Epigastric Pain and Migraine Unmasking Spontaneous *Type-1 Brugada Syndrome: Important Recognition for General Practitioner*

S. Rahma¹, T. Astiawati², A. Wibisono², E. Ruspiono², F.S. Laitupa², A.W. Nugraha²

¹General Practitioner of Dr. Iskak General Hospital, Tulungagung, Indonesia

²Cardiologist of Dr. Iskak General Hospital, Tulungagung, Indonesia

Background: *Brugada* syndrome (BrS) is unfamiliar for general practitioner (GP). It's infrequently happening so it's often misdiagnosed as dyspepsia or acute coronary syndrome. One of serious BrS complications is sudden cardiac death (SCD), so we have to establish the diagnose accurately.

Case Illustration: A 66-year old man came to the emergency room with epigastric pain radiating to his back, nausea, and diaphoresis for 2 months. The symptoms worsened in the last 1 week along with severe migraine. He also had a 1 month fever history without syncope history or SCD family. The symptoms didn't improve with Paracetamol and Antacid. The physical examination was normal except epigastric tenderness. The ECG showed prominent coved ST-segment elevation followed by T-wave inversion in lead V1-V3, with day-to-day variation of BrS pattern (Fig 1). Shanghai's scoring system was ≥ 3.5 score revealed as definite BrS. The laboratory showed mild hyponatremia (134 mmol/L). The TTE revealed mild mitral regurgitation, global normokinetic with 54% LVEF. He was discharged with Bisoprolol, Paracetamol, Lansoprazole, Antacid, and Sucralfate. The epigastric pain reduced and still persisted without the ECG pattern changes in 4 month follow up.

Conclusion: It's a challenge for GP to immediately and promptly diagnose *Brugada* syndrome with epigastric pain and migraine. However, type-1 BrS ECG day-to-day variation pattern might indicate autonomic tone disorder and predict VF events. Epigastric pain can be due to arrhythmia which can cause atypical chest pain. Fever, and hyponatremia can unmask BrS. Migraine also had a strong correlation with BrS. It is needed to continue monitoring since malignant type-1 BrS may need ICD implantation.

Keywords: Epigastric pain, Migraine, *Brugada Syndrome*, Arrhythmia, Sudden Cardiac Death

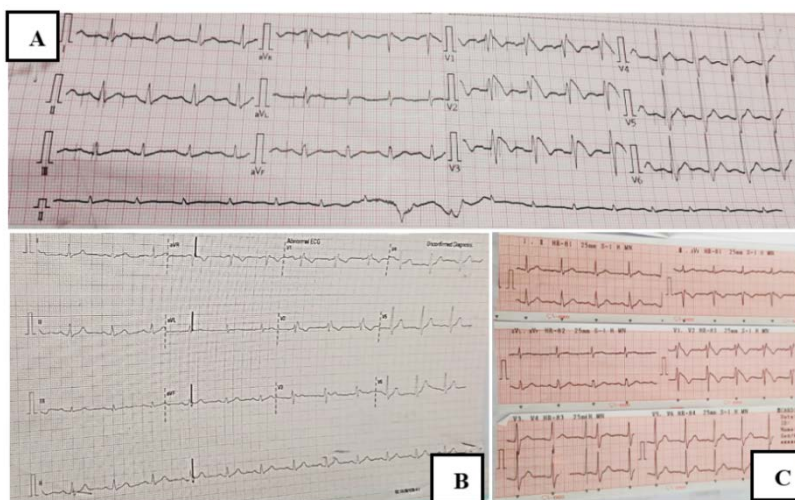


Figure 1. The differences of type-1 BrS day-to-day ECG pattern during 4 months follow up; A) ECG patient in ER, B) inpatient ECG, C) outpatient polyclinic ECG.



Vasovagal Syncope and Sinus Node Dysfunction in a Patient with Cerebral Infarction: A Case Report

S.S. Baskoro¹, G.D. Saerang¹, A. Rizal^{1,2}, S. Widito^{1,2}

¹Brawijaya Cardiovascular Research Center, Department of Cardiology and Vascular Medicine, Faculty of Medicine, Universitas Brawijaya, Malang, Indonesia

²Department of Cardiology and Vascular Medicine, Faculty of Medicine, Universitas Brawijaya, Malang, Indonesia

Background: Vasovagal syncope (VVS) is a common cause of transient loss of consciousness, triggered by emotional or orthostatic stress. Diagnosis of both VVS in patient with Sinus node dysfunction (SND) was not unheard of and posed a challenge in its diagnosis and management. This Case Report aimed to describe the diagnosis and management of such cases.

Case Illustration: We report a case of a 67-year-old male patient who presented with recurrent episodes of syncope for 3 months with history of cerebral infarction on levetiracetam therapy. He fainted for less than 5 minutes preceded by light-headedness while standing in line and recovered spontaneously. Electrocardiogram (ECG) showed third-degree atrioventricular block with a ventricular rate of 42 beats per minute. He was given atropine and dopamine to increase his heart rate, but the effect was transient. Holter monitoring revealed intermittent sinus pauses up to 4 seconds and junctional escape rhythm. Echocardiography showed normal cardiac structure and function. He underwent permanent pacemaker implantation with VVI mode and was discharged without further symptoms.

Conclusion: This case illustrated the coexistence of VVS and SND in a patient with syncope. The diagnosis of VVS was based on the clinical presentation and the absence of structural heart disease. Permanent pacemaker implantation was effective in preventing recurrent syncope and improving the quality of life of the patient.

Keywords: Vasovagal syncope, sinus node dysfunction, pacemaker, case report



A Case Report of Recurrent Ventricular Tachycardia (VT) Storm: Primary Care Perspectives

S. Safitri¹, R. M. Candrasatria²

¹RSUD Menggala, Tulang Bawang, Indonesia

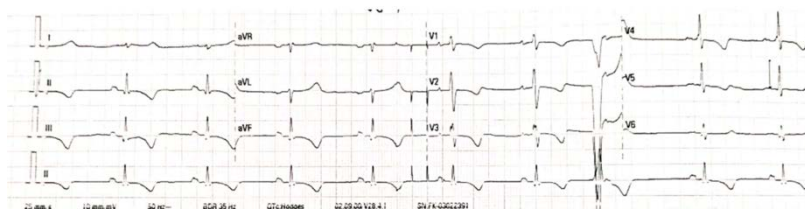
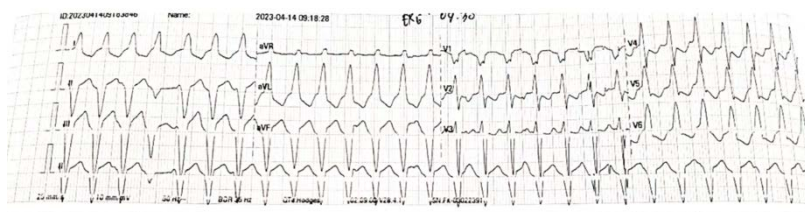
²RSUD dr. H Abdul Moeloek, Bandar Lampung, Indonesia

Background: Ventricular tachycardia (VT) storm is a form of electrical storm that refers to a life-threatening syndromes, characterized by multiple recurrent of sustained ventricular arrhythmias within short period time. This condition can occur in various clinical states, often present as a medical emergency and related to high morbidity and mortality burden. Management of VT storm can be more challenging in primary health care setting.

Case Illustration: We present a patient with recurrent ventricular tachycardia (VT) storm. A 57-year old man, with history of congestive heart failure and VT 2 months ago, admitted to emergency department with chief complaint of shortness of breath, he was also had chest pain, palpitation, vomiting, epigastric pain. On admission; he had HR 173 tpm, BP of 70/40 mmHg, RR of 28 tpm. ECG revealed monomorphic VT with unstable hemodynamic. According to ACLS (advanced cardiac life support) algorithm, direct cardioversion of 100 joules was given continued with intravenous amiodaron, VT reverted to sinus rhythm with T inverted in all leads. Laboratory findings; potassium 4,08 mmol/L, sodium 140 mmol/L, chloride 98 mmol/L, ureum 31 mg/dL, creatinine 1,6 mg/dL, CKMB 32 U/L, TSH 6,23. Chest x-ray showed cardiomegaly. His past echocardiography (a year ago) revealed normal EF, normal cardiac dimension and structures. Patient admitted to intensive care unit but he had recurrent VT, and terminated again after direct cardioversions. He was given antiplatelet, oral amiodaron, and vasoconstrictor as needed. He was continued observed at ICU.

Conclusion: VT storm occur in primary care can be managed according to the simultaneously steps: initial diagnosis, early rapid emergency management to stabilize patient with ACLS algorithm for acute termination of VT, approaching and correcting the underlying causes, and administered the antiarrhythmic drugs. Planning to refer patient to cardiovascular center due to limitation at primary care setting to get definitive management is required.

Keywords: Ventricular arrhythmia, VT storm, recurrent, primary health care





Recover symptoms and ejection fraction after atrial fibrillation ablation: A case report

S. Salim^{1,2}, M. Yamin^{1,2}, R. Sukardi², A. Pramudita^{1,2}, C. Wulanningsari², R. Widiyanto², R. Malik³

¹Division of Cardiology, Department of Internal Medicine, Faculty of Medicine, Universitas Indonesia, Jakarta, Indonesia; ²Integrated Cardiac Centre - Dr. Cipto Mangunkusumo National Central General Hospital, Jakarta, Indonesia; ³Dr. Cipto Mangunkusumo National Central General Hospital, Jakarta, Indonesia.

Background: Coronary artery disease and atrial fibrillation are frequently found together, and both can cause heart failure. Complete revascularization and AF ablation were both recommended for a heart failure patient.

Case Illustration: A 57-year-old man with HFrEF, CAD 2 vascular disease following PCI to the LAD and LCX, and paroxysmal AF arrives at our clinic with worsening dyspnea. He had 80% stenosis of his LAD and LCX, both of which had been opened six months previously. Although his EF increased from 25% to 47.8%, he continues to experience paroxysmal AF and heart failure symptoms. He underwent AF ablation, which improved his symptoms, bringing him from NYHA functional class IV to class I, which he maintained for two years after the ablation. Additionally, his LVEF improved from 47.8% to 60.0%.

Conclusion: This case study shows a patient who benefits from AF ablation. Atrial Fibrillation Management Guidelines published by the European Society of Cardiology (ESC) in 2020 give class I recommendation for AF ablation in heart failure reduced EF. The recent CASTLE-AF RCT found that patients with HFrEF who underwent AF catheter ablation experienced a decrease in all-cause mortality and hospitalization for worsening HF. Even in the vicinity of coronary artery disease, AF ablation should be considered in Heart Failure patients to improve symptoms, exercise tolerance, quality of life, and LVEF in AF patients with HF.

Keywords: AF ablation, heart failure, ejection fraction (EF), symptoms recovery

Successful Radiofrequency Catheter Ablation of Left Lateral Accessory Pathway in A Patient with Orthodromic Atrioventricular Reentrant Tachycardia

S. Y Pradana^{1,2}, M.S Goma^{1,2}, A.Z Abidin^{1,2}, A. Alamsyaputra^{1,2}, P. Ardhianto^{1,2}

¹Department of Cardiology and Vascular Medicine, Faculty of Medicine Diponegoro University, Semarang, Indonesia

²Dr. Kariadi Central General Hospital Semarang, Indonesia

Background: Orthodromic atrioventricular reentrant tachycardia (AVRT) is a supraventricular tachycardia commonly involving an accessory pathway (AP) with approximately 30–40% are related to concealed APs exhibiting a unidirectional, typically exclusive retrograde, conduction pattern. In rare cases, AVRTs that occur via a concealed AP does not exhibit pre-excitation on resting electrocardiogram. This case report highlights a patient presenting with tachycardia symptoms and revealed a concealed AP during electrophysiological study, leading to successful ablation and resolution of symptoms.

Case Illustration: A 59 years old female hospitalized for a sudden tachycardia that occur during daily activity. She underwent a 24-hour holter monitoring but didnt recorded any SVT episodes. Laboratory result showed within normal limit. Echocardiography showed no cardiac structure abnormality with normal right and left ventricle function. She felt uncomfortable with the occurrence of palpitation so that the electrophysiology study was conducted. During right ventricular pacing, supraventricular tachycardia was easily induced by programmed electrical stimulation and showed the classic eccentric pattern of orthodromic AVRT using left lateral accessory pathway. Several mapping attempts were performed retrogradely, but we found difficulties entering the left ventricle at the aortic cusp level. The accessory pathway successfully ablated through antegrade approach via transseptal puncture. After procedure the symptom was relieved and she discharged the day after.

Conclusion: Comprehensive management can significantly alleviate symptoms in patient with orthodromic AVRT, including medication and catheter ablation. Identifying concealed accessory pathways through electrophysiological studies is essential for successful ablation, resolution of tachycardia, and improves the quality of life.

Keywords: *orthodromic atrioventricular reentrant tachycardia, left lateral accessory pathway, radiofrequency catheter ablation*

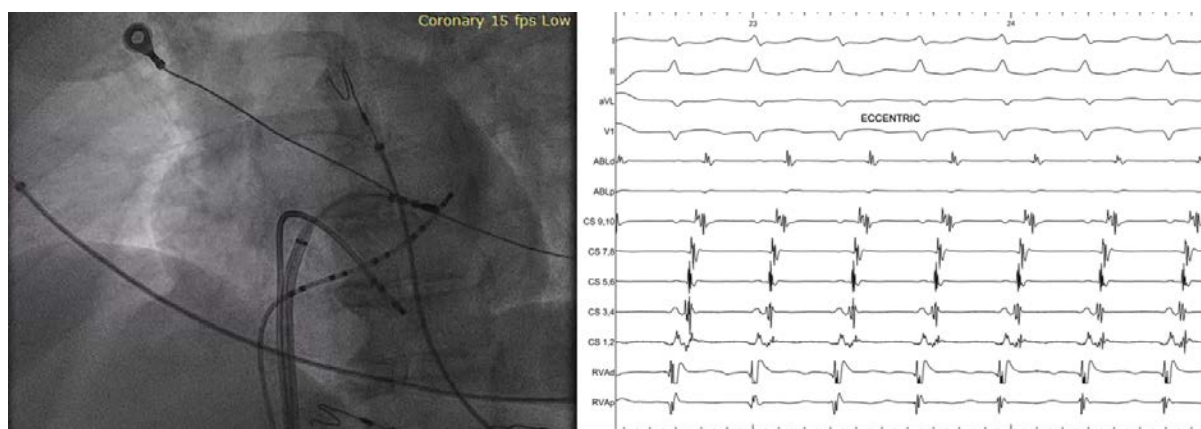


Figure 1. A successful ablation of orthodromic atrioventricular reentrant tachycardia using left lateral accessory pathway

Shark Fin Pattern as a Predictor of Poor Prognosis in Patient with STEMI : a Case Report

Sulastri¹, S.H Putra²

¹General Practitioner, Soekarno General Hospital, Bangka Belitung Island, Indonesia

²Cardiologist, Soekarno General Hospital, Bangka Belitung Island, Indonesia

Background: Differentiating the origin of wide complex tachycardia is difficult. Shark fin electrocardiographic (ECG) pattern is a rare ECG pattern associated with poor prognosis in a patient with ST-elevation myocardial infraction.

Case Presentation: a 26-year-old male presented to the ED with complaints of chest pain, dyspnea, diaphoresis and vomiting for two hours. He had a 1-2 pack-day smoking history. On examination, his BP was 80/50 mmHg, HR was 120 bpm, RR 30 x/m, temperature 36,5 Celcius, and oxygen saturation 89% in room air. There were ronchi on both the lungs. The Extremitas was acral coldness, CRT <2". The ECG showed wide complex tachycardia that was later identified as morphology sahrk fin pattern of ST elevation in lead I, AVL, V1-3. The arterial blood gas showed acute respiratory distress syndrome and asidosis respiratory. The electrolite level was within normal limits. X-Ray showed edema pulmonum. Oxygen was given at the rate 15 lpm to maintain oxygen saturation of 90-96%. The patient treated immediately with aspirin 160 mg, clopidogrel 300mg and atorvastatin 40 mg. The patient given norepinephrin for treatment shock cardiogenic and intubation due to ARDS. The fibrinolytic did not given due to unstable hemodynamic. During preparation of intubation, the patient was unconsciousness and had no pulse with ECG on monitor VT/VF, but even after we permofmed cardio pulmonary resuscitation, the patient was stated death.

Conclusion: The shark fin pattern is a high risk ECG pattern of STEMI, which should be diagnosed early and differentiated from other condition causing similar waveforms such as wide complex tachycardia and hyperkalemia. The shark fin STEMI is a sign of poor prognosis in patient with STEMI because associated with high risk of cardiogenic shock and ventricular fibrillation. The aggressive management, including mechanical circulary support is necessary.

Keywords: *Shark fin pattern, STEMI, ST-elevation*

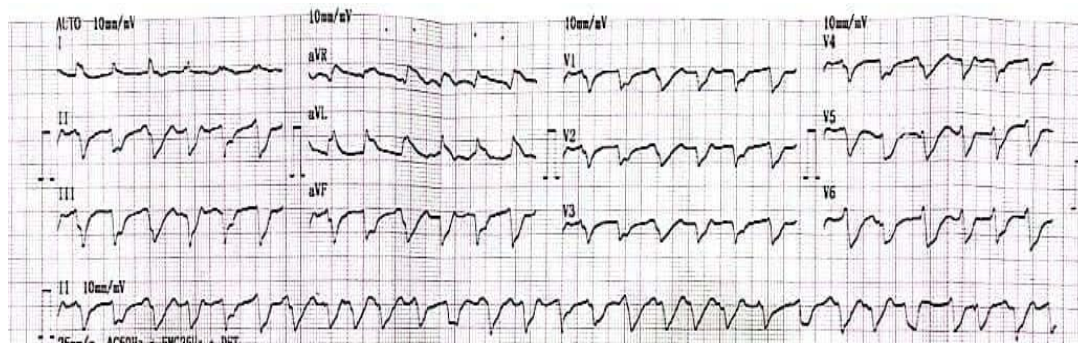


Fig. 1. The ECG showed wide complex tachycardia that was later identified as morphology shark fin pattern of ST elevation in lead I, AVL, V1-3.

The Role of Permanent Pacemaker (PPM) in a Patient with Torsade de Pointes Induced By Complete Atrioventricular Block: a Case Report

Sulastri¹, S.H Putra²

¹General Practitioner, Soekarno General Hospital, Bangka Belitung Island, Indonesia

²Cardiologist, Soekarno General Hospital, Bangka Belitung Island, Indonesia

Background: Torsade de pointes (TdP) is a malignant ventricular arrhythmia and is potentially life-threatening. Complete atrioventricular block (CAVB) accompanied by QT interval prolongation and premature ventricular complex (PVC) is known to be one of the major factors predisposing to TdP.

Case Presentation: a 62-year-old woman, was admitted to our hospital for seizures and syncope. She had several episodes of syncope in the last few hours. She had a history of hypertension. Electrocardiography showed CAVB with a rate of 36 bpm and frequent PVCs. Echocardiography showed hypertrophy in the left ventricle, LVEF of 63%. While being monitored in the cardiac intensive care unit, she suddenly developed TdP and leading to syncope and seizure. She had recurrence episodes of TdP until transvenous temporary pacemaker was in effect. All TdP episodes were triggered by an QT interval prolongation and PVC with R on T phenomena. The patient was further treated with single chamber permanent pacemaker. The 2-month follow-up was uneventful.

Conclusion: acquired CAVB may sometimes induce TdP and the episodes of TdP result in seizure, syncope, cardiac arrest, and even death due to degeneration into ventricular fibrillation. PVCs especially "R-on-T" phenomenon and QT interval prolongation should alert physicians as precursors for TdP. Early recognition and implantation of cardiac pacemaker can be lifesaving.

Keywords: *Permanent Pacemaker, Torsade de Pointes, Complete Atrioventricular Block, Prolonged QT-Interval*

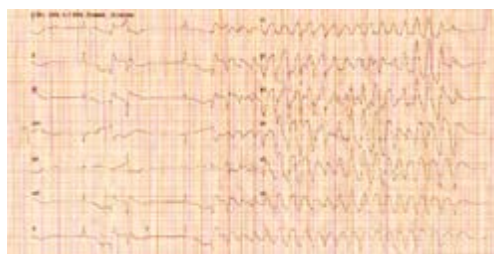

Fig. 1. a TdP episode triggered by a Prolonged QT interval and an early PVC hit the descending portion of the T wave

WIDE QRS COMPLEX TACHYCARDIA IN A YOUNG MAN: VT OR NOT?

T.B. Prakoso¹, M.W. Hadi¹, A.Y.A.B. Mochtar¹, P. Ardianto¹

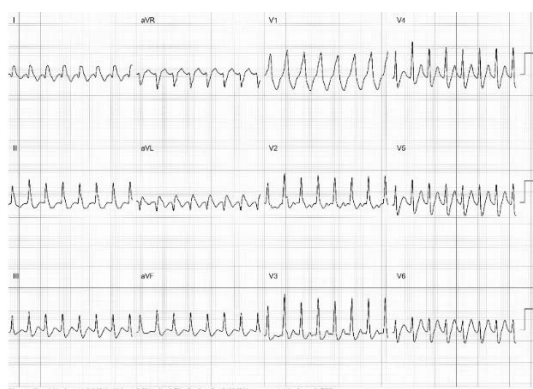
¹Department of Cardiology and Vascular Medicine, Diponegoro University, Semarang, Indonesia

Background: Wide complex tachycardia is a common rhythm found in ECG. There are 4 arrhythmia that can cause wide QRS complex tachycardia, which are: ventricular tachycardia (VT) which is the most common, supraventricular tachycardia (SVT) with abberancy, SVT with pre-excitation or ventricular paced rhythm. Brugada and Vereckeï algorithm are commonly used to distinguish VT from SVT with abnormal intraventricular conduction. Despite the high sensitivity and specificity reported in original cohorts, their use in the clinical setting has consistently showed low reproducibility.

Case Illustration: This is a case report of a 17 years old man referred to our clinic complained worsening episodes of palpitation for one year. His physical examination was normal. His chest X-Ray and laboratory test revealed normal results. The ECG showed wide QRS complex tachycardia with RBBB morphology. According to Brugada and Vereckeï algorithm, it was ventricular tachycardia. According to step 1 to step 3 in the Brugada algorithm, the rhythm still could be diagnosed as SVT, but from morphology criteria, it was classified to VT, since it had atypical RBBB morphology (monophasic in lead V1 and V6). He underwent an electrophysiology study procedure which revealed orthodromic AVRT with RBBB as final diagnosis. Then he had radio frequency ablation (RFA) procedure at left lateral accessories pathway and it was successful. No complications were found from the procedure and later he discharged from the hospital.

Conclusion: There are numerous algorithms and criteria for the diagnosis of VT. They have a high sensitivity, but in general, their validation studies excluded patients with accessory pathways. Our case remarks the limitation of ECG algorithms to differentiate VT and preexcited SVT. These algorithms may orient the initial diagnosis, but performing an electrophysiology study seems mandatory to make a final diagnosis.

Keywords: Wide QRS Complex Tachycardia, Atrioventricular Reentrant Tachycardia, Accessories Pathway



Picture 1. The patient's electrocardiogram obtained before electrophysiology study



Type 1 Brugada in Weil's Disease : unmasked or just a phenocopy?

T. H. Chau¹, Irnizarifka^{1,2}, H. Arifianto^{1,2}, E.L. Wulandari³

¹Universitas Sebelas Maret Hospital, Surakarta

²Department of Cardiology and Vascular Medicine, Faculty of Medicine, Universitas Sebelas Maret, Surakarta

³Division of Internal Medicine, Universitas Sebelas Maret Hospital, Surakarta

Background: Since Brugada Syndrome was found in 1992, researchers were trying to understand this syndrome, leading to three main hypotheses, that until now, is still remain disputed : abnormal repolarization, depolarization, or current-load match. Two decades later, Baranchuk and colleagues were proposing a new terminology “Brugada Phenocopy” to be used where Brugada-like pattern which was induced by reversible conditions, like metabolic conditions, mechanical compression, ischaemia, and myocardial or pericardial diseases. Unfortunately to date, management of brugada phenocopy, aside from triggers avoidance, is still under debate.

Case Illustration: 32-years-old male admitted to UNS Hospital with 5th day of febrile. Further work-up led to diagnosis of Weil's Disease, hence treatment was introduced. During admission, stabile new-onset 2:1 conduction atrial flutter appeared; thus, he was consulted to cardiovascular department with suspicion of myocarditis. He was immediately transferred to ICVCU for strict monitoring. High-sensitive troponin level was high (2040 ng/L) and echocardiography showed impaired LV function (LVEF of 40%). Standard therapy of heart failure was initiated. Atrial flutter turned onto atrial fibrillation with rapid ventricular response on the next day, which compromising his haemodynamic. Emergency electrical cardioversion was done and converted the rhythm to sinus tachycardia with 1st degree AV block. At this time, type 1 Brugada pattern came out on 12-leads ECG. On the next day, unstable episode of atrial fibrillation reappeared, so thus electrical cardioversion was done once more. Regrettably, few hours later episode of cardiac arrest with ventricular fibrillation ensued.

Conclusion: Brugada-like pattern did exist and could appeared in Weil's Disease. It is easy to be recognized, but still challenging to be distinguished from the true one. Unfortunate cardiac arrest could suddenly ensue.

Keywords: *Brugada syndrome, weil's disease, cardiac arrest*

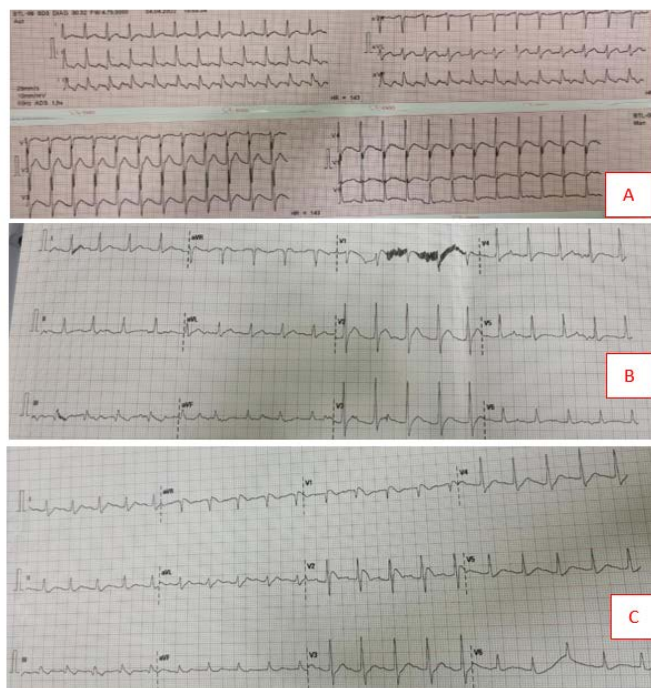


Figure 1. Atrial Flutter with 2:1 Conduction (A). Sinus Tachycardia with 1st Degree AV Block [after 1st cardioversion] (B). Sinus tachycardia with 1st Degree AV Block [after 2nd cardioversion] (C). Type-1 Brugada was noticeably found on B and C.



A case report of sick sinus syndrome in younger female

T. Julianti¹, J.A. Setiawan¹, S. Ng²

¹Faculty of Medicine, University of Pelita Harapan, Tangerang, Indonesia

²Department of Cardiology, Siloam Hospital Lippo Village, Tangerang, Indonesia.

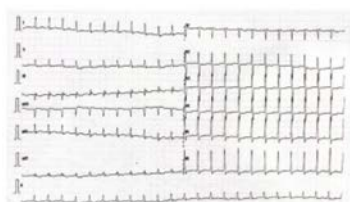
Background: Sick sinus syndrome (SSS) is a common arrhythmia amongst elderly over 65. In the younger population (< 65 yo), the incidence is rare (0.17 to 0.37 per 1,000 person-years) and therefore might be underdiagnosed. SSS can manifest as tachy-brady syndrome, which causes palpitations, lightheadedness, and fatigue. Extreme bradycardia or sinus arrest can also cause presyncope or syncope. This report aims to present a case of sick sinus syndrome in a patient aged <65y.

Case Illustration: A 60-year-old woman presented to the emergency department with palpitations and near-syncope episode. She had a history of hypertension and recurrent hypokalemia. She had undergone several investigations including coronary angiography, echocardiography and Holter recording, which all revealed no remarkable findings. She received routine bisoprolol 5 mg once daily. Electrolyte levels were within normal range but ECG revealed supraventricular tachycardia (Figure 1a). She was initially given digoxin intravenous, but she became bradycardic (Figure 1b), so all her medications, including beta-blocker, were stopped for several days to allow for a complete wash-out. Despite being stopped, continuous ECG and vital signs monitor still recorded heart rate fluctuations between 30-120 bpm and several episodes of sinus pause for 1662-1783 ms (Figure 1c). Moreover, alternating bouts of tachycardia in the form of atrial fibrillations and bradycardia were reported.

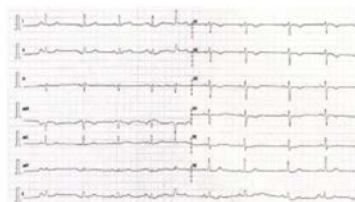
The patient was diagnosed with sick sinus syndrome. All reversible causes had been excluded; therefore a single chamber pacemaker was implanted in the right ventricle and set to VVI mode with hysteresis 50/60. A week later, she underwent pacemaker interrogation. The result showed 12.9% ventricular pacing with an average HR of 60-70 bpm. She complained of mild fatigue, so the pacemaker was switched to VVIR with rate modulation of 60-135 bpm. Afterwards, she reported feeling better.

Conclusion: We have presented a case of SSS in a patient under 70. Although unusual, SSS should be considered as a differential diagnosis, especially in patients with complaints of recurrent palpitations and syncope when other causes have been excluded. Thus, continuous HR and ECG monitoring can be helpful for establishing an accurate diagnosis.

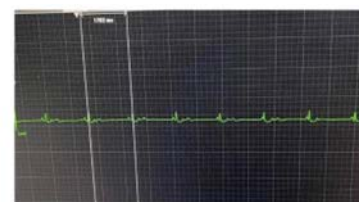Keywords: Sick sinus syndrome, syncope, palpitations.




A. Supraventricular tachycardia



B. Sinus bradycardia with ventricular rate of 50 bpm



C. Sinus activity with a 1783 ms pause and HR of 33 bpm



D. Tachy-brady syndrome

His-bundle pacing corrected complete right bundle block in patient with advanced heart failure

T. Nugrahaputra¹, G. Karwiky², C. Achmad³, M. Iqbal⁴

¹Faculty of Medicine, Universitas Padjadjaran, Cardiology and Vascular Medicine Department, Hasan Sadikin General Hospital, Bandung, Indonesia; ²Cardiology and Vascular Medicine Department, Hasan Sadikin General Hospital, Bandung, Indonesia; ³Cardiology and Vascular Medicine Department, Hasan Sadikin General Hospital, Bandung, Indonesia; ⁴Cardiology and Vascular Medicine Department, Hasan Sadikin General Hospital, Bandung, Indonesia

Background. Cardiac resynchronization therapy (CRT) is known to be effective in managing patient with left ventricular (LV) systolic dysfunction, left bundle branch block (LBBB), and heart failure. However, the benefits of biventricular pacing is limited in patients with complete right bundle branch block (CRBBB). Permanent His bundle pacing (HBP) has been used as an option for resynchronization in patient with complete CRBBB.

Case Illustration. 59-year-old male with ischemic cardiomyopathy and advanced heart failure was referred to tertiary hospital for his bundle pacing following multiple acute coronary syndrome and heart failure despite optimal medical therapy. Electrocardiogram (ECG) showed sinus rhythm with complete RBBB. Baseline echocardiography showed dilated left atrial (LA), LV, eccentric LV hypertrophy, reduced left ventricular ejection fraction (LVEF) 28% with regional wall motion abnormalities and aneurysm apical LV. Valves evaluation showed sclerotic aortic valve and mild aortic regurgitation (AR). Patient had percutaneous coronary intervention (PCI) at Left Anterior Descending (LAD) artery with chronic total occlusion (CTO) at distal LAD. Final EP study diagnosis were sinus rhythm with CRBBB, normal sinus node and AV nodal function, corrected QRS morphology with his bundle pacing. His bundle pacing was recommended for this patient. Primary outcomes were evaluated with ECG and echocardiography. ECG and echocardiography parameter were evaluated post HBP. ECG showed narrowing CRBBB from 154 ms to 120 ms. Improved LV/RV preejection time from 74 ms to 19 ms, septal-to-posterior wall delay (SPWD) from 260 ms to 220 ms, and improved LVEF from 28% to 29%.

Conclusion. HBP was associated with narrowing of QRS duration and LVEF improvement. Permanent HBP may be considered in patient indicated for CRT with RBBB and reduced LVEF.

Keyword: RBBB, His Bundle Pacing, Cardiac Resynchronization Therapy

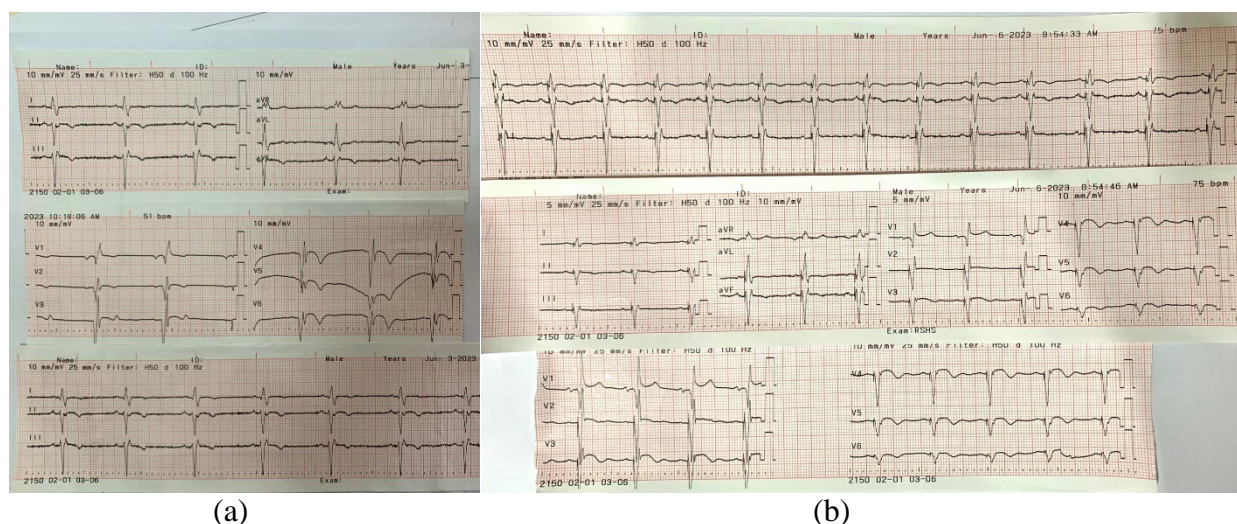


Figure.1 differences in the patient's ECG before (a) and after HBP (b), there is a narrowing of the QRS complex after HBP implantation

Is It Enough to Perform Slow Pathway Modification using 3D Electroanatomical Mapping to Prevent AV Block in Octogenarian? What did We Miss?

T. Oktavio¹, M.E. Santoso¹, S. Adiwinata¹, E.J. Gunawan², A. Handayani², B. Hartono², D. Larasati², M.Munawar².

¹Department of Cardiology and Vascular Medicine Sam Ratulangi University Prof. Dr. R.D. Kandou General Hospital Manado, Indonesia

²Department of Cardiology and Vascular Medicine Binawaluya Heart Hospital, Jakarta, Indonesia

Background: Slow pathway modification is the preferred ablation method for typical AVNRT. AV block may occur about 1-2.3%. Here we present a case of typical AVNRT ablation using 3D electroanatomical mapping with complication TAVB.

Case Illustration: A 86-year old female with palpitation since 2 years ago spontaneously terminated. X-ray showed cardiomegaly, echocardiography revealed normal heart chamber and ejection fraction, moderate aortic and mitral stenotic was found. Electrocardiography and electrophysiology study showed slow/fast AVNRT, PR interval 202 ms, AH interval 92 ms, HA interval 40 ms, AV conduction 2:1 was found. Ablation procedure using 4 mm non-irrigating catheter, marking of the His using Carto 3D. His site was marked, AV signal 1:3 and no his signal was found in ablation catheter, ablation was performed near CS ostium and 15.1 mm from His site. Unfortunately, TAVB was found in <10 second of RFA with 30 watt, 35°C, 40 second. 5 mg dexamethasone was administered, temporary pacemaker was implanted. The next two days, TAVB still exist so dual chamber permanent pacemaker was implanted.

Conclusion: AV block may appear as a direct damage to the AV node, displacement of the slow or fast pathway. In this case may be due to displacement of fast pathway. Even using 3D mapping, we need to use His catheter to calculate the A(H)-A(Md) interval to prevent the incidence of AV block.

Keywords: AVNRT ablation, AV block Slow pathway modification, 3D mapping AVNRT ablation

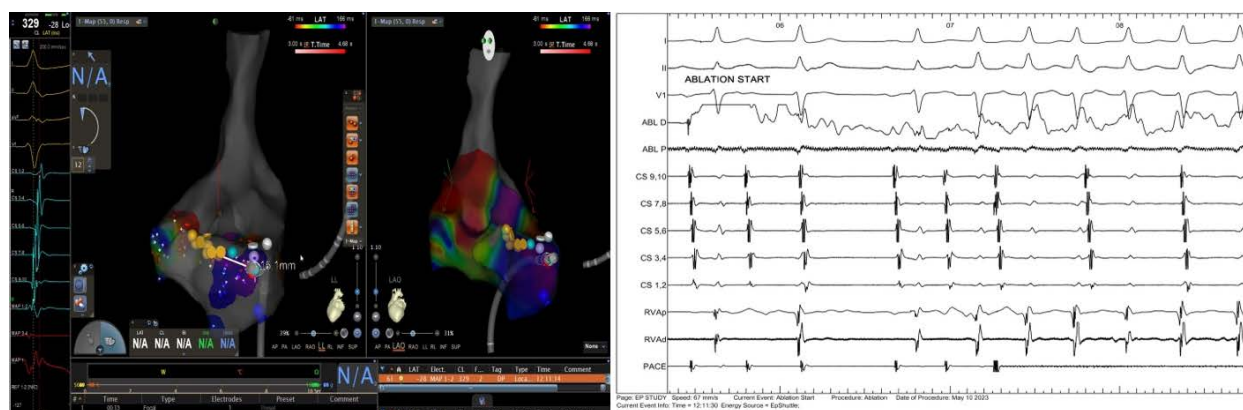

Figure 1. Carto 3D electroanatomical mapping showing distance from his to ablation site 15.1 mm, no his signal found in MAP catheter and AV dissociation was seen



Atrial Fibrillation in Spontaneous Intracerebral Hemorrhage

T. Rahmani, I. Aprianti Putri, M. Arief Rachman Kemal, N. Phalita Laksmi

National Brain Center, Jakarta, Indonesia. Faculty of Medicine, Universitas Airlangga, Surabaya, Indonesia

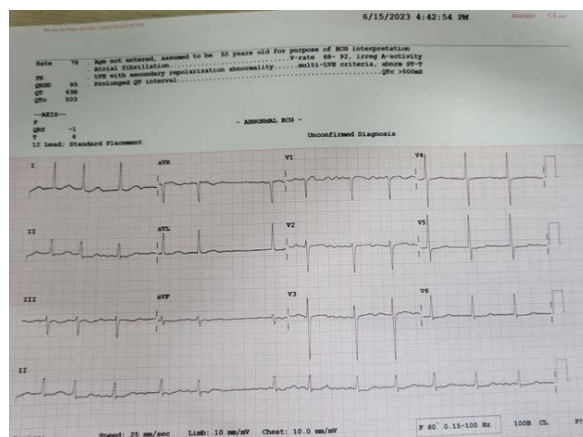
Background: Atrial fibrillation (AF) is a highly prevalent and important risk factor for cardioembolic ischaemic stroke. On the other hand, haemorrhagic stroke with atrial fibrillation more difficult to treat due to spontaneous bleeding due to high blood pressure or side effect of oral anticoagulation treatments. This case illustration present about hemorrhagic stroke with atrial fibrillation in National Brain Center of Jakarta.

Case Illustration: A man, 63 years old, admitted to ER with sudden left motoric weakness and tingling at the same side since 1 hour and 36 minutes before came to hospital. Patient has hypertension dan AF and diabetes type II without treatment properly. General examination shows blood pressure is 180/100 mmHg, heart rate 80x/minutes irregular rhythm, respiratory rate 20x/minutes with normal temperature. Neurological examination found with compos mentis, severe dysarthric, and left hemiparesis. NIHSS 18 MRS 3. Non Contrast brain CT Scan result was Intraparenchym haemorrhage volume 7,2cc in externa capsula to right thalamus extend to intraventricle.

Patient with haemorrhagic stroke with atrial fibrillation for this patient more related with high blood pressure. Patient got fibrynolytic and vitamin K for two weeks to absorb the bleeding. Patient treated with beta blocker and cordarone for his atrial fibrillation. Direct oral anticoagulant was given for his atrial fibrillation after four weeks within repeated non contrast brain CT scan to assess bleeding absorption.

Conclusion: Hemorrhagic stroke with atrial fibrillation is recommended for anticoagulant treatment after 2-4 weeks post stroke. Hypertension emergency is a cause for intracranial haemorrhage based on location due to chronic hypertension (basal ganglia, lobar, thalamic, pons, cerebellum). Rhythmic and rate control recommend for patient with anticoagulant treatment to prevent cardioembolic stroke.

Keywords: Atrial Fibrillation, Intracranial Haemorrhage, Oral Anti Coagulant



ECG shows arrhythmia

Progression from paroxysmal to long-standing persistent atrial fibrillation and the coexistence with atypical atrial flutter in an adult case of ventricular septal defect

V. A. N. Fatimah¹

¹Raffa Hospital, Cilacap, Indonesia

Background: In congenital heart disease, atrial fibrillation (AF) may arise as the result of atrial dilatation, atrial scar, sinus nodal dysfunction, and congenital conduction system abnormalities. It can be paroxysmal but its recurrence may trigger the progression to long-standing AF. AF can be concurrent with atrial flutter in almost 25% of patients. The development of atrial flutter may be preceded by the formation of functional line of block which occurs during AF of variable conduction. It also may arise from the exacerbation of lung disease.

Case Illustration: A 24 years old female with a history of heart failure from ventricular septal defect (VSD) presented to the emergency department with fever that lasted for 1 week, shortness of breath, and palpitation. About 10 months prior, she experienced paroxysmal AF which converted back to normal sinus rhythm after kalium correction, rhythm and rate control. She had been taking 20mg tid sildenafil, 4mg daily candesartan, 12.5mg daily spironolactone, 0.125mg daily digoxin, 5mg daily bisoprolol, and 20mg daily furosemide since then. Her electrocardiogram at admission demonstrated atrial fibrillation (AF) coexisting with atypical atrial flutter. The heart rate was 88 beats/minute. On the thorax radiograph, consolidation was noted at the middle part of the right lung. She was hospitalized and treated with antibiotics. The resolution of pneumonia resulted in atrial flutter cessation even though the AF persisted.

Conclusion: This case depicted the progression of paroxysmal to persistent AF in an adult VSD and the coexistence with atypical atrial flutter. The occurrence of persistent AF suggests that paroxysmal AF might reoccur frequently. It was assumed that pneumonia triggered the episode of AF facilitating the development of atrial flutter.

Keywords: persistent atrial fibrillation, atrial fibrillation, adult ventricular septal defect.

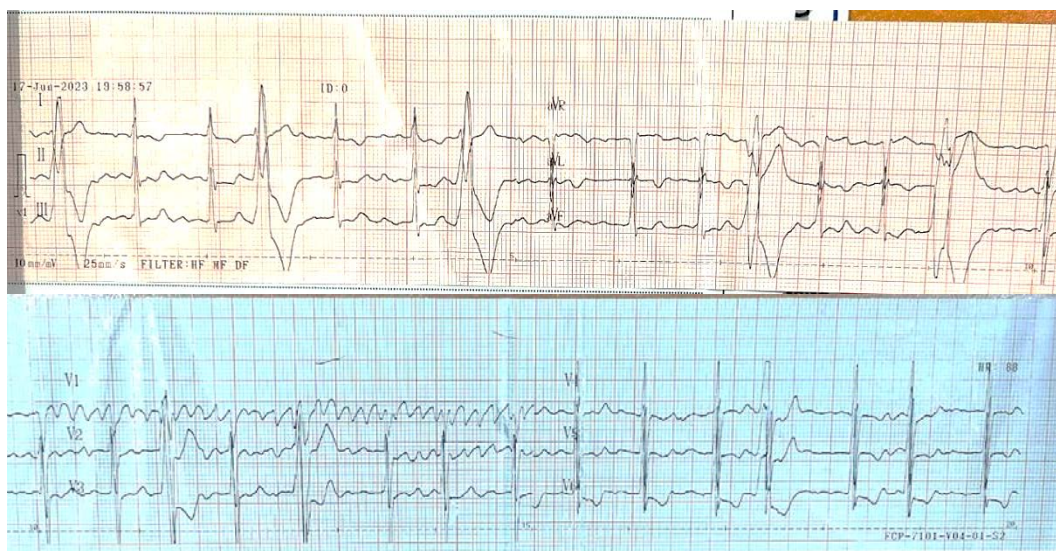


Figure showing the ECG of AF coexisting with atypical atrial flutter in an adult case of VSD

An Unconventional Twist: Paradoxical Ventriculophasic Sinus Arrhythmia Unraveled during 2:1 Atrioventricular Block

W. Mubarak¹, D. Nugraha¹, I.P. Farissa¹, A.Y.A.B Mochtar², P. Ardianto²

¹Faculty of Medicine, Diponegoro University, Semarang, Indonesia; ²Departement Cardiology and Vascular Medicine, Dr. Kariadi General Hospital Semarang, Indonesia

Background: Ventriculophasic sinus arrhythmia is a phenomenon commonly observed in patients with complete atrioventricular (AV) block. Typically, the PP intervals which contain a QRS complex are shorter > 3% than the PP intervals which do not contain it. This phenomenon is present in more than 40% of cases with complete AV block and less common in the setting of second-degree AV block.

Case Illustration: A 71-year-old woman was referred to Kariadi Hospital for further evaluation AV block. She complained of easily fatigue and near-syncope. She was not receiving any medications with AV node-blocking effects. Blood pressure was 110/70 mmHg, heart rate was 40 beats per minute, and the oxygen saturation was normal. The ECG showed sinus rhythm with high degree AV block with 2:1 AV conduction. Note that the PP intervals containing the QRS complex are shorter (680 ms) than the PP intervals without a QRS complex (760 ms) which is typically for paradoxical ventriculophasic sinus arrhythmia. The patient received a dual-chamber pacemaker for symptomatic high-grade AV block. The potential mechanism is by two-phase chronotropic effects proposed by Rosenbaum and Lepschkin. The positive chronotropic (accelerating) that is related to early appearance of a P wave following a QRS complex then shortening of the PP interval which contains a QRS complex and a negative chronotropic (decelerating) may result in the next longer PP interval without an intervening QRS complex.

Conclusion: Ventriculophasic sinus arrhythmia is a common finding in the presence of complete heart block. Its mechanism is not fully understood. Paradoxical ventriculophasic sinus arrhythmia during 2:1 atrioventricular block has not been described in the literature so far. Our particular case can also be explained by two-phase chronotropic effect mechanism.

Keywords: Ventriculophasic sinus arrhythmia, high degree AV block

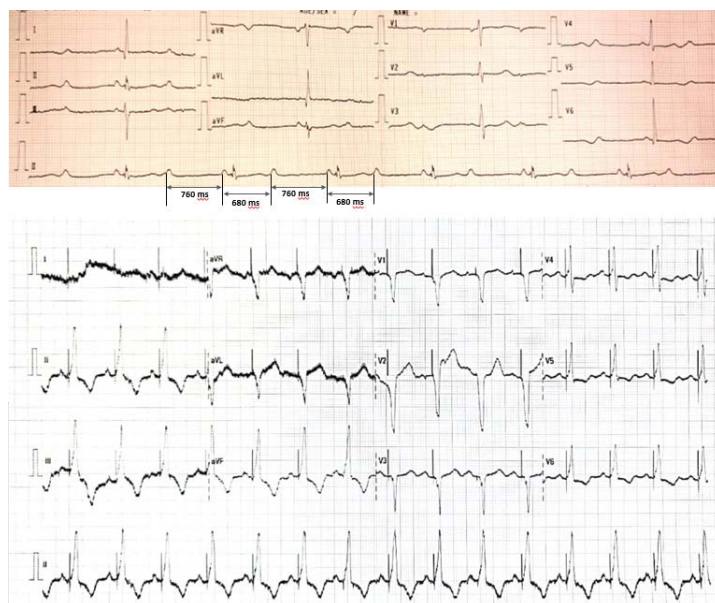


Figure 1. The 12 lead electrocardiogram pre and post a dual-chamber permanent pacemaker

Supraventricular Tachycardia in Pregnancy: The Necessity of Multidisciplinary Approach

Y.A. Fikri¹, E.P.B. Mulia², F.W. Nugroho²

¹General Practitioner, dr. R. Soetrasno Regional General Hospital, Rembang, Central Java

²Department of Cardiology and Vascular Medicine, dr. R. Soetrasno Regional General Hospital, Rembang, Central Java

Background: Hemodynamic and hormonal changes in pregnancy may contribute to increased cardiac output which subsequently stretches the myocardial tissues, predisposing pregnant women to arrhythmias. Supraventricular tachycardia (SVT) is one of the commonest forms of arrhythmia in pregnancy. However, it may pose a difficult clinical challenge due to the lack of studies and case report. Here we present a case of supraventricular tachycardia in a gravid woman.

Case Illustration: A 35-year-old woman, G2P1A0 was admitted to our emergency department with shortness of breath and palpitation. The symptoms had worsened for the last 10 days prior to admission. She had history of one previous normal vaginal delivery 5 years back without any complication or similar symptoms. The patient was also diagnosed with active pulmonary TB and hyperthyroidism and had routinely been taking her medication since 30 days prior. Her vital signs showed hemodynamic stability (BP 110/70 mmHg), albeit with a pulse rate of 210/min with electrocardiogram revealing the presence of SVT with short RP interval. Routine laboratory examination revealed leukocytosis (16,500/ μ L) and mild hypokalemia (3.11 mEq/L), while her chest X-ray showed signs of pulmonary edema. The patient was treated accordingly with IV diltiazem 15 mg and oral diltiazem 1x100 mg, along with infusion of potassium chloride 50 mEq, and she was subsequently reverted to normal sinus rhythm. The patient was also consulted to pulmonology and internal medicine for the management of concomitant pulmonary TB and hyperthyroidism, and she was regularly followed up by our obstetrician for maternal and fetal monitoring. Following the stabilization of heart rate, considering the existing pulmonary problem in this patient, she was discharged on verapamil 240 mg QD. She was following up regularly until her peripartum period.

Conclusion: A multidisciplinary approach, cautious use of medication, and proper maternal and fetal monitoring are the key for successful management of SVT in pregnancy.

Keywords: supraventricular tachycardia, pregnancy

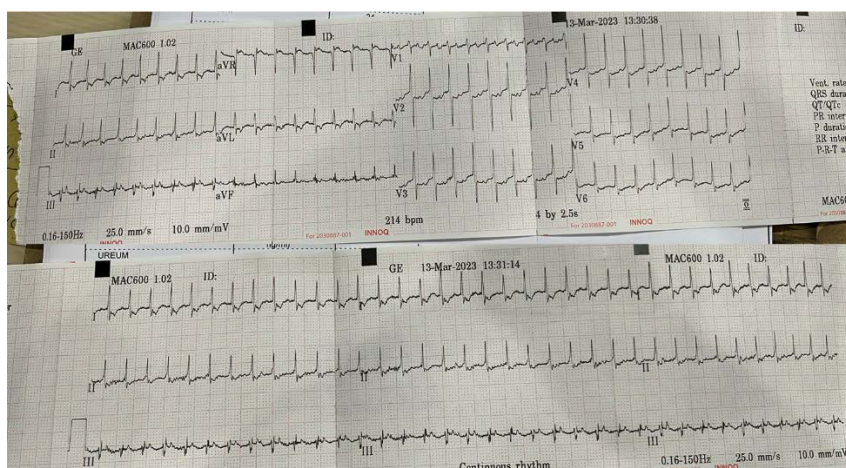


Figure 1. Electrocardiogram on admission revealed supraventricular tachycardia with short RP interval



Stop the MAD-ness: 3D Ablation of Mitral Annular Disjunction and Arrhythmic Mitral Valve Prolapse

Y. Adani¹, F. Hidayati¹, E. Maharani¹

¹Department of Cardiology and Vascular Medicine, Dr Sardjito General Hospital/ Universitas Gadjah Mada, Yogyakarta, Indonesia

Background: Mitral annular disjunction (MAD) is an abnormal displacement of the mitral valve leaflet onto the left atrial wall and is commonly found in patients with mitral valve prolapse (MVP). MAD plays a critical role which lead to increased mechanical stretch and subsequent fibrosis mainly in the papillary muscles, forming the arrhythmogenic substrate. A premature ventricular contraction (PVC) triggered ventricular fibrillation being the main mechanism of sudden cardiac death (SCD).

Case Illustration:

Case 1

A 35-year-old man diagnosed with MVP presented with occasional palpitations and mild chest discomfort. Holter monitoring revealed PVC burden of 11% with multifocal PVC (right ventricular outflow tract dominant). Echocardiography showed moderate mitral regurgitation with MAD with normal left ventricle systolic function. Cardiac magnetic resonance (CMR) confirmed mitral valve prolapse with MAD and mitral regurgitation. Electrophysiology study was performed and a successful 3D ablation of moderator band origin PVC. Following the procedure, PVC burden decreased to <1%.

Case 2

A 32-year-old woman with a history of MVP presented with two episodes of non-sustained ventricular tachycardia during treadmill test on peak exercise and recovery phase. Holter recording revealed PVC burden 4% with multifocal PVC (right bundle branch morphology, superior axis, transition zone in V4). Echocardiography showed bileaflet MVP without mitral regurgitation and MAD. CMR confirmed the separation between posterior mitral valve leaflet to basal left ventricle. Electrophysiology study concluded the ventricular tachycardia origin from posterior papillary muscle origin and 3D ablation was done successfully. Evaluation post-ablation showed PVC burden decreased significantly and symptoms was claimed to be improved.

Conclusion: MVP combined with MAD is a pathological condition predisposing to life-threatening ventricular arrhythmias and sudden death. Ablation in these patients was safe and improved arrhythmia control. Catheter ablation of ventricular arrhythmia is efficacious to eliminate PVC therefore decrease SCD risk.

Keywords: 3D catheter ablation, mitral annular disjunction, mitral valve prolapse, premature ventricular complex, sudden cardiac death, ventricular tachycardia



**Orthodromic Atrioventricular Reentrant Tachycardia Mimicking Ventricular Tachycardia :
Revisiting Coumel's Law Phenomenon**

Y. Aljaidi, F. Ahmad, S.A. Manurung, C. Rith,

D.Y. Hermanto, S.B. Raharjo, D.A. Hanafy, Y. Yuniadi

Division of Arrhythmia, Department of Cardiology and Vascular Medicine,
Faculty of Medicine Universitas Indonesia / National Cardiovascular Center Harapan Kita,
Jakarta, Indonesia

Background: The differentiation between ventricular tachycardia (VT) and broad-complex supraventricular tachycardia can be extremely difficult. Atrioventricular reentrant tachycardia (AVRT), both antidromic and orthodromic could be considered as one of differential diagnosis.

Case Illustration: We report a case of 26-year-old female with concealed left posterolateral accessory pathway and episodes of recurrent palpitation due to orthodromic AVRT. During the ablation procedure, sustained clinical tachyarrhythmia was induced with tachycardia cycle length (TCL) 300 ms, VA interval 120 ms and narrow QRS (QRS duration 109 ms). It showed the most VA fusion at coronary sinus 3-4 (left posterolateral AP), right ventricular overdrive pacing maneuver showed VAV response with PPI-TCL < 115 ms, therefore the diagnosis was orthodromic AVRT with left posterolateral AP. Orthodromic AVRT spontaneously changed to wide complex tachycardia (LBBB-pattern morphology) with TCL 320 ms and VA interval 132 ms, with no VA fusion was seen at left posterolateral mitral annulus, confirming the diagnosis of left AVRT (ipsilateral), according to Coumel's law. Successful radiofrequency ablation were delivered to left posterolateral mitral annulus area during sinus rhythm.

Conclusion: Complete electrophysiology study should be performed in a doubt of correct diagnosis, including in difficult wide-complex tachycardia cases. The phenomenon of Coumel's law can facilitate identification and localization of a concealed accessory pathway during electrophysiology study.

Keywords: atrioventricular reentrant tachycardia, concealed accessory pathway, Coumel's law



A rare case of arrhythmia and Advanced Heart Failure in LVNC

Y.C. Nuraini¹, Irnizarifka², T.H. Chau¹, H. Arifianto²

¹Universitas Sebelas Maret Hospital, Sukoharjo, Central Java

²HF Clinic Team of Universitas Sebelas Maret Hospital, Dept. Cardiology and Vascular Medicine
UNS

Background: Left Ventricular noncompaction (LVNC) is a rare cardiomyopathy characterized by a thin, compacted epicardial and a noncompacted endocardial layer with trabeculations and recesses that communicate with left ventricular cavity. Some literatures explained about the appearance of arrhythmia in LVNC that is considered to be caused by immature development of cardiac conduction system, but others proofed that it does not origin from non-compaction area. PVCs occur in 70-95% of patient with heart failure and multifocal PVCs may be predictors of more malignant arrhythmias and sudden cardiac death.

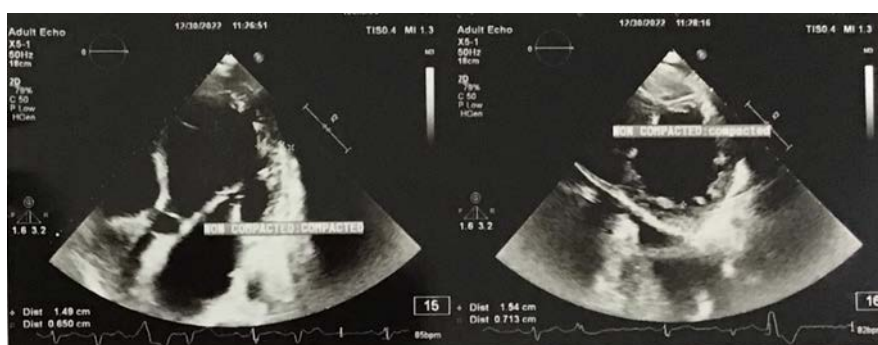
Case Illustration: A 56 year old male was hospitalized with dyspnoea, ascites, palpitation, and peripheral edema for the past 3 weeks. Physical examination revealed pulmonary rales and dullness at the base of pulmo, increasing JVP, murmur at tricuspid valve, and persistent NYHA fc.III. Rontgen thorax interpretation was bronchopneumonia, pleural effusion dextra, edema pulmonum, and cardiomegaly. Patient then diagnosed with Advanced Heart Failure.

Echocardiography showed decreasing LVEF 17.1% (Simpson), global hypokinetic with severe hypokinetic at basal-mid septal, and non-compaction segment on mid-apical lateral, anterolateral and inferolateral with ratio 2.3. It showed LVH eccentric with all chamber dilatation and moderate tricuspid regurgitation. Electrocardiography recorded atrial fibrillation, multifocal premature ventricular contraction at different location, those were at right ventricular origin, anteroseptal RVOT, tricuspid valve free wall and there was left bundle branch block.

Patient then received ARNI 100mg bid, β -blocker 6.25mg bid, SGLT2i 10mg od, MRA 25mg od, tolvaptan 15mg od, and loop diuretic 40mg od. Patient was intolerance with β -blocker and developed into symptomatic bradycardia with premature atrial contraction.

Conclusion: There is no therapy specific for treatment of LVNC, but arrhythmia and AdHF should be treated based on each recommendations. Arrhythmia in this case, supposed to be treated with CSP or ICD to prevent worsening of heart failure and sudden cardiac death.

Keywords: Advanced Heart Failure, Arrhythmia, Left Ventricular Non-Compaction Cardiomyopathy (LVNC)



Anemia as A Reversible Cause of Periodic Tachy-Brady Syndrome: A Case Report

Y.G.E. Suprana¹, J. Probokusumo²

¹ Brebes Regional General Hospital, Brebes, Central Java, Indonesia; ² Department of Cardiology and Vascular Medicine, Brebes Regional General Hospital, Brebes, Central Java, Indonesia

Background: Tachy-Brady Syndrome is usually occur in older adults and at least 50 percent of patients with sinus node dysfunction develop tachy-brady syndrome. It can be caused by intrinsic pathology (heart failure, atrial tachyarrhythmias, endocarditis) and external causes (vasovagal syncope, metabolic derangement, etc).

Case Illustration: A 67 years old male came to the emergency room with shortness of breath. The patient also suffered from chronic headache with recurrent syncope in 1-year. Initial blood pressure was 164/58 mmHg, irregular heartbeat of 90-110 beats/min, tachypnea, and normal temperature. Electrocardiography (ECG) showed an episode of atrial flutter followed by periodic sinus paused (tachy-brady syndrome), and also a ventricular premature contraction wave. Transthoracic Echocardiography showed severe mitral regurgitation and moderate tricuspid regurgitation with high probability of pulmonary hypertension, with ejection fraction 51% and no vegetation. Complete blood count revealed the hemoglobin concentration was decreasing to 6.8 g/dL and his blood smear examination showed microcytic and hypochromic anemia. Electrolyte, liver, and renal function test were normal. After receiving antiarrhythmic therapy and supportive treatment for anemia which was transfusion packed-red-cells, the hemoglobin was increasing to 10.3 g/dl, symptoms gradually disappeared and the ECG was changed in day 2 admission to normal sinus rhythm, normal axis and no ST-T changed. Somehow, in day 3 follow up on ECG showed normal sinus rhythm with p-pulmonale and dynamic ST-T changed (T inversion from V2-V5). The patient was planned to be referred to tertiary hospital for further investigation due to limited facility in our hospital to find the etiology of the disease.

Conclusion: There are several reversible causes in periodic tachy-brady syndrome that we can find in this patient such as anemia, mitral regurgitation, and infective endocarditis. Further investigation needed to find the clinical entity of this disease and treat the disease properly.

Keywords: tachy-brady syndrome, sinus node dysfunction, atrial flutter, anemia

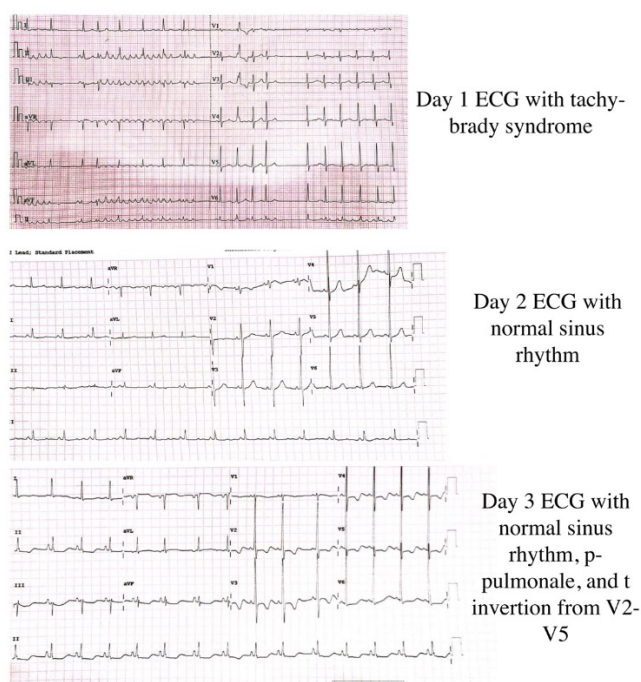


Figure 1. Electrocardiography follows up on the patient



**NSTE-ACS Following Ablation of Idiopathic RVOT PVC in Young Woman with Suspected
Fibromuscular Dysplasia : a Rare Case**

Y. Muya¹, H. E. Rasyid²

¹ Faculty of Medicine, Andalas University, West Sumatera, Indonesia.

² Cardiology and Vascular Medicine, M. Djamil Hospital, West Sumatera, Indonesia.

Background: Radiofrequency ablation was a prefer technique to treat idiopathic RVOT PVC in young patient. Although rarely founded, complication related to ablation procedure include: hematome in site of puncture, vascular thrombosis, heart block and tamponade. Acute coronary syndrome was a very rare complication since these procedure did not reach coronary artery area. Fibromuscular dysplasia is an abnormal development of wall of arteries that can cause narrowing of the vessel, include coronary arteries.

Case Illustration: A 31 years old woman with history of idiopathic RVOT PVC and unresponsive with medication, had a radiofrequency ablation procedure of the antero-septal RVOT area. During the procedure, she developed worsened chest pain that is not relieved by analgetics. Electrocardiogram showed ST segment depression in the inferior leads. Coronary angiography showed subtotal occlusion at mid left anterior descending artery, she performed a drug eluting stenting that was placed in the proximal mid left anterior descending artery. The symtoms resolved and follow up echocardiogram showed normal left ventricular systolic and diastolic function with no regional wall motion abnormality. Due to the absence of thrombus during coronary angiography procedure, there was a suspicion of abnormality of the coronary artery muscle. The patient was suspected to fibromuscular dysplasia by neurologist and performed further investigation for diagnosis.

Conclusion: These case raised the alarm of electrophysiologist who performed radiofrequency ablation to treat arrhythmia, in terms of non obstructive miocardial infarction must be considered as one of rare but serious complications.

Keywords: Premature ventricular cotraction, radiofrequency catheter ablation, miocard infarction,

Sinoatrial Node Dysfunction Resulting Paradoxical Bradycardia Following Blood Loss: A Woman in Jeopardy

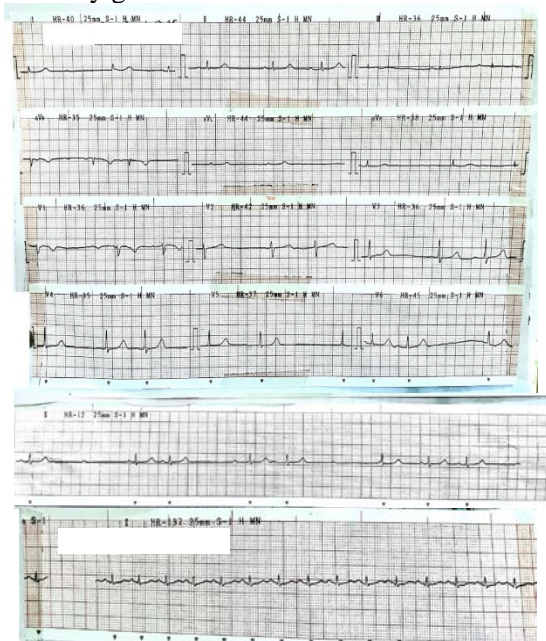
Y. N. Afifah¹, G. B. Putra²

¹General Practitioner, PKU Muhammadiyah Gamping Hospital, Yogyakarta, Indonesia; ²Faculty of Medicine, Universitas Muhammadiyah Yogyakarta, Yogyakarta, Indonesia

Background: Sinoatrial Node Dysfunction (SND) can manifest as symptomatic bradycardia and sinus pauses due to multifactorial factors, including hypervagotonia. Hypervagotonic SND can be presumed by its association with symptoms resulting from increased vagal tone and temporary bradycardia. Atropine, by blocking acetylcholine action at parasympathetic sites, can eliminate the electrophysiological abnormalities of the sinus node. In certain conditions such as haemorrhagic shock, bradycardia requires exploration for haemorrhage and resuscitation, as tachycardia is the expected physiological response in such situations. This phenomenon is referred to as paradoxical bradycardia. Paradoxical bradycardia following blood loss may be associated to an increase in efferent branches of vagal nerve activity, in order to optimize ventricular filling time.

Case Illustration: A 29-year-old primigravida experienced haemorrhagic shock and severe anaemia (3.3 g/dl) because of blood loss due to ruptured ectopic pregnancy. After undergoing an emergency laparotomy and salpingectomy, she was monitored in the intensive care unit. She lost 1000 cc of blood during surgery and was resuscitated. Hours later, she complained of vomiting and dizziness. Her blood pressure measured 99/62 on 0.1 mcg/kg/min norepinephrine, 48 bpm heart rate, and normal oxygen saturation. Her physical examination was unremarkable with normal lochia. Electrolytes were within normal limits, with 5.6 g/dl haemoglobin level, thrombocytopenia (114.000), and albuminemia (2.6). Her electrocardiography revealed varying prolonged PR intervals followed by dropped beats suggesting AV nodal block. QRS duration and axis were normal. After receiving 0.5 mg of atropine sulphate, the rhythm changed to sinus tachycardia. Her echocardiography showed preserved ejection fraction without structural abnormalities. During hospitalization, she received 6 packed red blood cells. Pacemaker was not provided to her given the resolution of symptoms and AV block.

Conclusion: Hypervagotonia and haemorrhagic shock are reversible causes of SND. Atropine may be administered to SND patient with moderate to severe symptoms, alongside with resuscitation for haemorrhagic shock. Prompt identification and management of any reversible causes of SND are crucial and may give a favourable outcome.



Keywords: bradycardia, sinus node dysfunction, anaemia, haemorrhagic shock



A Rare Case of Cardio-hepatorenal Syndrome After Permanent Pacemaker Implantation

¹Y.Newary, ²C.D.Aristiana, ³E.J.Gunawan, ⁴D.A.Munawar, ⁵D.L.Munawar, ⁶M.Munawar

¹*Binawaluya Heart Hospital, Jakarta, Indonesia*

Background: Cardio-hepatorenal syndrome after pacemaker implantation is a rare post-cardiac injury syndrome condition. Pericardial effusion is one of the complications following insertion of a pacemaker due to perforation is reportedly between 0.5% and 2% but the incidence of cardiohepatorenal syndromes is still undocumented. It could involve cardinal pathophysiologic pathways, namely neurohormonal activation and endothelial dysfunction with pathophysiologic pathways linking the liver, heart, and kidney. The patient's unusual presentation, examinations and treatment for cardio-hepatorenal syndrome are discussed below.

Case Illustration: A 47-year-old man with atrial fibrillation presented in our emergency department with sudden onset dyspnea. Patient has been performed permanent pacemaker with left bundle pacing a week earlier. On physical examination, he was tachycardia. ECG demonstrated normal pacing rhythm with LBBB pattern. Echocardiography showed pericardial effusion with maximal size at apex about 19mm and right atrial collapse but no other symptoms of cardiac tamponade. The blood tests of patient revealed high INR, elevated hepatic marker with up to 10 times increase of AST and ALT levels and also higher creatinine level if we compared with the blood test on the day of procedure, but still normal result of NTproBNP. The patient ultimately underwent pericardiosintesis. We found on chest CT that the sheath tip was near the edge of right atrium made it as a risk factor for mechanical complication along with high INR. Evaluation of cardiac function was assessed daily with generally good result and the renal function returned to normal in 3 days after tapping procedure unlike hepatic marker needed longer time which in 9 days.

Conclusion: It is noteworthy that the any procedures of cardiac have many factors affected to other conditions which may turn more comorbidity to other systems. Interaction between the heart, kidney and liver in the setting of post cardiac pacemaker complication should be closely monitored since the cardiac condition after the procedure may be unusual and complex.

Keywords: cardiohepatorenal syndrome, pacemaker, pericardial effusion

ATRIAL FLUTTER WITH 1:1 CONDUCTION WITH WOLFF-PARKINSON-WHITE SYNDROME IN ATRIAL SEPTAL DEFECT PATIENT : THE DYNAMIC DUO

Y.P. Ardelia¹, E. Maharani², F. Hidayati²

¹Resident of Cardiology and Vascular Medicine, Gadjah Mada University/ Sardjito General Hospital, Yogyakarta

²Staff Department of Cardiology and Vascular Medicine, Faculty of Medicine, Public Health and Nursing Gadjah Mada University Sardjito General Hospital, Yogyakarta

Background: Atrial septal defect (ASD) have left-to-right shunt and primarily right-sided volume overload that leads to atrial remodeling that may predispose patients to atrial tachyarrhythmias and conduction disorders. The most common supraventricular arrhythmia in ASD patient are atrial flutter and atrial fibrillation. However, the presence of ASD may also disrupt the normal development of the electrical pathways leading to the formation of an accessory pathway characteristic of *Wolff-Parkinson-White* (WPW) syndrome, although relatively rare. Preexcitation syndromes, such as WPW syndrome, frequently cause supraventricular tachydysrhythmias, most commonly, atrioventricular reciprocating tachycardia and atrial fibrillation. Atrial flutter with 1:1 atrioventricular conduction and an accessory pathway is an uncommon presentation of Wolff-Parkinson-White syndrome not previously reported in the literature.

Case Illustration : A 43-year-old man arrived at the emergency room complaining of palpitations and shortness of breath. The patient has a history of secundum atrial septal defect with pulmonary hypertension. An electrocardiogram revealed narrow QRS tachycardia with a regular rate of 250-300 bpm and blood pressure was 60/40 mmHg. Electrocardiogram showed long RP supraventricular tachycardia (SVT) which accounts as atrial flutter with 1:1 conduction. Hence, electrical cardioversion was performed due to unstable hemodynamic. The rhythm returns to sinus rhythm with preexcitation at a heart rate of 111 bpm and blood pressure went normal after electrical cardioversion.

Conclusion : Double burden of tachyarrhythmia such as atrial flutter with 1:1 conduction in conjunction with preexcitation is rarely reported in the cardiology literature, especially in atrial septal defect. The presence of atrial flutter with 1:1 conduction such as in this case, a patient must have both an accessory pathway with an extremely short refractory period and a slow atrial flutter. Electrophysiology study and ablation should be considered prior to device closure or surgical repair of the ASD. For instance, atrial flutter with preexcitation conduction requires specific consideration of medication choice to avoid potential degeneration into ventricular arrhythmias.

Keywords: preexcitation; Wolff-Parkinson-White syndrome; atrial flutter; narrow complex tachycardia; accessory pathway, atrial septal defect

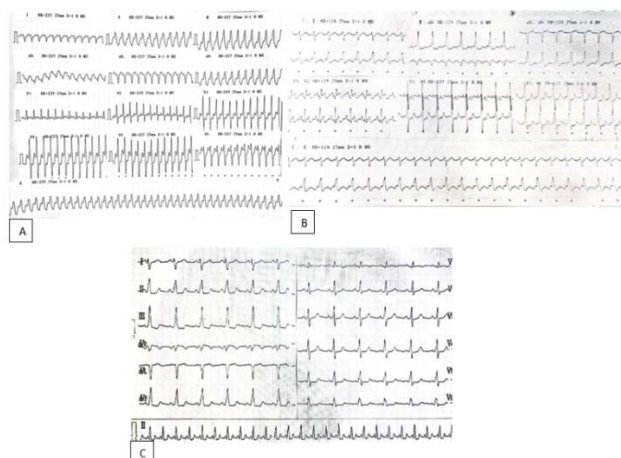


Figure 1. (A) Twelve-lead electrocardiogram (ECG) at the ER showed atrial flutter with 1:1 conduction. (B) Twelve-lead ECG obtained in the ward when patient had recurrent atrial flutter with 2:1 conduction. (C) ECG after electrical cardioversion showed normal sinus rhythm with pre-excitation.

**Running with Run VT: A Very Rare Case of Cathecolaminergic Polymorphic Ventricular
Tachycardia**

Z. Z. Z. Jayadisastra¹, E. Maharani², F. Hidayati²

¹Cardiology Resident, Department of Cardiology and Vascular Medicine, Faculty of Medicine, Public Health, and Nursery, Gadjah Mada University; ² Department of Cardiology and Vascular Medicine, Faculty of Medicine, Public Health, and Nursery, Gadjah Mada University

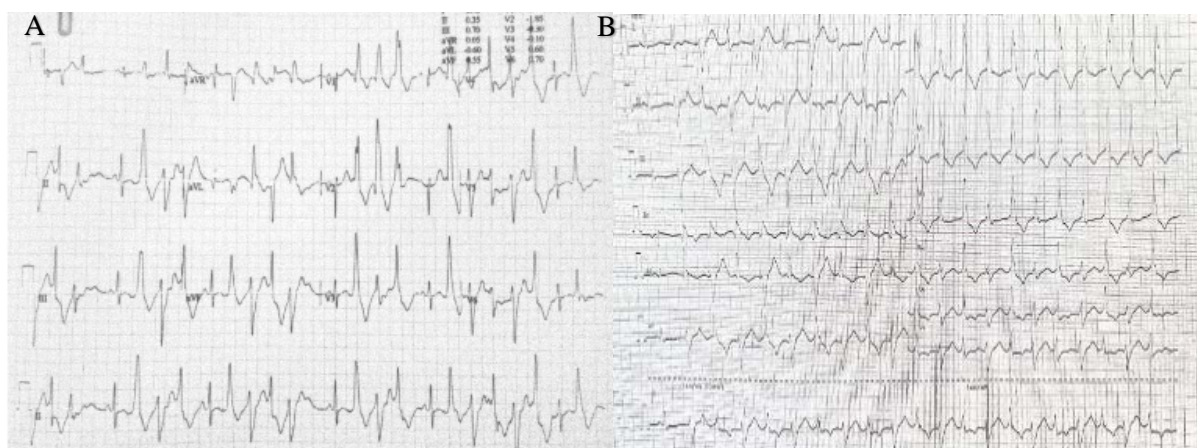
Background: Cathecolaminergic polymorphic ventricular tachycardia (CPVT) is a rare familial tachyarrhythmia that is related to gene mutation (RYR2 or CASQ2) that presents with sudden exercise-emotion-triggered syncope or cardiac arrest in patient with normal heart structure. Its electrocardiogram (ECG) showed sinus bradycardia and normal QTc in resting and bidirectional and/or polymorphic while in CPVT.

Case Illustration: We report a case of mildly symptomatic twenty years old patient with palpitation in exercise and history of recurrent syncope irrespective of activity level. Initial electrocardiogram (ECG) showed frequent ventricular premature contraction (VPC) during medical check up. Further evaluation with holter showed biphasic ventricular tachycardia (VT) during mild and vigorous activities. Treadmill test was used to further investigate the cause and it showed bigemini VPC during the initiation phase and the peak phase of exercise then diminished in recovery phase. Adrenal abnormalities was excluded using abdominal computerized tomography scan with contrast. Therefore, those investigations confirmed our diagnosis of CPVT in this patient. The patient then administered routine daily dose of beta-blocker as therapy and periodically evaluated using holter monitoring.

Conclusion: This case is a rare and easily missed case with most presented in children and young adults, therefore any symptoms of arrhythmia in these age groups should be evaluated extensively to rule out cardiac arrhythmia.

Keywords: cathecolaminergic polymorphic ventricular tachycardia, syncope, palpitation, young adult, children, pediatric, sudden cardiac

Figure 1. Patient's ECG in multiple conditions. 1A: Patient's ECG during Treadmill Test 1B: Patient's



ECG in outpatient clinic

Frequent PVC as a Manifestation of SA Exit Block:

Sulfas Atropine Trial as a Simple Method Diagnostic at Rural Area

A.P.H. Ferdianthi¹, I.M.P.S. Antara¹, J.H.M.H. Manurung²

¹Division of Arrhythmia and Electrophysiology, Department of Cardiology and Vascular Medicine, Faculty of Medicine Udayana University, Prof Dr. dr. I.G.N.G. Ngoerah Hospital, Denpasar, Indonesia;

¹Department of Cardiology and Vascular Medicine, Provita-Jayapura Hospital, Papua, Indonesia

Background

Arrhythmia is a disturbance of heart rhythm that caused by disturbance in the electrical impulses. Premature Ventricular Complex (PVC) is one of the most common arrhythmia, with various underlying causes, one of which is the condition of SA exit block. Understanding of the underlying cause will determine the proper choice of therapy.

Case Illustration

A 40 yo female patient, complained of palpitation that goes on and off since 3 months ago. Palpitation usually come after punch like sensation in her chest. Physical examination found high blood pressure and irregular heart beat from auscultation. Several ECG examination showed PVC frequent with episodes of bigeminy, trigeminy, and couplet. Chest x-ray, echocardiography, and coronary angiography examination were within normal limit. Patient was treated with antihypertension and beta blocker. During hospitalization, the frequent of PVC getting worse after beta blocker administration, therefore the dose was reduced in half. PVC still present but slightly decreased. Unfortunately there was no Holter device available to monitoring the burden of PVC. The first though was planned to referred patient to EP study and Ablation for the ectopic foci. However, according to the history of baseline bradycardia and PVC burden decreased as long as the reduction of beta blocker, than other possibilities are suspected including the existence of SA exit block. Other modality to assessed the possibility were cessation of beta blocker and Sulfas Atropine (SA) trial, as the hypothesis was the bradycardia causing inhibition of overdrive suppression of ectopic foci for PVC. During SA injection to maximum 3 mg IV, the heart rate was increased, and PVC burden was significantly decreased, making conclusion of SA exit block existence more likely. The goal therapy in this case was switch to Permanent Pacemaker (PPM) implantation.

Conclusion

Arrhythmia is sometimes challenging, especially in rural area without proper tools. Therefore, method to utilize existing resources is needed. Management therapy that usually done for cases of ectopic foci of PVC is EP study and ablation, however in this case, due to the expectation of frequent PVC as the manifestation of SA exit block, than management of choice was PPM implantation.

Keyword: *Frequent PVC, SA exit block, Sulfas atropine trial, PPM implantation.*

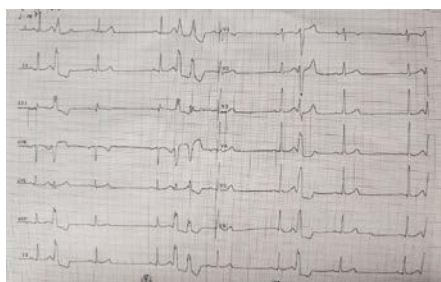


Figure 1. ECG on admission

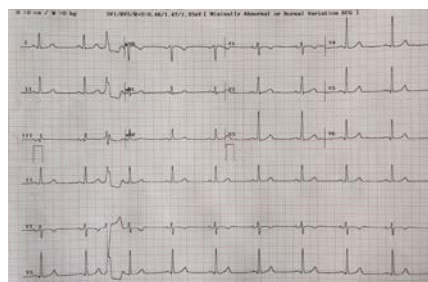


Figure 2. ECG during SA trial



**The 10th Annual
Scientific Meeting**
InaHRS 2023



**Indonesian Journal of
Cardiology**

Indonesian J Cardiol 2023;43:suppl_B
pISSN: 2830-3105 / eISSN: 2964-7304
doi: 10.30701/ijc.1565