



Indonesian Journal of Cardiology

An Official Publication of the Indonesia Heart Association

Volume 47, Suppl_A, 2026

Proudly presents

The 12th Annual Scientific Meeting InaHRS 2025

Case Report Abstracts

This supplement consists of abstracts presented at:

The 12th Annual Scientific Meeting InaHRS 2025, held September 11–13, 2025, at Raffles Jakarta, Jakarta, Indonesia.

The 12th Annual Scientific Meeting InaHRS 2025 is supported by the Indonesian Heart Rhythm Society (InaHRS).

This supplement is published through the collaboration and mutual agreement between the Annual Scientific Meeting InaHRS 2025 and the Indonesian Journal of Cardiology (IJC). The abstracts and cases are being reprinted without journal editorial review. The opinions expressed in this supplement are those of the authors and are not attributable to the publisher, editor, or editorial board of the Indonesian Journal of Cardiology.

The 12th
Annual Scientific Meeting
InaHRS 2025



Indonesian Journal of Cardiology

Indonesian J Cardiol 2026;47:suppl_A

pISSN: 2830-3105 / eISSN: 2964-7304

doi: 10.30701/ijc.2126

The Indonesian Journal of Cardiology and the Scientific Committee of The 12th Annual Scientific Meeting InaHRS would like to express our appreciation to all the Abstract Reviewers for their dedication and time.

Abstracts Reviewers

Anggia Chairuddin Lubis

Mohammad Iqbal

Alexander Edo Tondas

Dian Andina Munawar

Beny Hartono

I Made Putra Swi Antara

Yoga Waranugraha

[12INAHRS-CR1]

Cavo-Tricuspid-Isthmus dependent Atrial Flutter Ablation in the Heart with Giant Eustachian Valve appears as Cor Triatriatum Dexter

ARB Sitorus^{1,2}, WS Chee², AR bin Abd Ghani²

¹Department of Cardiology and Vascular Medicine, Faculty of Medicine, Hasanuddin University, Makassar, Indonesia

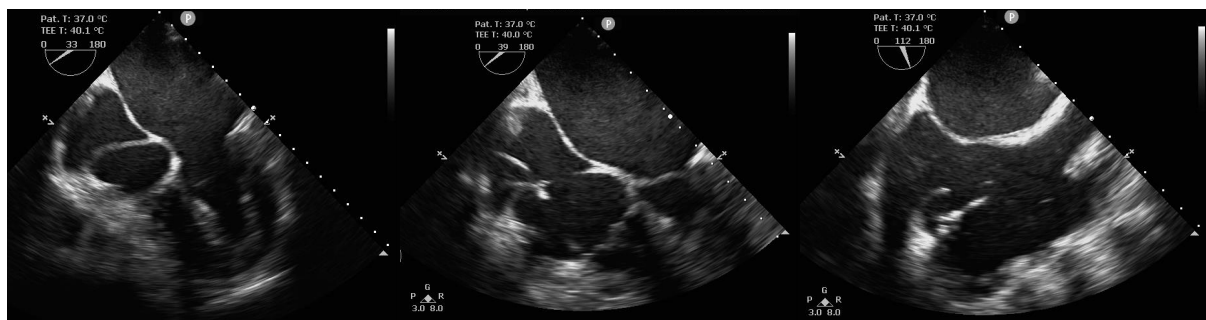²Serdang Heart Center, Serdang, Malaysia

Background: Cor triatriatum dexter (CTD) is characterized by a fibromuscular membrane dividing the right atrium into proximal and distal chambers and is rarely observed in adults. The Eustachian valve (EV) forms a ridge-like crescent arising from the anterior rim of the Inferior Vena Cava (IVC). If its structure and attachment to the atrial septum are large enough to define a giant EV, it can lead to CTD. In patients with cavotricuspid isthmus (CTI)-dependent atrial flutter (AFL), ablation along the CTI line is frequently performed and is typically straightforward. However, certain regional anatomical features can present technical challenges, making bidirectional blockade across the CTI difficult to achieve.

Case Illustration: A 46-year-old woman presented with palpitations and heart failure. She was diagnosed with AFL and treated medically; however, her AFL recurred; therefore, electrophysiological studies and ablation were recommended. Entrainment maneuvers demonstrated CTI-dependent counterclockwise atrial fibrillation. A high-density Pentaray mapping catheter was used to map the AFL propagation. A 4 mm irrigated-tip radiofrequency ablation catheter was used to ablate the CTI line; however, the procedure was unsuccessful in completing the line due to an obstacle preventing catheter access to the inferior vena cava (IVC) end. Review of the pre-procedure transthoracic echocardiography revealed a large effacement (EV) forming a complex trabecular structure within the right atrium. Transesophageal echocardiography facilitated the completion of ablation lines, subsequent termination of atrial fibrillation, and achievement of a bidirectional block.

Conclusion: Anatomical variations, such as a giant EV forming the CTD structure of the CTI, can make energy delivery challenging and predispose patients to procedural failure of AFL ablation. Recognizing this anomaly is critical for developing effective and safe troubleshooting strategies. Ultrasound imaging can be particularly helpful in achieving bidirectional blocks during challenging AFL ablations.

Keywords: Atrial Flutter, Eustachian Valve, Cor Triatriatum.



[12INAHRS-CR2]

Beyond ST Elevation: Spodick's Sign and the Electrocardiographic Diagnosis of Tuberculous Pericarditis

M.Y. Susilo¹, B. Pratama¹, I. Darwis²

¹General Practitioner in Hermina Hospital, Lampung, Indonesia

²Cardiologist in Hermina Hospital, Lampung, Indonesia

Background: Tuberculous pericarditis complicates approximately 1–2% of pulmonary tuberculosis cases and can result in pericardial effusion in approximately 10% of these cases. Accurate diagnosis of acute pericarditis is critical because of its clinical and electrocardiographic similarities to ST-elevation myocardial infarction. Spodick's sign, an electrocardiographic characteristic of acute pericarditis, is frequently overlooked by clinicians despite its significance.

A 46-year-old woman presented to the emergency department with a 3-day history of worsening vomiting and respiratory distress. The patient reported no history of chest pain, fever, or other significant medical conditions. Physical examination revealed an anxious patient with hypotension, tachycardia, a respiratory rate of 38 breaths per minute, a low-grade fever, and an oxygen saturation of 80% while receiving supplemental oxygen via nasal cannula. Auscultation revealed crackles and diminished breath sounds in the lower left lung. Electrocardiography (ECG) showed diffuse, subtle ST elevation and a downsloping T-wave (Spodick's sign), indicative of acute pericarditis. Subsequent ECG demonstrated the development of premature ventricular contractions, suggesting increased myocardial irritability. Laboratory tests revealed anemia, leukocytosis, elevated creatinine and urea levels, hyperkalemia (7.4 mmol/L), normal troponin levels, and metabolic acidosis. Chest radiography revealed cardiomegaly and pleural effusion. Echocardiography revealed moderate pericardial effusion without signs of cardiac tamponade and an ejection fraction (EF) of 81%. The patient was admitted to the intensive care unit and required mechanical ventilation due to progressive respiratory failure. Thoracentesis yielded 500 cc of exudative, xanthochromic fluid with elevated adenosine deaminase (288 U/L), suggestive of tuberculosis. Pericarditis treatment was initiated based on the suspected etiology. Pericarditis treatment was initiated based on the suspected etiology; however, despite the instituted therapies, the patient's condition continued to deteriorate, and she died on the 14th day of treatment.

Conclusion: Recognizing Spodick's sign and vigilance for arrhythmias, such as PVCs, on ECGs remains invaluable for early diagnosis and potentially improved outcomes in acute pericarditis.

Keywords: Spodick's sign, acute pericarditis, tuberculosis, ST elevation

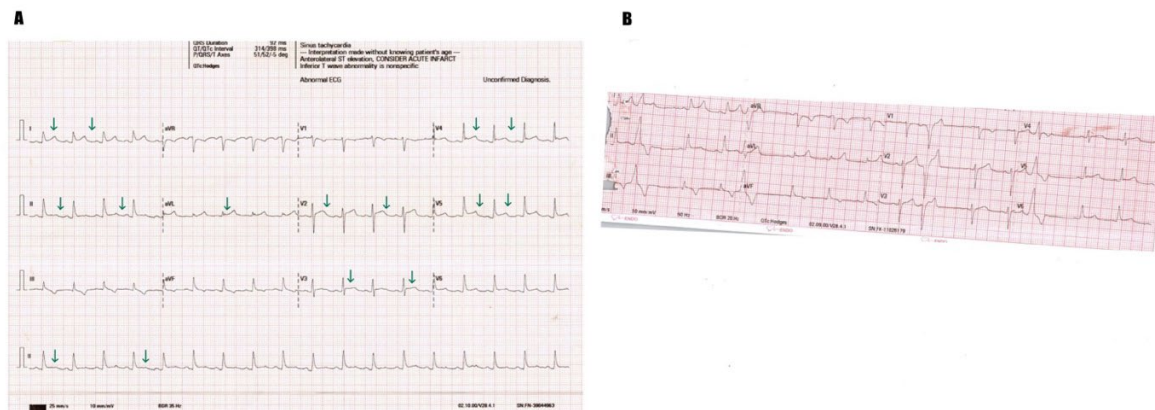


Figure 1. (A) Initial electrocardiogram: diffuse, subtle ST elevation and a downsloping T-wave. (B) Follow-up electrocardiogram demonstrating premature ventricular contractions.

[12INAHRS-CR3]

Bradyarrhythmia Associated with Vitamin B12 Deficiency and Chronic Gastritis: A Case Report in a 25-Year-Old Female

L. W. Samkakai¹, A.P. H. Ferdiyanti²

¹General practitioner at Dsquare Medical Seminyak, Badung, Bali, Indonesia

²Cardiologist, Prima Medika Hospital, Denpasar, Bali, Indonesia.

Background: Vitamin B12 deficiency is a common condition frequently associated with anemia; however, it is rarely recognized as a cause of bradyarrhythmia. To enhance the understanding of bradyarrhythmia in the context of B12 deficiency and chronic gastritis, we report the case of a female patient with chronic gastritis who presented with bradyarrhythmia.

Case illustration: A 25-year-old female presented with a one-year history of fatigue, nausea, retrosternal burning sensation, and sour taste. She also reported palpitations, difficulty concentrating, and distal paresthesia. Laboratory results indicated a white blood cell count of 7,500/mm³, eosinophils at 7%, neutrophils at 46%, HbA1c of 4.8%, and borderline vitamin B12 deficiency (229.52 pmol/L). Electrocardiography revealed sinus rhythm with a heart rate of 56 bpm, PR interval of 173 ms, QRS duration of 102 ms, and QT/QTc interval of 414/416 ms, which were borderline prolonged. The patient had been taking proton pump inhibitors (PPIs) for 12 months without symptom improvement and had experienced significant psychological stress during this period. Treatment consisted of intravenous B12 supplementation (1 vial), mecobalamin (500 mg, 14 tablets) administered once daily for two weeks, and a referral for endoscopy. Following treatment, the patient demonstrated improvement in daily activities, and palpitations and distal paresthesia were no longer reported. Her heart rate increased to 60 beats/min.

Conclusions: Although infrequently recognized as a cause of bradyarrhythmia, vitamin B12 deficiency can lead to significant clinical consequences, particularly in patients with chronic gastritis. Correcting the underlying deficiency via appropriate treatment can improve patient outcomes and enhance the quality of life.

Keywords: Vitamin B12 Deficiency, Bradyarrhythmia, Proton Pump Inhibitors, Paresthesia, Palpitations

[12INAHRS-CR4]
Ventricular Tachycardia in Patients with Coronary Heart Disease

U.Latifah¹, S.C.Dewi²

¹General Practitioner at Citra Arafiq Sawangan Hospital, Depok, Indonesia

²Cardiologist at Citra Arafiq Sawangan Hospital, Depok, Indonesia

Background: Ventricular tachycardia (VT) is a wide-complex tachycardia defined as three or more consecutive beats at a rate exceeding 100 beats per minute originating from the ventricle. Ischemic heart disease is the most common etiology of VT, and approximately 5–10% of patients with acute coronary syndrome experience ventricular arrhythmias. VT in the presence of coronary artery disease may manifest as chest pain, syncope, dyspnea, or cardiac arrest. In hemodynamically unstable patients, intravenous amiodarone should be administered to maintain sinus rhythm if VT is refractory to direct current cardioversion or recurs following successful cardioversion.

Case Illustration: A 51-year-old man presented to the emergency department with chest pain of three days' duration, which had intensified overnight. He reported typical angina, palpitations, and occasional shortness of breath. Physical examination revealed tachycardia (HR 213 bpm), blood pressure 89/71 mmHg, respiratory rate 29, and SpO₂ 99% on supplemental oxygen via a nasal cannula at 4 lpm. ECG demonstrated monomorphic VT with pulse. Laboratory tests indicated elevated myocardial enzymes (troponin I: 10 ng/mL), impaired renal filtration (urinary output/creatinine ratio = 3/89 mL/min), and hyperglycemia (258 mg/dL). Further observation after loading DAPT and amiodarone 150 mg on NS 100 ml finished in 10 minutes, the patient was prepared for synchronized cardioversion 100 joules with sedation Midazolam 3 mg. cardioversion, the rhythm returned to sinus rhythm, accompanied by T-wave inversions in leads II, III, aVF, and V1–V6. During intensive care unit monitoring, the patient received Lovenox 2 × 0.4 mL subcutaneously for five days, aspirin 80 mg once daily, clopidogrel 75 mg once daily, atorvastatin 40 mg once daily, amiodarone 200 mg twice daily, omeprazole injection 40 mg twice daily, and sucralfate syrup 10 mL three times daily, as prescribed by the cardiologist. After 5 days of treatment, the patient had no complaints and was discharged, and still has check-ups once a month now.

Conclusion: Combination cardioversion and amiodarone intravenous can be recommended for the treatment of patients with ventricular tachycardia with coronary heart disease.

Keywords: Ventricular Tachycardia, Cardioversion, Coronary Heart Disease

[12INAHRS-CR5]

Wait and Trust: Conservative Management of Total Atrioventricular Block in Acute Myocardial Infarction: A Case Report in A Resource-Limited Settings

S. A. Himah¹, B. B. Ariesta²

¹*Department of Emergency, Panglima Sebaya General Hospital, East Kalimantan, Indonesia*

²*Department of Cardiology and Vascular Medicine, Panglima Sebaya General Hospital, East Kalimantan, Indonesia*

Background: Total atrioventricular block (TAVB) is a conduction disturbance affecting the transmission of electrical impulses from the atria to the ventricles via the atrioventricular (AV) node. The underlying causes of AV blocks are diverse and may include acute myocardial infarction (AMI). We report a case of TAVB preceded by coronary heart disease, occurring in a resource-limited setting, and resolved with conservative management.

Case Illustration: A 69-year-old female patient presented to the emergency room with complaints of weakness, which had worsened over the preceding three days, accompanied by left-sided chest pain and vomiting. Physical examination revealed a blood pressure of 126/56 mmHg, heart rate of 32 beats/min, respiration rate of 22 breaths/min, temperature of 36.8 °C, and oxygen saturation of 99% on ambient air. Electrocardiography (ECG) revealed TAVB with a ventricular escape rhythm. Laboratory examination showed an increase in troponin I (9,87 ng/mL). Regional heart wall motion abnormalities were indicated by echocardiography. The patient received a loading dose of aspirin (160 mg), clopidogrel (300 mg), and intravenous atropine sulfate (1 mg every 5 minutes, up to a maximum dose of 3 mg), alongside a continuous intravenous infusion of norepinephrine and an intravenous heparin bolus of 3600 units, maintained at 720 units per hour. After 48 hours in the intensive care unit, the ECG converted to normal sinus rhythm at a rate of 102 beats per minute, with Q waves present in leads III and aVF.

Conclusion: TAVB after AMI is rare. Clinical suspicion and thorough evaluation of patients are crucial for early diagnosis and timely definitive treatment, thereby decreasing the morbidity and mortality associated with this condition.

Keywords: Total AV Block; Acute Myocardial Infarction

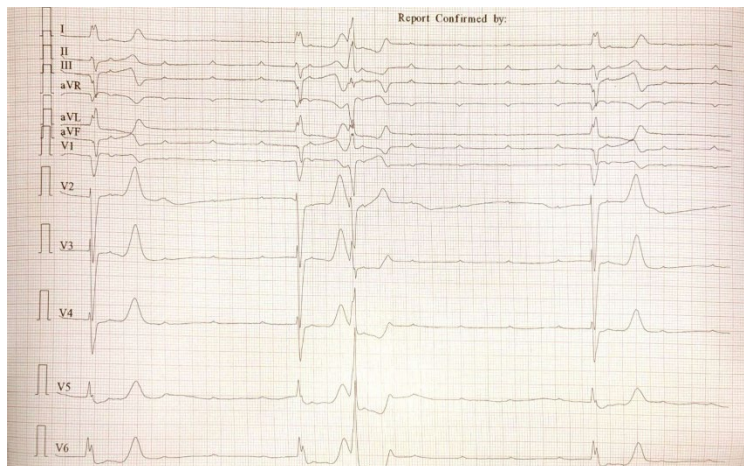


Figure 1. ECG in ER: TAVB with ventricular escape rhythm

[12INAHRS-CR6]

When One Pathway Causes Chaos: A Case Report of Various Arrhythmias with an Underlying Wolff-Parkinson-White Syndrome

A.F Toaha¹, O.O. Palayukan², S. Yolavita³, Y. Iskandar⁴

¹ General Practitioner, Weda Regional Hospital, Central Halmahera, Indonesia

² General Practitioner, I Lagaligo Regional Hospital, East Luwu, Indonesia

³ General Practitioner, Elim Rantepato Hospital, North Toraja, Indonesia

⁴ Cardiologist, Elim Rantepao Hospital, North Toraja, Indonesia

Background: Wolff-Parkinson-White (WPW) syndrome is a congenital anomaly characterized by the presence of an accessory pathway (AP) that facilitates direct atrioventricular conduction, bypassing the decremental properties of the atrioventricular node. This predisposes patients to life-threatening arrhythmias.

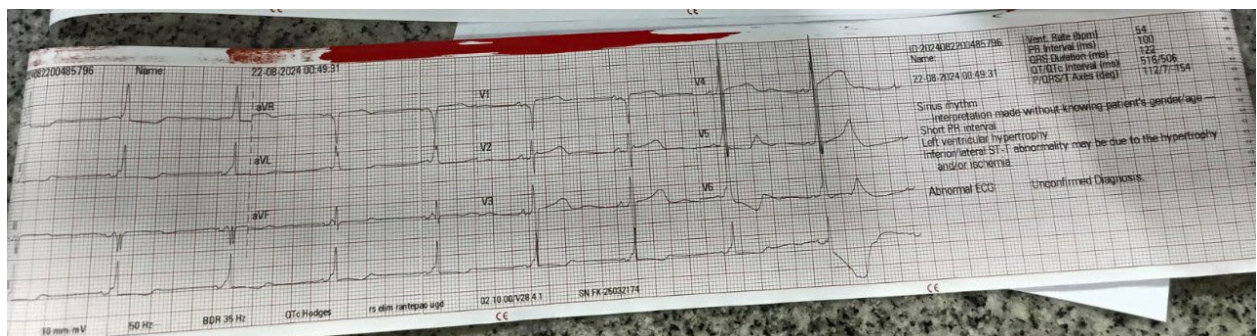
Case Illustration: We report a case of a 52-year-old woman who presented to the emergency department with palpitations. The initial electrocardiogram (ECG) during the episode demonstrated regular wide-complex tachycardia, which was successfully managed with intravenous amiodarone. The baseline ECG in sinus rhythm revealed a short PR interval and a delta wave, indicative of WPW syndrome. The delta wave morphology suggested a right posteroseptal AP. Her tachycardia was diagnosed as antidromic Atrioventricular Reentrant Tachycardia (AVRT).

On a subsequent visit, the patient presented with irregular wide-complex tachycardia. Given the underlying WPW syndrome, a diagnosis of Atrial Fibrillation with WPW was established. Because of her stable vital signs, lidocaine infusion was administered. However, her ECG did not convert to sinus rhythm; the following day, it showed Atrial Fibrillation with a narrow QRS, a significant change from her initial ECG.

The patient underwent an electrophysiological study revealing A-V fusion in the right posteroseptal region. Despite multiple radiofrequency ablation attempts, fusion persisted, suggesting an epicardial accessory pathway location. The procedure was aborted due to its prolonged duration.

Conclusion: WPW syndrome can manifest with diverse and potentially fatal arrhythmias, significantly impacting quality of life. Catheter ablation remains the definitive treatment; however, anatomical challenges, such as epicardial accessory pathways (APs), may complicate its success.

Keywords: WPW, AVRT, Atrial Fibrillation, Ablation



[12INAHRS-CR7]

RBBB Pacing Rhythm in Temporary Pacemaker: A Case Report Evaluation and Management of Lead Malposition into the Middle Cardiac Vein

B.P. Gilang¹, Irnizarifka².

¹Faculty of Medicine, Universitas Sebelas Maret, Indonesia

²Consultant in Arrhythmia and Cardiac Pacing Dept. of Cardiology and Vascular Medicine Faculty of Medicine UNS Surakarta UNS Hospital, Indonesia

Background: Symptomatic bradycardia refractory to medical therapy frequently necessitates temporary pacemaker (TPM) implantation to maintain adequate hemodynamics while addressing the underlying cause. However, complications such as lead malposition can occur during or after TPM insertion. Early recognition of pacing rhythm abnormalities and lead position is critical to prevent adverse outcomes. Despite advances in medical therapy, TPM implantation rates have decreased, potentially reducing clinicians' familiarity with TPM-related complications.

Case Illustration: An 83-year-old male presented with intermittent palpitations, chest discomfort, diaphoresis, and presyncope. Initial ECG showed sinus bradycardia progressing to sinus arrest. Medical therapy failed to improve rhythm, prompting TPM insertion. Post-procedure evaluation demonstrated a right bundle branch block (RBBB) pacing pattern, raising suspicion of lead malposition. Further assessment identified a lead within the middle cardiac vein of the posterior left ventricle, resulting in left ventricular pacing. The lead was subsequently repositioned to the apicoseptal right ventricle. No dislodgement or further complications were observed. The patient was discharged with routine therapy and advised to proceed with permanent pacemaker implantation.

Conclusion: This case underscores the importance of vigilant monitoring for transient pacemaker malfunctions (TPM) complications during and after implantation. Early detection and correction of lead malposition can prevent hemodynamic deterioration and improve patient outcomes. Clinicians should maintain awareness of TPM-related complications despite declining implantation rates.

Keywords: Temporary pacemaker, RBBB, Lead malposition, Complications, Middle cardiac vein

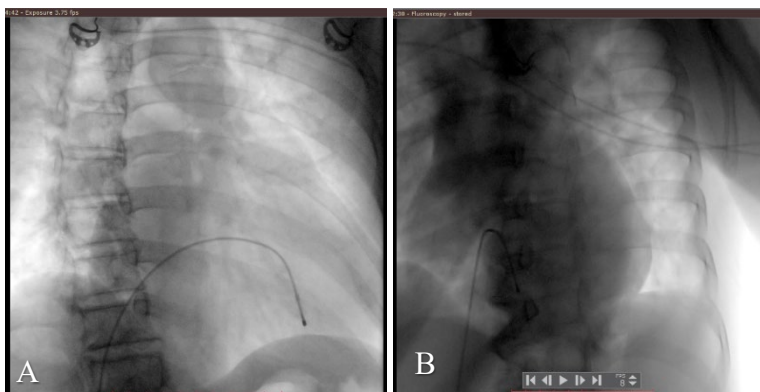


Figure 1. Fluoroscopy of the right ventricle (malposition into the Middle Cardiac Vein) during TPM insertion in RAO (A) and LAO (B) views.

[12INAHRS-CR8]

Digitalis Intoxication: A Report of Two Cases in Elderly Patients

M.A.P Saboe¹, A.M Ainunnisa¹, V.M Arthacya¹, L.M.S Sianipar¹, D.P Andryan², R.H Wibowo^{1,3}

¹Department of Cardiology and Vascular Medicine, Cibabat General Hospital, Cimahi, Indonesia

²Department of Cardiology and Vascular Medicine, Umar Wirahadikusumah General Hospital, Sumedang, Indonesia

³Faculty of Medicine, Pasundan University

Background: Digoxin is widely used to treat heart failure and arrhythmias; however, it has a narrow therapeutic window, increasing the risk of toxicity, particularly in elderly patients with renal dysfunction.

Case Presentation: Case 1: A 72-year-old woman receiving chronic digoxin therapy presented with diarrhea, vomiting, and oliguria. Laboratory investigations revealed hyponatremia (128 mEq/L) and acute kidney injury (creatinine: 3.8 mg/dL). ECG showed a second-degree AV block (Mobitz II) and ST-segment elevation. Given limited resources, digoxin levels were not assessed, and a clinical diagnosis was made. Case 2: A 93-year-old woman with atrial fibrillation who received chronic digoxin therapy presented with similar symptoms. Laboratory tests showed elevated digoxin levels (4.73 ng/mL) and acute kidney injury (creatinine: 2.95 mg/dL). ECG revealed scooped ST segments. Both patients were managed conservatively due to the unavailability of digoxin-specific antibody therapy. Supportive care resulted in gradual clinical improvement.

Discussion: Digoxin toxicity presents a diagnostic and therapeutic challenge, particularly in elderly patients with renal dysfunction. ECG findings were crucial for the diagnosis in both cases, as digoxin level testing was unavailable. DigiFab is the standard antidote, but limited access necessitates supportive management and correction of electrolyte abnormalities. Maintaining potassium balance is critical, as hypokalemia exacerbates toxicity, while hyperkalemia indicates severe poisoning. Early recognition and ECG-based diagnosis are essential in resource-limited settings to prevent complications.

Conclusion: These cases highlight the importance of early recognition of digoxin toxicity, especially in elderly patients with renal impairment. Early diagnosis and intervention are crucial for improved patient outcomes.

Keywords: Digitalis intoxication, Arrhythmias, Atrioventricular block, Digoxin-specific antibody

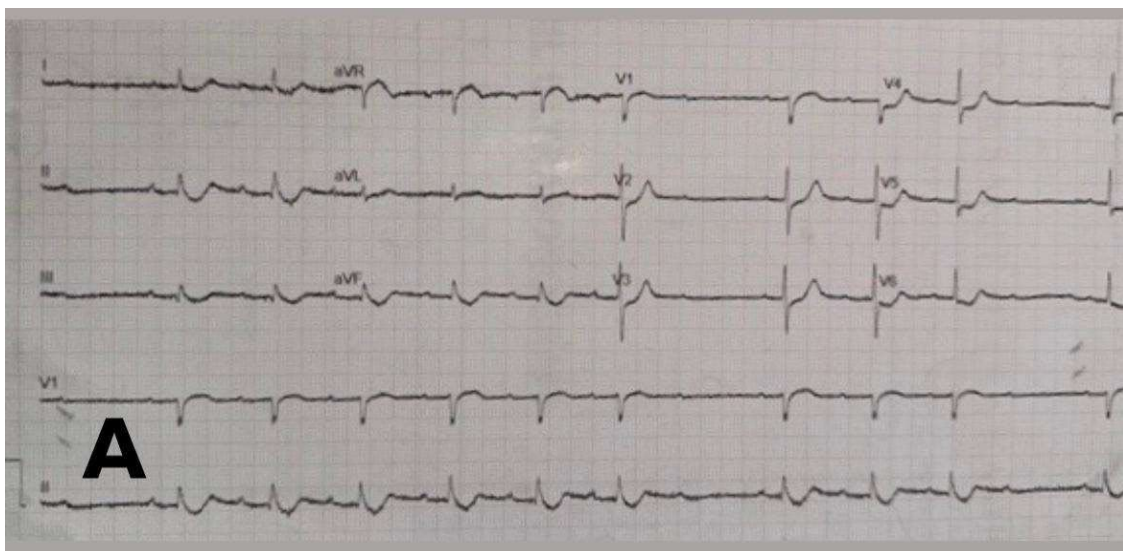


Figure A. ECG showed second degree AV block, Mobitz type II with scooped ST segments in leads II, III, and AVF.

[12INAHRS-CR9]
Protecting Two Lives: Successful Treatment of Idiopathic Left Ventricular Tachycardia During Pregnancy

I. Widanata¹, A. S. Zubeidi^{1,2}, M. N. I Siregar^{1,2}

¹Cardiovascular Center of RSUD Prof. Dr. Aloi Saboe, Gorontalo, Indonesia

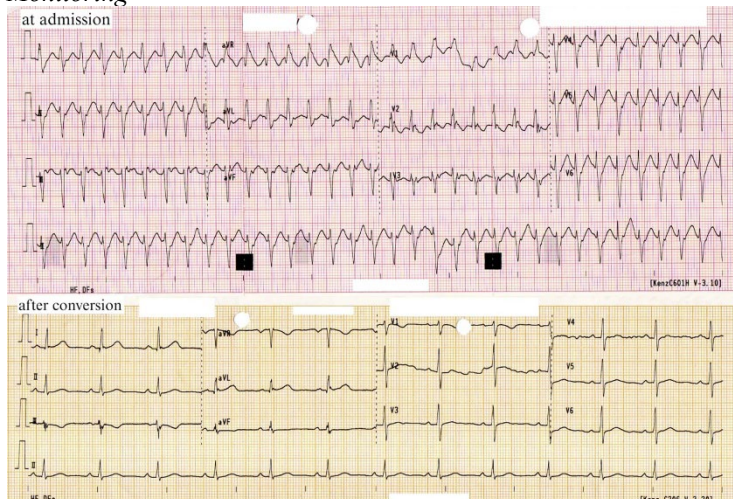
²Faculty of Medicine State University of Gorontalo, Gorontalo, Indonesia

Background: Idiopathic left ventricular tachycardia (ILVT) is a rare form of ventricular tachycardia characterized by the absence of structural heart abnormalities, metabolic disorders, or prolonged QT syndrome. Electrocardiographically, ILVT typically presents with a right bundle branch block (RBBB) and left axis deviation (LAD). It accounts for approximately 10–15% of all ventricular tachycardias originating from the left ventricle. Although uncommon, ILVT can manifest during pregnancy, potentially posing risks to both maternal and fetal well-being. Prompt diagnosis and appropriate therapeutic intervention generally lead to favorable outcomes.

Case Illustration: A 26-year-old woman, gravida 2, para 1, presented to the emergency department at 20 weeks' gestation with an acute onset of severe palpitations and shortness of breath lasting approximately three hours. Initial assessment revealed signs of severe hemodynamic instability, including a blood pressure of 80/50 mmHg, a heart rate of 210 bpm, a respiratory rate of 32 breaths per minute, and an oxygen saturation of 95% on room air. Electrocardiogram (ECG) revealed a regular wide-complex tachycardia with RBBB and LAD. Echocardiography confirmed normal cardiac anatomy and function, revealing a left ventricular ejection fraction (LVEF) of approximately 77%, normal chamber dimensions, and no regional wall motion abnormalities. The patient declined electrical cardioversion, and verapamil was unavailable. Consequently, amiodarone was immediately administered intravenously, resulting in rapid conversion to sinus rhythm and marked clinical improvement. Within 15 minutes, her hemodynamic parameters stabilized significantly (blood pressure 110/70 mmHg, heart rate 90 bpm). Subsequent fetal monitoring indicated normal fetal heart rate and activity, confirming the fetus's healthy condition following intervention.

Conclusion: ILVT during pregnancy requires early recognition and timely intervention to mitigate potential maternal and fetal complications. Rapid intravenous administration of amiodarone effectively restored sinus rhythm and stabilized maternal hemodynamics without adverse fetal outcomes, underscoring the importance of prompt, accurate diagnosis and appropriate therapeutic management in these cases.

Keywords: Tachycardia, Ventricular; Pregnancy Outcome; Cardiovascular Diseases; Amiodarone; Fetal Monitoring



[12INAHRS-CR10]

The Dilemma of Delayed Pacemaker Implantation in Atypical BRASH Syndrome with Persistent Total Atrioventricular Block in a Young Male: A Rare Case Report

I. Rasyid^{1*}, A. Hidayatullah², Y. Tanoyo³

¹General Practitioner, Hermina Arcamanik Hospitals, Bandung, Indonesia

²Cardiologist, Hermina Arcamanik Hospitals, Bandung, Indonesia,

³Internist, Hermina Arcamanik Hospitals, Bandung, Indonesia.

Background: BRASH syndrome, characterized by bradycardia, renal failure, AV block, shock, and hyperkalemia, arises from the combined effects of AV nodal blockers and renal dysfunction, leading to a cycle of conduction abnormalities and hemodynamic instability. Chronic alcohol consumption is a risk factor for cardiac conduction disturbances, including AV block.

Case Illustration: A 23-year-old man with a history of chronic alcohol consumption, increasing to two bottles per day over the past year, presented with weakness, dizziness, and shortness of breath. His heart rate was 32 bpm, and an electrocardiogram (ECG) revealed total atrioventricular block (TAVB). Laboratory results showed acute kidney injury but normal potassium, sodium, and calcium levels, suggesting an atypical case of BRASH syndrome. Despite treatment, TAVB persisted, and the patient was referred for permanent pacemaker implantation.

Conclusion: This case illustrates the dilemma of delaying pacemaker implantation in patients with atypical BRASH syndrome and chronic alcohol consumption, wherein conduction abnormalities persist despite normal electrolyte levels and renal improvement. It emphasizes the challenges of managing alcohol-induced conduction toxicity and the need for further research into BRASH syndrome without hyperkalemia.

Keywords: Atrioventricular Block, Renal Insufficiency, Alcohol-related disorders, Pacemaker

[12INAHRS-CR11]

The Role of PFA in AF Ablation: Case and Review of Literature

S. Laksono¹, P. Nurbaeti²

¹Cardiovascular Departement, Siloam Heart Center, Diagram Hospital

²Faculty of Medicine, Islamic State Syarif Hidayatullah Jakarta

Background: Atrial fibrillation (AF) is the most common clinically significant arrhythmia, characterized by uncoordinated atrial activation resulting from ectopic foci, primarily within the pulmonary veins (PVs). Pulmonary vein isolation (PVI) has become a cornerstone of interventional AF therapy. Pulsed field ablation (PFA), a non-thermal technique utilizing irreversible electroporation, selectively ablates myocardial tissue while preserving adjacent structures, offering a safer alternative to traditional thermal ablation.

Case Illustration: A 65-year-old male presented with worsening chest discomfort and easy fatigability, alongside a history of paroxysmal atrial fibrillation, triple-vessel coronary artery disease (CAD 3VD), hypertension, and structural heart remodeling. Multi-slice computed tomography and transesophageal echocardiography confirmed suitable anatomy for ablation. Under general anesthesia, PVI was performed using the FARAPULSE PFA system, targeting all four PVs. The procedure achieved successful bidirectional isolation of all veins without complications. The patient remained in sinus rhythm and was discharged with stable hemodynamic status.

Discussion: PFA has emerged as an effective and safer modality for AF ablation compared to thermal techniques. The electrophysiological characteristics of PV myocardial sleeves underpin their role in arrhythmogenesis, justifying targeted PVI. Unlike thermal ablation, which carries risks to surrounding tissues, PFA enables selective myocardial ablation with a lower risk of complications, such as esophageal or phrenic nerve injury. Preprocedural imaging, utilizing MSCT and TEE, is crucial for anatomical assessment and procedural success. This case supports the feasibility of PFA in patients with complex cardiovascular comorbidities.

Conclusion PFA represents a promising advancement in AF management, offering effective PVI with minimal risk in high-risk patients. This case highlights the procedural safety, clinical utility, and future potential of PFA as a preferred strategy in AF ablation, particularly in patients with complex anatomical and clinical profiles.

Keyword: Paroxysmal Atrial Fibrillation, Atrial Fibrillation, Pulmonary Vein Isolation, Pulsed Field Ablation, MSCT, TEE

[12INAHRS-CR12]
Palpitation In Primary Care Setting: Let The Electrocardiogram Tell Everything

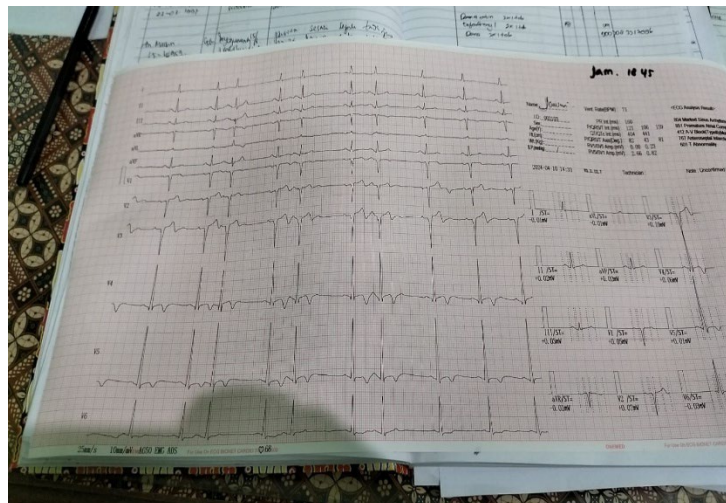
D. A. Laraswati¹, Darsono¹, M. Toha¹
¹Puskesmas Patean, Kendal, Indonesia

Background: Palpitations are a common complaint frequently encountered in primary healthcare services. The etiology of palpitations is broad, encompassing benign conditions to the initial presentation of serious cardiac diseases, including ischemic heart disease and arrhythmias. Electrocardiography (ECG) plays a crucial role as a simple yet highly informative initial diagnostic tool that can help identify underlying conditions such as arrhythmias, ventricular hypertrophy, or old myocardial infarctions that may otherwise go clinically undetected. This case study highlights the importance of accurate ECG interpretation in facilitating prompt management and appropriate referral for patients presenting with palpitations in primary healthcare facilities.

A 71-year-old man presented to our community health center's emergency department complaining of palpitations for one week. The patient also complained of discomfort in the chest, dizziness, and pain in the back of the neck. The patient has a history of smoking for greater than five years. Upon arrival, he was fully conscious, with vital signs including a blood pressure of 132/79 mmHg, a heart rate of 79 beats per minute, a respiratory rate of 20 breaths per minute, a body temperature of 36°C, and an oxygen saturation of 99 % (SpO₂). Electrocardiography (ECG) revealed a normal sinus rhythm with premature atrial contractions, left ventricular hypertrophy with left ventricular strain, and a prior anteroseptal myocardial infarction. The patient was immediately referred to the hospital for further evaluation and care.

Conclusion: Palpitations warrant thorough evaluation, considering the possibility of structural or ischemic heart disease. A 12-lead electrocardiogram (ECG) plays a central role in the initial evaluation and clinical decision-making within primary care. Early detection of PAC, LVH with strain, and OMI through ECG can lead to appropriate interventions and prevent long-term complications.

Palpitations, premature atrial contractions, left ventricular hypertrophy, previous myocardial infarction, electrocardiogram, and primary care.



[12INAHRS-CR13]

The Evolution from Total Atrioventricular Block to Sinus Rhythm in Severe Hypokalemia Patient: A Case Report

E. Rosmillah¹, Z. Zain¹, R. Julario², A. S. Dharma¹

¹*Department of Cardiology and Vascular Medicine, Al Irsyad Hospital, Surabaya, Indonesia*

²*Department of Cardiology and Vascular Medicine, Dr. Soetomo General Hospital, Surabaya, Indonesia*

Background: Hypokalemia is a prevalent electrolyte disturbance in hospitalized patients, affecting over 20% of the patient population. Approximately 4–5% of hypokalemia cases are severe, defined as potassium levels below 2.5 mmol/L. This condition can precipitate life-threatening arrhythmias, such as ventricular fibrillation. Here, we report an uncommon case of total atrioventricular block (TAVB) in a patient with severe hypokalemia who gradually recovered sinus rhythm as potassium levels improved with supplementation during hospitalization.

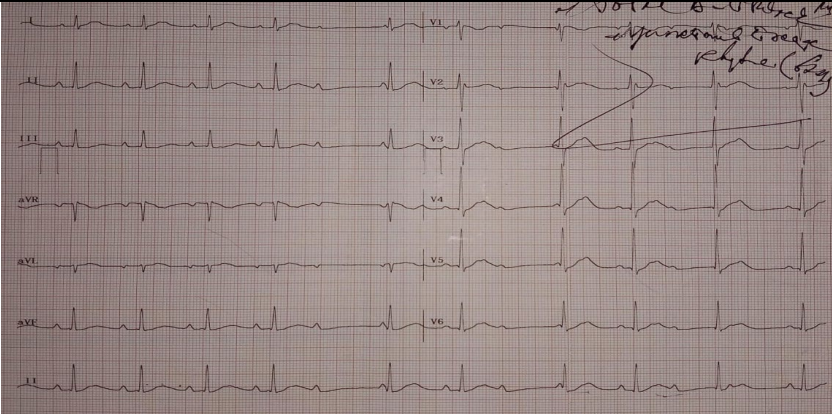
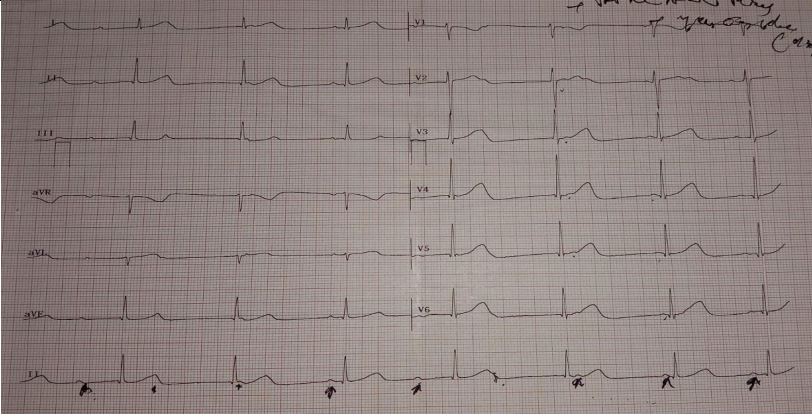
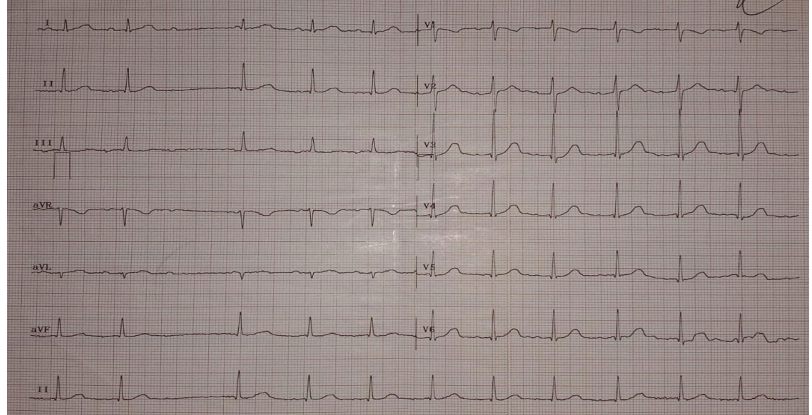
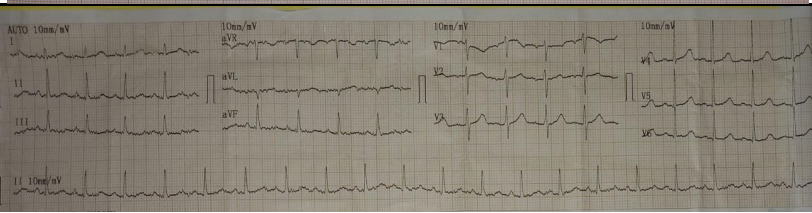
Case presentation: A 35-year-old man presented to the emergency room with abdominal pain without nausea, vomiting, or diarrhea for 3 days. He also reported rigidity and numbness in both lower extremities. He had no reported medication history, including laxatives, diuretics, insulin, or asthma medications. His vital signs were stable, except for a slow, irregular heart rate of 54 bpm. Further examination revealed hypokalemia (1.49 mmol/L) and sinus rhythm with total atrioventricular block (TAVB) on the initial electrocardiogram (ECG), as presented. The patient was hospitalized and treated with potassium supplementation. Clinical condition, potassium levels, and heart rhythm were monitored during a seven-day hospitalization period. As potassium levels improved, both symptoms and heart rhythm improved, as demonstrated in Table 1. Following discharge, the patient was followed routinely in an outpatient setting, with no recurrent symptoms observed after three months.

Discussion: Severe hypokalemia can manifest as fatal arrhythmias because potassium plays a crucial role in cardiac action potential, particularly during repolarization. This condition can promote hyperpolarization and slow conduction velocity, thereby triggering total atrioventricular block (TAVB). Compared to TAVB caused by myocardial infarction, which is the most common etiology, the underlying mechanism may involve increased vagal tone or reduced vascularization of the atrioventricular nodal branch. The severity of hypokalemia is associated with the severity of the AV block. However, the block is reversible, and sinus rhythm can be recovered with potassium supplementation.

Conclusion: TAVB is a rare manifestation of severe hypokalemia. This represents a serious condition, but is typically reversible and can fully resolve with improvement in potassium levels, rendering a temporary pacemaker unnecessary.

Keywords: Hypokalemia, total atrioventricular block, potassium level

Table 1. Comparison of Electrocardiographic Changes from Total Atrioventricular Block to Sinus Rhythm and Associated Potassium Levels during Hospitalization.

Day of Hospitalization	Potassium level (mmol/L)	ECG	Description
1 (Emergency Room)	1.49		Sinus rhythm normoaxis with TAVB
2	1.86		Sinus rhythm normoaxis with TAVB
4	2.22		Sinus rhythm with 2:1 AV block Mobitz 2
6 - 7	3.27		Sinus rhythm with no block conduction

[12INAHRS-CR14]

Sine Wave Rhythm and Pseudo-ST Elevation in a Patient with End-Stage Renal Disease and Severe Anemia: A Diagnostic Challenge

R.N.D.C Ratu¹, R. Jauwerissa²

¹Faculty of Medicine, Universitas Pattimura, Ambon, Maluku, Indonesia

²Dr. Johannes Leimena Central General Hospital, Department of Nephrology and Hypertension, Ambon, Indonesia

Background: Electrocardiographic (ECG) abnormalities are frequently observed in patients with end-stage renal disease (ESRD), particularly in association with severe electrolyte disturbances and profound anemia. Among these abnormalities, hyperkalemia-induced arrhythmias can present with a spectrum of ECG changes, ranging from tall, peaked T waves to the life-threatening sine wave pattern. Although rare, the sine wave represents a pre-terminal sign of severe hyperkalemia, characterized by the progressive merging of QRS and T waves due to impaired myocardial conduction. This pattern may be misinterpreted as acute ST-elevation myocardial infarction (STEMI), particularly when accompanied by ST-segment elevation in specific leads and right bundle branch block (RBBB), as illustrated in this case. Furthermore, severe anemia exacerbates myocardial oxygen supply-demand mismatch, potentially leading to pseudo-ischemic ECG changes, including ST elevation and diffuse T wave inversion, without evidence of coronary artery obstruction.

Case Illustration: We report the case of a 71-year-old woman presenting with ESRD who developed progressive dyspnea, lower limb edema, and poorly controlled hypertension. Initial ECG revealed sinus tachycardia, ST elevation in leads aVR and III, upsloping ST depression in leads I and aVL, RBBB in V1–V2, diffuse T wave inversion, low voltage in aVF, and loss of P waves in V4–V6—features mimicking STEMI with RV strain. Laboratory findings indicated severe anemia (hemoglobin 6.2 g/dL), hyperkalemia (K^+ 6.14 mmol/L), and advanced renal dysfunction (eGFR \approx 3 ml/min/1.73m²). The patient was diagnosed with end-stage renal disease (ESRD), severe anemia, and impending respiratory failure. Management included blood transfusions, correction of hyperkalemia, fluid restriction, and hemodialysis. Following treatment, the patient's clinical condition significantly improved, and there was no evidence of obstructive coronary disease.

Conclusion: This case highlights the diagnostic challenges in interpreting ECG findings in patients with ESRD and complex metabolic disturbances. Pseudo-STEMI patterns due to hyperkalemia and anemia can closely resemble true acute coronary syndromes and may lead to inappropriate invasive interventions if not properly recognized. A comprehensive evaluation, integrating clinical presentation, laboratory data, and serial ECG monitoring, is essential for accurate diagnosis and targeted management in these high-risk patients.

Keywords: End-Stage Renal Disease, Hyperkalemia, Sine Wave Pattern, Pseudo-STEMI, Severe Anemia

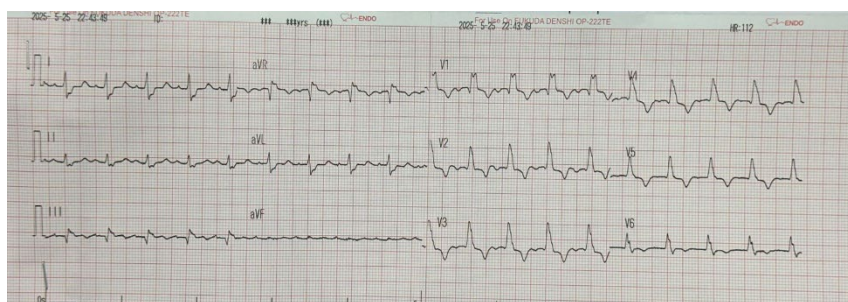


Figure 1. The patient's ECG showed sinus tachycardia with a heart rate of 125 bpm, with ST-segment elevation in leads aVR and III, and upsloping ST-segment depression in leads I and aVL. A right bundle branch block (RBBB) pattern was evident in leads V1–V2, alongside signs of right ventricular hypertrophy (RVH) and strain in leads V1–V3, characterized by diffuse T-wave inversion across the precordial leads. Furthermore, progressive disappearance of P waves was noted in leads V4–V6, and low-voltage P waves were observed in lead aVF.

[12INAHRS-CR15]
**Breaking the Storm: Managing Refractory Ventricular Tachycardia in
Acute Myocarditis with Stellate Ganglion Block**

A. Yudha¹, A.Y.A.B. Mochtar^{1,2}, P. Ardhianto^{1,2}, S. Sungkar^{1,2}, M.F. Ahnaf^{1,2},
M.H. Trisnawan¹, R. Hidayatullah¹

¹Departement of Cardiology and Vascular Medicine Diponegoro University, Semarang, Indonesia

²Dr. Kariadi Central General Hospital, Semarang, Indonesia

Background: Acute myocarditis is an inflammatory condition of the myocardium that can result in severe, life-threatening arrhythmias, including ventricular tachycardia (VT). In severe cases, standard antiarrhythmic therapies may fail to control arrhythmic storms. Stellate Ganglion Block (SGB) has emerged as a potential rescue therapy in such refractory arrhythmia management.

Case Illustration: A 32-year-old man presented with generalized weakness and low-grade fever. Cardiac Magnetic Resonance (CMR) confirmed myocarditis with myocardial edema and inflammation. During hospitalization, the patient developed sustained ventricular tachycardia (VT) with hemodynamic instability, necessitating 16 electrical cardioversions within the first 16 h. Despite administration of antiarrhythmic drugs, deep sedation, and mechanical ventilation, VT episodes persisted. Considering the potential role of sympathetic overactivity in sustaining arrhythmias, bilateral SGB was performed using 0.2% ropivacaine. Following the procedure, VT episodes markedly decreased to only two within 6 days, accompanied by restoration of hemodynamic stability. The patient was successfully extubated and discharged from the hospital without further arrhythmic events. At one-month follow-up, the patient remained arrhythmia-free.

Conclusion: This case demonstrates the role of SGB as an effective adjunctive therapy in managing refractory VT in acute myocarditis when conventional treatments fail. The role of sympathetic modulation underscores the relevance of targeting the autonomic nervous system for arrhythmia control.

Keywords: Acute myocarditis, refractory ventricular tachycardia, stellate ganglion block

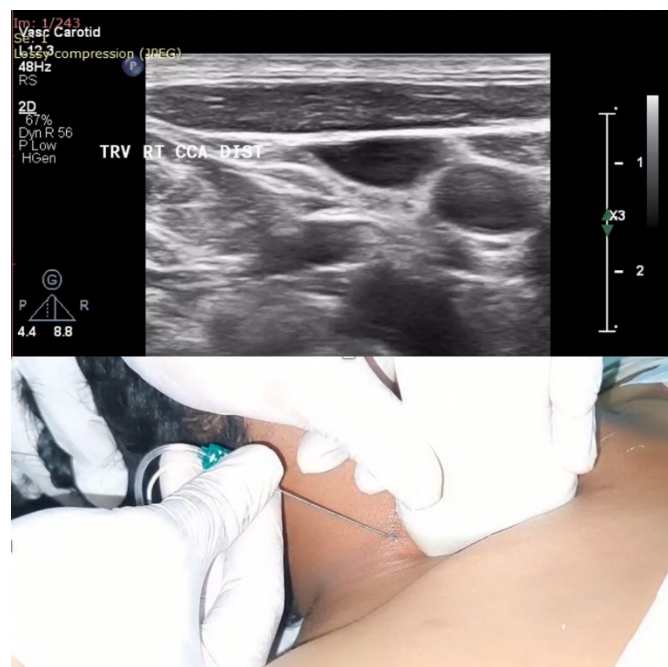


Figure 1. Figure 1 depicts an ultrasound-guided Stellate Ganglion Block (SGB) procedure. The stellate ganglion was identified around the C7 region at the C6 vertebral level. A 100 mm Stimuplex needle was inserted. Ropivacaine 0.2% was deposited beneath the prevertebral fascia and above the longus colli muscle after confirmation of the C6 transverse process.

[12INAHRS-CR16]

Out of Rhythm, Into Isolation: Atrial Tachycardia Resolved by Left Pulmonary Vein Isolation - Case Report

R. Siburian^{1,2}, R. Julario^{1,2}, B. Dharmadjati^{1,2}, R. Rosyadi^{1,2}, R. Gunadi^{1,2}, M. Al-Farabi^{1,2}, J. Arnindita^{1,2}, R. Karimah³

¹Faculty of Medicine, Universitas Airlangga, Surabaya, Indonesia

²Department of Cardiology and Vascular Medicine, Dr. Soetomo General Academic Hospital, Surabaya, Indonesia

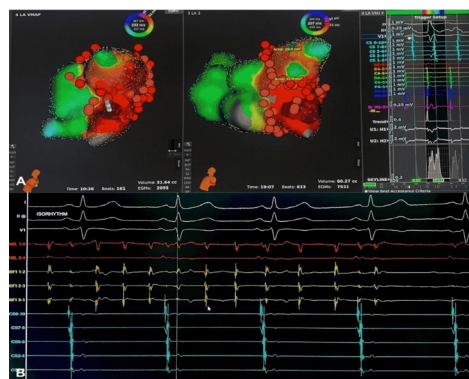
³Faculty of Medicine and Health, Institut Teknologi Sepuluh Nopember, Surabaya, Indonesia

Background: Focal atrial tachycardia (AT) accounts for approximately 10% of supraventricular tachycardia and frequently demonstrates poor responsiveness to pharmacological interventions. These arrhythmias can originate from diverse anatomical locations within the atria and adjacent structures, including the pulmonary veins (PVs), though this is uncommon. The majority of PV-related AT cases occur on the left side, predominantly at the ostium of a single pulmonary vein, particularly the superior PVs. The underlying mechanisms of PV ATs are primarily triggered activity or abnormal automaticity, resulting in a tachycardia cycle length generally longer than that observed in atrial fibrillation (AF), which is characterized by diffuse atrial remodeling and various reentrant arrhythmias. Radiofrequency ablation (RFA) for PV AT can be performed either by directly targeting the AT focus or by employing pulmonary vein isolation (PVI). Both approaches achieved comparable success and low recurrence rates. PVI is frequently utilized in AF ablation due to the presence of multiple and deeper foci within the veins. In contrast, focal RFA for AT is more likely to target the ostium of the PV. However, if the AT focus is located in the distal region of the PV, RFA in that area risks phrenic nerve injury and pulmonary vein stenosis.

Case Illustration: A 35-year-old man with a 2-year history of palpitations and documented atrial tachycardia (AT) was referred for catheter ablation. Standard transseptal puncture was performed under fluoroscopic guidance. The earliest site of activation was identified in the left superior pulmonary vein (LSPV) and left inferior pulmonary vein (LIPV) using 3D mapping. The catheter ablation was advanced into the LIPV, and the LPV was isolated. After 30 minutes of observation, tachycardia could not be re-induced by decremental atrial burst pacing, and the EGM confirmed successful isolated LPV. At the one-month follow-up, the patient was symptom-free, and the ECG was normal.

Conclusion: We employed the PVI approach rather than targeted focal ablation, as the AT focus stemmed from both the distal LIPV and LSPV, resulting in excellent and secure patient outcomes.

Keywords: Atrial Tachycardia; Pulmonary Vein Isolation; Supraventricular Tachyarrhythmia



[12INAHRS-CR17]

The Impact of Mental Health Disorders with Cardiovascular System and Renal Disease as the
Complication : a Case Report

V. M. Alverina¹, A.S. Mangoppo²

¹Johar Baru Public Health Center, Jakarta, Indonesia

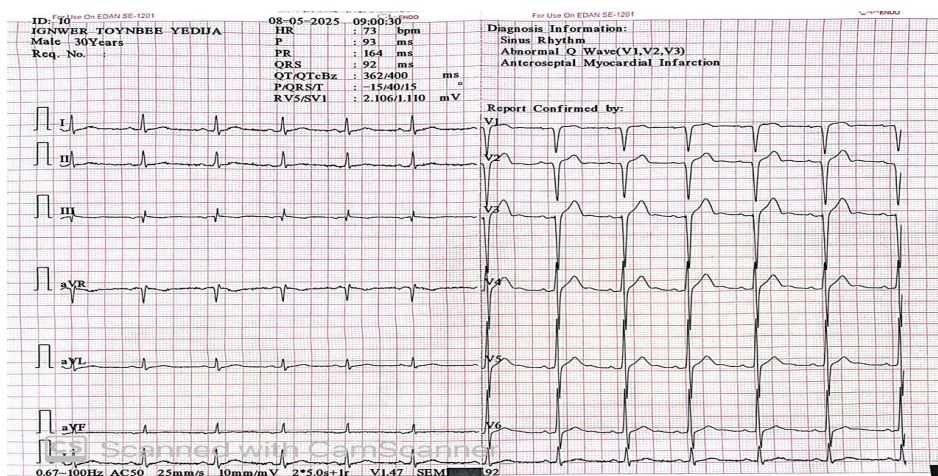
²DKI Jakarta Provincial Public Health Service, Jakarta, Indonesia

Background: Mental health conditions, such as anxiety, are associated with an increased risk of cardiovascular problems and disorders, such as myocardial infarction. This risk is linked to alterations in heart rhythm, including coronary artery spasm and atherosclerosis. The body's response to these stressors involves the release of norepinephrine and neurotransmitters, which can damage nerve endings in the myocardium and elevate the risk of infarction. Activation of the hypothalamic-pituitary-adrenal axis and cardiac autonomic nervous system triggers inflammation, hemostasis, changes in cardiac control, and other mechanisms. Not only the alteration of the cardiac system but also the autonomous kidney control with efferent sympathetic activity stimulation affects the enhancement of kidney vascular resistance, flow reduction, arterial pressure elevation, and hypoperfusion. These prolonged conditions can lead to renal failure. Prolonged effects of these conditions can result in renal failure, which subsequently increases the risk of Major Adverse Cardiovascular Events (MACE), including cardiovascular mortality, acute coronary syndrome, and heart failure.

Case Illustration: A 30-year-old man presented to a Puskesmas with recurrent chest pain complaints since 2018, resolving with rest. He reported persistent anxiety related to personal, familial, and occupational stressors. He had a history of hypertension, hypercholesterolemia, and smoking from 2018 to 2022. His family members also had the same disease. His BMI was categorized as overweight (28.37 kg/m²) and his vital signs and general examination results were within normal limits. Electrocardiograms revealed QS waves in leads V1-V2 and ST elevation in leads V2-V5. Laboratory findings included total cholesterol 250 mg/dL, HDL cholesterol 49 mg/dL, LDL cholesterol 173 mg/dL, creatinine 1.4 mg/dL, uric acid 10 mg/dL, 212 mg/24 hours of microalbuminuria in the urine, and a decline in eGFR of 69 mL/min/1.73 m². The patient received counseling from a clinical psychologist for anxiety and was treated with Allopurinol 3x100 mg, Amlodipine 1x10 mg, Simvastatin 1x20 mg, Salicylic acid 1x80 mg, and subsequently referred to a cardiologist and internist for further management.

Conclusion: Anxiety disorders are associated with an increased risk of myocardial infarction and may lead to renal failure as a late complication.

Keywords: Anxiety, Myocardial Infarction, Cardiovascular



[12INAHRS-CR18]
**Painful Left Bundle Branch Block Syndrome Masquerading as STEMI:
A Case of Rate-Dependent Cardiac Dyssynchrony**

A. Yudha¹, JPS. Sianipar¹, MH. Trisnawan¹, H. Rafsanjani¹, SN. Kadafi¹, DJ. Pesireron¹,
MS. Dhani¹, D. Nugraha¹, P. Ardhianto¹

¹Department of Cardiology and Vascular Medicine, Faculty of Medicine,
Diponegoro University – Dr. Kariadi Central General Hospital, Semarang, Indonesia

Background: Painful left bundle branch block (LBBB) syndrome is a rare condition that can mimic acute myocardial infarction, frequently presenting with exertional chest pain. It is characterized by chest pain associated with new-onset LBBB without evidence of obstructive coronary artery disease and typically resolves when LBBB disappears. Acute cardiac dyssynchrony, attributed to rate-dependent conduction block, is proposed as the underlying mechanism.

Case Illustration: A 52-year-old male patient presented with uncontrolled hypertension and a 2-hour history of left-sided chest pain, characterized as a pressing sensation during activity without radiation. He had no prior cardiac history or family history of sudden cardiac death. Physical examination was unremarkable. Initial ECG from the referring hospital revealed sinus rhythm at 88 bpm with new-onset LBBB. Upon admission, the ECG showed sinus rhythm at 75 bpm, accompanied by LBBB and subsequent supraventricular extrasystoles followed by a normally conducted QRS complex. Due to persistent chest pain and LBBB, primary percutaneous coronary intervention (PPCI) was performed. However, coronary angiography revealed normal coronary arteries, and echocardiography demonstrated preserved cardiac function. Cardiac enzymes were within normal limits. The patient was managed with optimal medical therapy. During hospitalization, the chest pain resolved as the heart rate decreased to 60 bpm, concurrent with the resolution of LBBB on ECG.

Conclusion: This case illustrates a painful LBBB syndrome that mimicked ST-elevation myocardial infarction (STEMI), despite demonstrating normal coronary anatomy and preserved ventricular function. The rate-dependent nature of both symptoms and conduction abnormality suggests a role for acute cardiac dyssynchrony in symptom generation. Clinicians should consider this syndrome in patients presenting with chest pain and new-onset LBBB to avoid unnecessary invasive procedures and ensure appropriate management.

Keywords: Chest Pain, Rate-Dependent, Left Bundle Branch Block, Normal Coronary Arteries

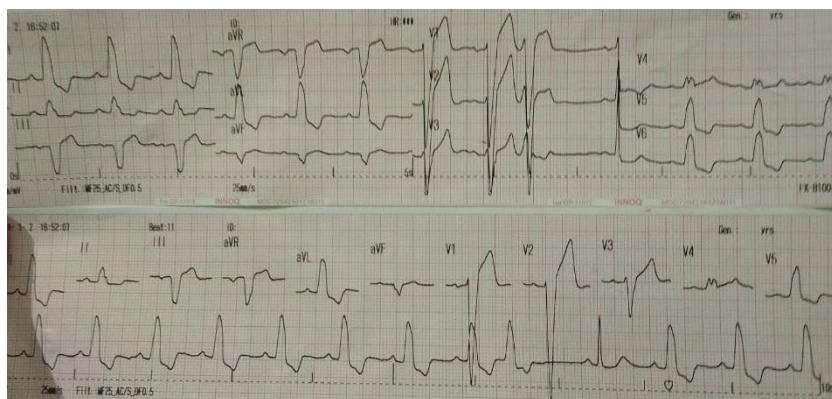


Figure 1. 12-lead ECG showing sinus rhythm at 75 bpm with complete left bundle branch block (LBBB) pattern. A supraventricular extrasystole, accompanied by a compensatory pause, was followed by a single QRS complex exhibiting normal conduction morphology. This observation illustrates the rate-dependent nature of LBBB, as it resolved at a lower heart rate, supporting the diagnosis of painful LBBB syndrome.

[12INAHRS-CR19]

Beyond the Peaks: Unmasking Severe Hyperkalemia Through an Unconventional Electrocardiographic Finding

N. U. Jannah¹, T. L. Bijaksana², M. S. Hutapea¹.

¹General Practitioner, Cikalongwetan Regional General Hospital, Bandung, Indonesia

²Cardiologist, Cikalongwetan Regional General Hospital, Bandung, Indonesia

Background: Severe hyperkalemia, a significant cause of sudden cardiac death, typically manifests with characteristic electrocardiographic (ECG) abnormalities, such as peaked T waves or sine waves. However, clinicians should be aware of rarer presentations. This case report highlights the crucial, yet often overlooked, role of a junctional rhythm as an indicator of this life-threatening electrolyte disturbance, particularly in settings with constrained medical facilities.

Case Illustration: A 79-year-old woman was urgently admitted to the emergency department at Cikalongwetan Regional General Hospital presenting with nausea, vomiting, generalized weakness, and dizziness. Her chief complaints are nausea, vomiting, generalized weakness, and dizziness, coupled with a history of hypertensive heart disease and chronic RAS inhibitor use. Examination revealed symptomatic bradycardia (38 bpm), with an ECG demonstrating a junctional rhythm. Laboratory analysis confirmed critical hyperkalemia (K^+ 9.2 mmol/L) alongside slightly elevated urea and creatinine levels. While awaiting referral for hemodialysis, the medical team employed a multifaceted approach, discontinuing the causative agent and administering atropine, dopamine, glucose-insulin, and calcium gluconate. This aggressive therapy remarkably reduced her potassium to 4.2 mmol/L, correlating with significant clinical and electrocardiographic improvement without the need for dialysis.

Conclusion: This report serves as a vital reminder that junctional rhythms can be atypical, but a decisive electrocardiogram (ECG) can reveal a reversible cause associated with severe hyperkalemia. Prompt and comprehensive pharmacological intervention was crucial in averting mortality, even when advanced facilities such as hemodialysis and temporary pacemakers are unavailable in resource-limited suburban settings.

Keywords: junctional rhythm, hyperkalemia, resource-limited setting, ECG abnormalities

[12INAHRS-CR20]

New-onset T Wave Inversion after Right Ventricular Pacing, Is it an Ongoing Myocardial Ischemia or Cardiac Memory? A Case Report

I.B. Ananta Wijaya¹, I. M. Putra Swi Antara²

¹Faculty of Medicine, Udayana University

²Electrophysiology and Pacing Division, Department of Cardiology and Vascular Medicine, Professor I.G.N.G. Ngoerah Hospital

Background: T-wave inversion (TWI) on electrocardiograms (ECG) frequently presents a diagnostic challenge in acute settings. Although myocardial ischemia is a common consideration, other etiologies must be considered, including cardiac memory T-waves, which are benign phenomena resulting from altered ventricular activation, such as the presence of right ventricular pacing. Differentiating between ischemic and non-ischemic TWI is crucial to avoid unnecessary interventions and extended hospitalization

Case illustration: A 67-year-old man presented to the emergency department with chest heaviness and was diagnosed with symptomatic bradycardia due to total AV block and high-risk non-ST-elevation myocardial infarction (NSTEMI). He subsequently requested temporary pacemaker (TPM) implantation and an immediate invasive strategy. Following TPM implantation, coronary angiography revealed a non-significant lesion, and percutaneous coronary intervention (PCI) was not performed. On follow-up, the patient still had persistent TAVB, and new-onset TWI was found in inferior and precordial leads, with no ischemic symptoms or events and normal laboratory results. Due to a lack of intrinsic rhythm, the patient was later implanted with a permanent pacemaker with VVI mode

Conclusion: Patient TWI morphology met the diagnostic ECG criteria established by Shvilkin and Gunaseelan (positive T waves in leads aVL and I, with greater TWI in precordial than inferior leads), supporting a diagnosis of cardiac memory rather than ischemia. Cardiac memory should be considered in the differential diagnosis of new T-wave inversion observed on post-pacing ECGs, particularly in stable patients without clinical or biochemical signs of ischemia. Recognizing this benign phenomenon is essential to prevent unnecessary testing or interventions. In the setting of RV pacing, cardiac memory represents an adaptive, non-pathological ECG finding that should be diagnosed carefully after ruling out acute coronary syndromes

Keywords: T wave inversion, cardiac memory, right ventricular pacing, pacemaker, myocardial ischemia

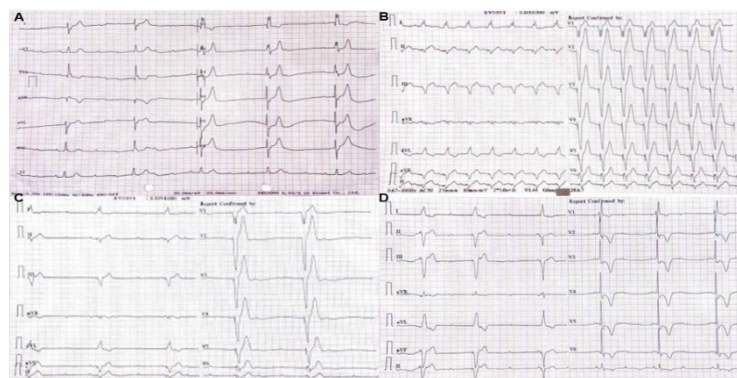


Figure 1. (A) Patient's ECG in 1st admission. (B) Patient's ECG after TPM implantation. (C) The patient's ECG with a TPM rate of 30 bpm showed TAVB. (D) Patient's ECG several days after RV pacing.

[12INAHRS-CR21]

Exercise and Incidence of Atrial Fibrillation: An Unsolved Conundrum

S. Adiwinata¹, K. Yuliet¹, D. Hadi¹, Y. Maria¹, R. Hanafiah¹, R. Gunadi¹, BM. Setiadi¹

¹Department of Cardiology and Vascular Medicine, Sam Ratulangi University, Prof. Dr. R. D. Kandou General Hospital, Manado, Indonesia

Background: The global prevalence of atrial fibrillation (AF) has increased in recent years. Evidence suggests that prolonged vigorous exercise may be an independent risk factor for AF. Several mechanisms have been proposed, including atrial structural remodelling, bradycardia, and atrial fibrosis from postexercise elevations in inflammatory factors and oxidative stress. These factors are considered plausible contributors to the development of exercise-induced AF.

Case Illustration: An 68-year-old man presented to our cardiology clinic with palpitations and recurrent syncope. He reported regular high-intensity exercise (cycling) for 30 years, with no history of smoking, drug abuse, or alcohol consumption. Palpitations and syncope typically occurred during the peak of exercise. He had a normal BMI. His medical history was notable for well-controlled stage I hypertension, with no history of diabetes or dyslipidemia. He had previously undergone multiple evaluations in various practices and was initially diagnosed with extreme sinus bradycardia, and a permanent pacemaker was considered. Six years later, he visited our clinic with AF SVR 40 bpm and an intermittent episode of atrial flutter. Echocardiographic evaluation revealed mild right atrial dilatation, borderline left atrial and ventricular enlargement, and no regional wall motion abnormalities with a preserved ejection fraction. He was referred to a cardiac electrophysiologist, and a 24-hour Holter monitor recorded AF with a slow ventricular response, with the lowest heart rate of 30 bpm during sleep and the longest R-R interval of 3.6 seconds. A permanent His-bundle pacemaker (DDDR mode) was implanted. Despite this, the patient continued to experience fatigue post-implantation. Subsequently, pulmonary vein isolation (PVI) and cavotricuspid isthmus (CTI) ablation were performed.

Conclusion: Physical activity is a cornerstone of cardiovascular disease prevention. However, the mechanisms underlying exercise-induced atrial fibrillation remain incompletely understood. Factors such as age, sex, genetics, and the presence of comorbidities and cardiovascular risk profiles may help identify individuals at an increased risk of developing atrial fibrillation as a result of prolonged vigorous exercise.

Keyword: Atrial Fibrillation, Exercise, Arrhythmia

[12INAHRS-CR22]

Non-ST Elevation Myocardial Infarction with Wolf Parkinson White Syndrome: A Case Report

M.I.S Gunadi¹, F. M.S Harmani²

¹General Practitioner, Adhyaksa Hospital, Jakarta, Indonesia

²Cardiologist, Adhyaksa Hospital, Jakarta, Indonesia

Background: Wolf-Parkinson-White (WPW) syndrome, characterized by episodes of tachycardia and distinctive electrocardiographic (ECG) patterns, can complicate the diagnosis of myocardial infarction (MI) because it may mask the typical ECG signs of MI. Therefore, early utilization of high-sensitivity troponin levels and echocardiography to detect myocardial injury in patients with WPW is crucial. Patients with WPW who experience acute MI may be life-threatening, necessitating timely intervention and improved patient outcomes.

Case Illustration: A 44-year-old man presented to our emergency department with chest pain four days prior to hospital admission. The pain, described as pressure-like, lasted for two hours and occurred spontaneously without provocation by activity. It did not diminish with exertion and was accompanied by a shortness of breath. The patient had no history of diabetes mellitus, hypertension, or cardiovascular disease. He is a smoker. vital signs were normal. Physical examination findings were unremarkable. The initial ECG revealed a sinus rhythm with delta waves and ST depression of 0.2 mm in leads V5 and V6. Following percutaneous coronary intervention, ECG demonstrated sinus rhythm with delta waves and no ST depression. Laboratory results indicated hyperglycemia (407 mg/dL) and a troponin I level of 0.56 mg/dL. A chest X-ray revealed cardiomegaly.

Patients were treated with fondaparinux, ticagrelor, acetylsalicylic acid, ramipril, bisoprolol, atorvastatin, and isosorbide dinitrate. Echocardiography showed a normal heart chamber, EF of 70%, TAPSE of 1.2, mild mitral regurgitation, and mild tricuspid regurgitation. Catheterization showed 70-80% stenosis in the proximal-mid LCX. Percutaneous coronary intervention was performed on the LCX. Angiographic evaluation results were good, with a TIMI flow grade of 3. Following percutaneous coronary intervention, the electrocardiogram showed conversion to sinus rhythm, a narrow QRS complex with delta waves, and no ST-segment depression. The patient was discharged in good health.

Conclusion: The Wolf-Parkinson-White (WPW) pattern can obscure the diagnosis of myocardial infarction in patients presenting with chest pain. Myocardial infarction or ischemia rarely reveals concealed WPW syndrome. This diagnosis can impact the overall treatment of acute coronary ischemia. Recognizing myocardial infarction early is challenging in patients with WPW due to its potential to mimic the presentation of myocardial infarction. Acute myocardial infarction and WPW syndrome may present simultaneously, representing an emergency and potentially lethal event. Accurate and timely diagnosis is critical for the effective management of this condition. Delayed diagnosis may result in delayed treatment, increased myocardial damage, and consequently, higher mortality.

Keywords: NSTEMI, Wolf Parkinson White Syndrome

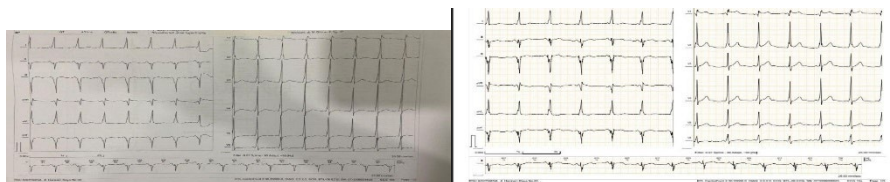


Figure 1. The ECG.

[12INAHRS-CR23]
Ventricular Tachycardia Despite Temporary Pacing in Acute Coronary Syndrome Complicated by Total AV Block: What Could Possibly Go Wrong?

J. Liong¹, M. Amir¹

¹Department of Cardiology and Vascular Medicine, Faculty of Medicine, University of Hasanuddin, Makassar, South Sulawesi, Indonesia

Background: Total atrioventricular block (TAVB) significantly complicates the management of acute coronary syndrome (ACS) and frequently leads to life-threatening arrhythmias such as ventricular tachycardia (VT). Although temporary pacing is a conventional approach, arrhythmic complications can still occur, reflecting complex electrical interactions that are exacerbated by myocardial ischemia.

Case Illustration: A 77-year-old man presented with generalized weakness and near syncope episodes, with a history of hypertension and recent percutaneous coronary intervention (PCI). After TAVB, he was identified with symptomatic bradycardia, and received temporary pacing management (TPM). Despite appropriate TPM settings, the patient experienced sudden, unexpected ventricular tachycardia (VT) marked by hemodynamic instability, requiring cardiopulmonary resuscitation and defibrillation. Laboratory findings revealed a high white blood cell count (21,700/ μ L), neutrophilia (92.7%), elevated procalcitonin (4.36 ng/mL), severe metabolic acidosis (pH 7.31), increased lactate levels (13.3 mmol/L), and reduced renal function (eGFR, 39 mL/min). These results suggest sepsis and multiorgan dysfunction, which exacerbated the ACS and TAVB.

The patient also had a history of notable coronary artery disease (CAD), supported by a recent PCI of the proximal-mid LAD and LCX at a previous hospital. Mildly decreased left ventricular function (EF, approximately 50%) and regional wall motion abnormalities, as identified by echocardiography, suggested structural susceptibility and myocardial ischemia. The patient received comprehensive medical treatment, including lipid-lowering agents, antiplatelet drugs and anticoagulants. A significant arrhythmia developed, indicating underlying myocardial ischemia and electrophysiological instability associated with acute coronary episodes, even in the presence of tenormin (TPM).

Conclusion: This case demonstrates that ventricular tachycardia can occur in individuals with third-degree atrioventricular block and acute coronary syndrome, even when temporary pacing is adequate. Underlying myocardial ischemia and structural heart disease contribute to electrophysiological instability, necessitating heightened awareness and proactive management strategies in similar clinical situations to prevent cardiac arrest.

Keywords: Ventricular tachycardia, Total AV block, Acute coronary syndrome, Temporary pacing.

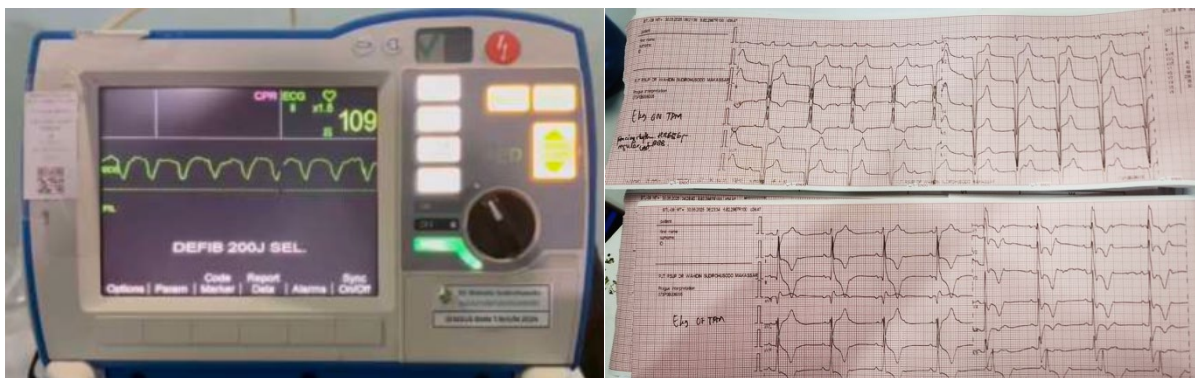

Figure 2. ECG in VT and On TPM.

[12INAHRS-CR24]
**Successful Fibrinolytic Therapy After Cardiopulmonary Resuscitation
in Acute Myocardial Infarction: A Case Report**

R. Pramudya¹, Y.A Arganatha¹, S. Widasmara¹, A.R. Noeriman²

¹RSUD Beriman Balikpapan, Balikpapan, Indonesia

²Faculty of Medicine, Universitas Padjadjaran, Bandung, Indonesia.

Background: Myocardial infarction is a leading cause of death in Indonesia and the most common underlying cause of cardiac arrest. Despite successful cardiopulmonary resuscitation (CPR), it carries a high mortality risk. Fibrinolytic therapy remains controversial in post-resuscitation patients due to bleeding risk. However, it may improve cerebral and myocardial microcirculation. This case report details a successful post-resuscitation fibrinolytic therapy in a patient with inferoposterior ST-elevation myocardial infarction (STEMI).

Case Illustration: A 65-year-old male with a history of heavy smoking presented to the emergency department with severe chest pain lasting two hours, accompanied by diaphoresis and nausea. He denied experiencing vomiting, shortness of breath, or a history of diabetes, hypertension, or stroke. A 12-lead ECG (Figure 1(a)) revealed ST elevation greater than 1 mm in leads II, III, and aVF, with reciprocal ST depression in leads I, aVL, and V1–V4, indicative of an inferoposterior STEMI. He received aspirin 320 mg and ticagrelor 180 mg and was planned for transfer to a PCI-capable hospital.

While awaiting transfer, the patient experienced cardiac arrest. CPR was initiated following asystole, and 1 mg of epinephrine was administered. Subsequently, ventricular fibrillation developed, necessitating a 200-joule shock and 300 mg of amiodarone. Return of spontaneous circulation (ROSC) was achieved after a second shock.

Due to limited access to PCI, 1.5 million units of streptokinase were administered as fibrinolytic therapy. A follow-up electrocardiogram (ECG) one hour later showed >50% resolution of ST elevation in leads II, III, and aVF (Figure 1(b)), accompanied by reduced chest pain and hemodynamic improvement. The patient was managed in the intensive care unit and discharged in good condition without neurological complications.

Conclusion: While primary PCI remains the gold standard for STEMI, fibrinolytic therapy is a viable alternative when PCI is unavailable. With careful bleeding risk assessment and close monitoring, it may offer favorable outcomes in post-resuscitation patients.

Keywords: Fibrinolytic, cardiopulmonary resuscitatio, myocardial infarction.

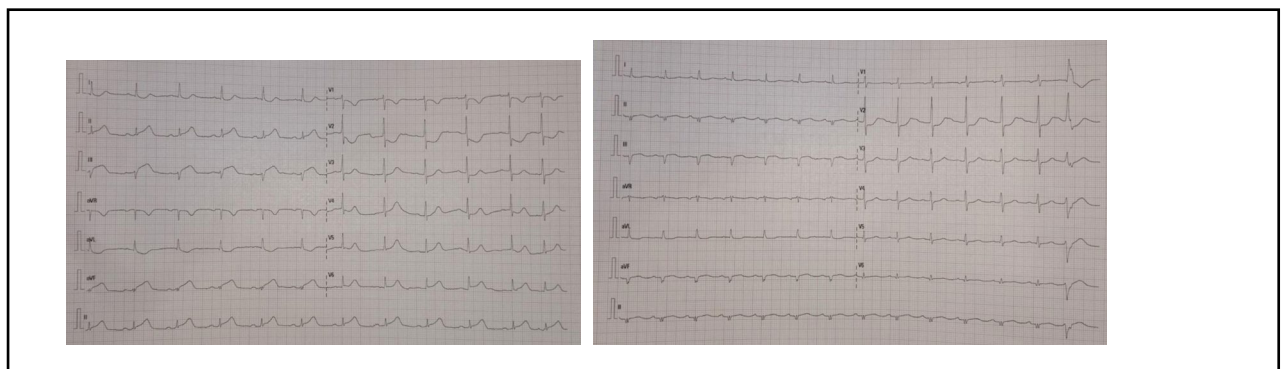


Figure 1. (a) ECG at admission and (b) ECG 1 hour after Fibrinolytics.

[12INAHRS-CR25]

Successful Catheter Ablation of Typical Atrial Flutter in a Patient with Sick Sinus Syndrome and Permanent His-Bundle Pacemaker: A Case Report

R. R. Dewi^{1,3}, R. Julario^{1,2,3}, M. J. Al-Farabi^{1,2}

¹Department of Cardiology and Vascular Medicine, RSUD Dr. Soetomo, Surabaya, Indonesia

²Heart Rhythm Unit, RSUD Dr. Soetomo, Surabaya, Indonesia

³Faculty of Medicine, Universitas Airlangga, Surabaya, Indonesia

Background: Atrial flutter in patients with sick sinus syndrome (SSS) presents a unique management challenge, especially when bradyarrhythmia coexists with symptomatic tachyarrhythmia. In patients already implanted with a permanent pacemaker, catheter ablation represents an effective therapeutic option for rhythm control and symptom relief.

Case illustration: A 77-year-old woman with a history of SSS treated with His-bundle pacing since 2022, coronary artery disease post-PCI, type 2 diabetes, and ischemic stroke presented with worsening dyspnea and palpitations. Electrocardiography revealed typical counterclockwise atrial flutter with variable AV conduction. Transthoracic echocardiography showed HFmrEF with an ejection fraction of 47%. A 3D electroanatomical mapping study confirmed typical counterclockwise atrial flutter with a macro-reentrant circuit around the tricuspid annulus. The patient underwent successful radiofrequency ablation targeting the cavotricuspid isthmus (CTI) at 40 watts for 200 seconds, resulting in termination of the flutter and restoration of sinus rhythm. Entrainment pacing confirmed CTI dependence with a PPI-TCL difference of 32 ms. Despite transient periprocedural hypotension, the patient remained hemodynamically stable post-ablation and showed no recurrence of symptoms. Pacemaker interrogation showed stable function with ventricular pacing at 60 bpm.

Conclusion: This case demonstrates that CTI ablation in a patient with typical atrial flutter and SSS with permanent His-bundle pacing is feasible and effective. Furthermore, 3D mapping enhances procedural precision, and permanent pacing ensures safety during post-ablation bradycardia management.

Keywords: atrial flutter, catheter ablation, sick sinus syndrome, pacemaker, His-bundle pacing

[12INAHRS-CR26]

A Case Report: Ventricular Tachycardia in Adolescent Patients, Management in Limited Facilities

A. Sanapati¹, F. Leksmono²

¹General Practitioner, Dr. Alberth H. Torey General Hospital, Teluk Wondama, West Papua, Indonesia

²Cardiologist, Kementerian Kesehatan Hospital, Makassar, South Sulawesi, Indonesia

Background: Ventricular tachycardia (VT) is rare in children, though it can occur in association with inherited channelopathies or structural heart disease. VTs are much less common in paediatric patients, with rates of 1-8 per 100,000. VT is typically triggered by multiple factors in the presence of a substrate, including myocardial ischemia, hypokalemia, hypomagnesemia, hypocalcemia, sepsis, and metabolic acidosis.

Case Illustration: A 14-year-old boy presented with palpitation, shortness of breath for one hour, and fever over the past day. His vital signs included a blood pressure of 90/50 mmHg, temperature of 37.8°C, heart rate of 287 beats per minute, and respiratory rate of 42 breaths per minute. Electrocardiography (ECG) revealed a regular wide QRS complex tachycardia at 250 bpm, AV dissociation, and a monomorphic VT pattern (Figure 1).

Supportive therapy was administered, and for ventricular tachycardia (VT), the patient received 150 mg of amiodarone over 15 minutes, followed by 300 mg over 6 hours, and then 450 mg over 18 hours. Laboratory results revealed normal glucose and electrolytes; leukocytosis was present, and ceftriaxone was administered. A chest X-ray demonstrated cardiomegaly. After administration of amiodarone, the ECG converted to sinus rhythm, 82 bpm, PR interval 182 ms, occasional PVCs, and inverted T waves in leads V1–V4.

The treatment continued for 3 days, and no recurrent ventricular tachycardia (VT) was observed. The patient was discharged and referred to a cardiologist for further management. In this case, the trigger for VT could not be definitively identified; however, infection was considered a possible cause. Furthermore, ischemia in the anteroseptal segment and cardiomegaly were detected, suggesting potential underlying structural heart disease.

Conclusion: VT in children is exceedingly rare and presents with a wide range of potential triggers; therefore, this case is worthy of further study. Due to limited facilities, additional investigations, including echocardiography, electrophysiology studies, and other examinations, are crucial for comprehensive patient management.

Keywords: Ventricular tachycardia, adolescents, amiodarone, rare case.

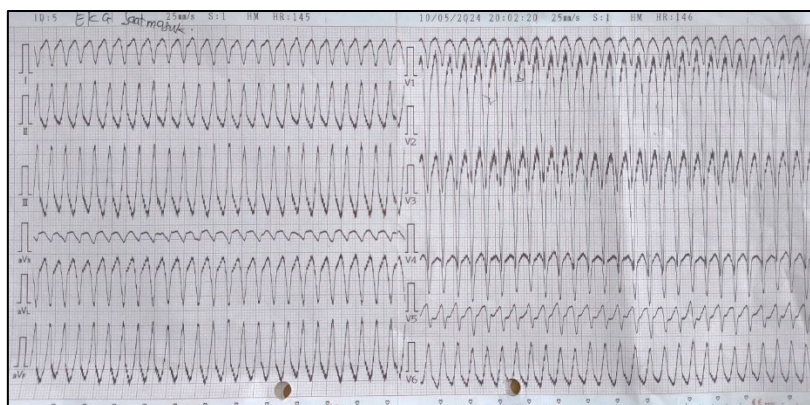


Figure 3. Electrocardiography (ECG) on admission showed Monomorphic VT.

[12INAHRS-CR27]

**Overlooked Pre-Excitation Induced Tachyarrhythmia in Hypertrophic Cardiomyopathy:
When Ignorance is Not a Bliss**

M. Sianturi¹, P.I. Suryajaya²

¹General Practitioner, Siloam Hospitals Kelapa Dua, Tangerang, Indonesia

²Cardiology Department, Siloam Hospitals Kelapa Dua, Tangerang, Indonesia

Background: Pre-excitation syndrome (PS) can cause potentially life-threatening extreme tachyarrhythmias. The coexistence of PS and hypertrophic cardiomyopathy (HCM) is not uncommon, although it is frequently overlooked and may increase the risk of sudden cardiac death.

Case Illustration: A 29-year-old man presented with a sudden onset of palpitations and shortness of breath, followed by a recurrent syncopal episode on the way to the ER. Limited history could be obtained initially due to the patient's agitated status; however, he remained fully alert. Physical examination revealed normotension with extreme tachycardia, up to 200 beats per minute (bpm), accompanied by rales of both lungs. Initial electrocardiography (ECG) demonstrated a narrow complex tachycardia with a heart rate of 200 bpm. Initially diagnosed as supraventricular tachycardia, a dose of 0.25 mg of digoxin was administered intravenously. Within minutes, the tachycardia worsened, with the heart rate increasing to 225 bpm despite the patient remaining fully alert and normotensive. The planned urgent cardioversion was subsequently withheld. After reviewing the ECG, the elevated rate and QRS alternans raised suspicion of pre-excitation syndrome, potentially exacerbated by digoxin administration. Amiodarone infusion was initiated, with urgent cardioversion prepared as needed. Over the subsequent 30 minutes, the rate gradually decreased, and the follow-up ECG revealed irregular, narrow QRS-complex tachycardia with visible P waves and a P-rate of 187 bpm, suspected as atrial tachycardia with variable conduction. Over the following hours, the rate normalized to 62 bpm, and the follow-up ECG demonstrated sinus rhythm with a short P-R interval, confirming the suspicion of pre-excitation syndrome. Echocardiography revealed severe symmetrical left ventricular hypertrophy, suggestive of hypertrophic cardiomyopathy (HCM). The patient was hospitalized for two days and treated with amiodarone, bisoprolol, and furosemide. He was then discharged and referred for consideration of ablation therapy.

Conclusion: Extreme tachycardia, potentially induced by PS, may be exacerbated by the administration of AV-nodal blocking agents such as digoxin. Further tachycardia could compromise ventricular filling in the underlying HCM, potentially leading to pulmonary edema. Early diagnosis and heightened suspicion of PS are crucial in cases presenting with extreme tachycardia to prevent unnecessary hemodynamic deterioration.

Keywords: Tachyarrhythmia, Pre-excitation Syndrome, Hypertrophic Cardiomyopathy

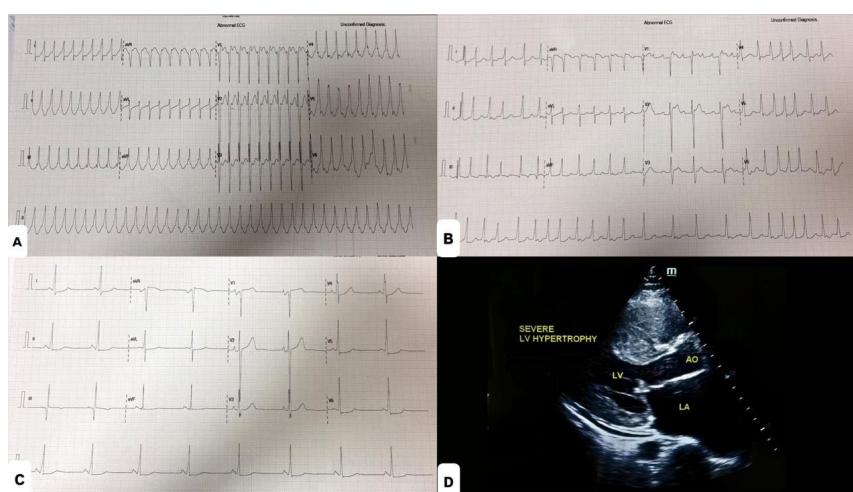


Figure 1. The serial ECG at Initial presentation (A); Post-amiodarone infusion (B); Final ECG (C), and the severe LV septal hypertrophy on Echocardiography (D).

[12INAHRS-CR28]

Probable Dengue-Associated Myocarditis Presenting with Mobitz Type II AV Block: A Case Report

F.K.Carlos MD¹, Olivia Handayani MD²

¹General Practitioner Mayapada Hospital Kuningan, Jakarta, Indonesia

²Cardiologist Mayapada Hospital Kuningan, Jakarta, Indonesia

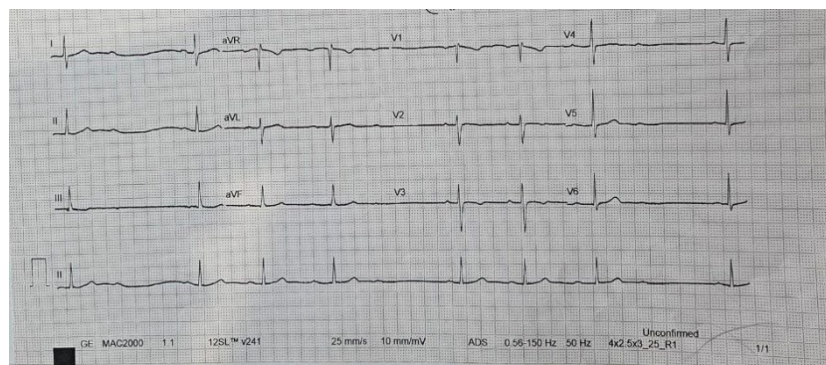
Background: Myocarditis is an inflammatory condition of the myocardium, presenting with a spectrum of clinical manifestations ranging from asymptomatic disease to fulminant heart failure or sudden cardiac death. Although dengue fever is a common mosquito-borne viral illness in endemic regions, its association with myocardial involvement, including conduction disturbances such as atrioventricular (AV) block, is relatively rare but potentially life-threatening. Early recognition of these cardiac complications is crucial for optimal patient outcomes.

Case Illustration: A 32-year-old previously healthy male presented with a one-day history of high-grade fever, a diffuse rash, nausea, and abdominal discomfort. He reported a similar febrile illness two weeks prior. Laboratory findings revealed thrombocytopenia (157,000/ μ L), leukopenia (3,800/ μ L), and elevated liver enzymes. Dengue NS1 antigen was reactive. Based on elevated cardiac biomarkers, including hs-Troponin I (34.3 ng/L) and CRP (12.94 mg/L), a probable diagnosis of dengue-associated myocarditis was made. Electrocardiography revealed second-degree AV block (Mobitz type II), while echocardiography showed preserved left ventricular function with no regional wall motion abnormalities. The patient was treated supportively in a high-care setting and monitored closely. No pacing was required. He exhibited clinical improvement and was discharged after seven days. At a three-month follow-up, he remained asymptomatic with normal cardiac function.

Conclusion: This case highlights a rare presentation of probable myocarditis associated with dengue fever, complicated by Mobitz type II AV block. It underscores the importance of early cardiac evaluation in dengue patients presenting with atypical symptoms. Prompt diagnosis and appropriate monitoring can facilitate full recovery and prevent long-term complications.

Keywords: Dengue fever; Myocarditis; Atrioventricular block; Mobitz type II; Cardiac biomarkers.

Parameter	Result	Unit
Hemoglobin	12.5	g/dL
Hematokrit	37	%
Leukosit	4.7	ribu/ μ L
Trombosit	188	ribu/ μ L
AST (SGOT)	35	U/L
ALT (SGPT)	38	U/L
Dengue NS1 Antigen	Reaktif	-
CRP	12.94	mg/L
hs-Troponin I	34.3	ng/L
CK-MB	1.4	ng/mL



[12INAHRS-CR29]

A Wolf in Sheep's Clothing: The Tale of A Masquerading Bundle Branch Block in a Rural Area: A Case Report

I. B. P. E. Werdi Putra¹, Y. S. Sugi², C. Saputra³

¹Departement Emergency Sito Husada Hospital, Atambua, Indonesia

²Departement Internal Medicine, Sito Husada Hospital, Atambua, Indonesia

³Departement Cardiology and Vascular Medicine, Mgr Gabriel Manek General Hospital, Atambua, Indonesia

Background: Masquerading bundle branch block (MBBB) is a rare cardiac conduction disorder. It typically suggests an underlying structural or ischemic heart disease and indicates significant conduction system abnormalities frequently associated with severe fibrotic degeneration. Recognizing this pattern is crucial to avoiding misdiagnosis and delays in management.

Case Illustration: A 68-year-old male patient presented to Sito Husada Hospital with chest pain described as a heavy pressure radiating to his left arm, accompanied by cold sweats, persisting for one month and unrelieved by rest. His medical history included hypertension managed with amlodipine, chronic obstructive pulmonary disease, and a prior myocardial infarction. Initial electrocardiogram (ECG) results indicated UAP, with a differential diagnosis of NSTEMI and CRBBB in Fig. 1. After loading ACS therapy, serial ECGs were obtained, revealing bifascicular block (CRBBB + left anterior fascicular block). Upon subsequent evaluations, the ECG revealed a masquerading bundle branch block (MBBB) in Fig. 1. A chest X-ray displayed mild cardiomegaly and increased bronchovascular patterns in Fig 3. Since it was known that the patient was at risk for sudden cardiac death, we made a recommendation to refer the patient. However, the patient and his family declined the referral request, citing a preference for further treatment at an alternative hospital. Despite initial improvement in chest pain, the patient reported new symptoms of palpitations and general weakness. Further evaluation revealed total AV block (TAVB).. After repeated evaluation, the patient fell into a hypotensive condition, which required inotropic administration, but the condition worsened, leading to sudden cardiac arrest. Despite resuscitation efforts, the patient could not be resuscitated and was pronounced dead.

Conclusion: Masquerading bundle-branch block is a rare arrhythmia disorder, and the “masked” nature of this conduction abnormality underscores the importance of clinical vigilance and a deep understanding of ECG patterns.

Keywords: Masquerading Bundle Branch Block, Chest pain, Old male patients

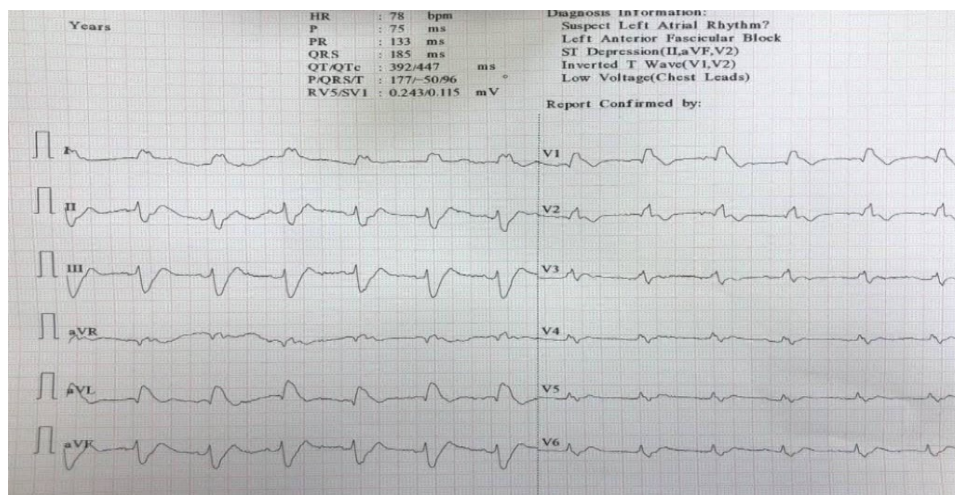


Figure 1. First ECG in ER.

[12INAHRS-CR30]

From Storm to Calm: Refractory Ventricular Tachycardia with Escalating Energy Protocol in Extensive Anterior STEMI

B. Ardell¹, M. Ruslim², K. Ummah³

¹General Practitioner in Rumah Sakit Pusat Pertahanan Negara (RSPPN) Soedirman, Jakarta

²General Practitioner in Rumah Sakit Primaya, Makassar

³Cardiologist in Rumah Sakit Primaya, Makassar

Background: Ventricular tachycardia represents a significant life-threatening complication of acute ST-elevation myocardial infarction, occurring in approximately 10–15% of patients. We present a challenging case of refractory ventricular tachycardia in a patient with extensive anterior STEMI and cardiogenic shock, requiring multiple high-energy cardioversions and demonstrating the critical importance of aggressive multimodal management in disrupting the ischemia-arrhythmia cycle.

Case Illustration: We present a compelling case of a 60-year-old male patient who developed an extensive anterior ST-elevation myocardial infarction (STEMI) with Killip class IV and ventricular tachycardia (VT) storm. Upon admission to the intensive care unit, the patient exhibited sustained ventricular tachycardia at a heart rate of 218 beats per minute, characterized by wide QRS complexes, a regular rhythm, and atrioventricular dissociation. Despite initial pharmacological intervention with intravenous amiodarone and lidocaine, the patient demonstrated refractory ventricular tachycardia requiring an aggressive cardioversion protocol. Eight sequential cardioversions at 100 joules achieved only transient sinus rhythm restoration, lasting approximately 60 minutes per intervention. Escalation to 150 joules for three additional attempts resulted in progressively shortened sinus rhythm durations, averaging 10 minutes per cardioversion. Definitive rhythm stabilization was ultimately achieved following two cardioversions at 200 joules, establishing a sustained sinus rhythm. Subsequently, the patient underwent successful percutaneous coronary intervention for definitive coronary revascularization.

Conclusion: The extensive anterior STEMI in our patient resulted in a heterogeneous myocardial substrate characterized by zones of viable, ischemic, and necrotic tissue, establishing conditions conducive to reentrant ventricular arrhythmias through differential conduction velocities and refractory periods. Ischemic myocardium exhibited prolonged action potential duration and delayed conduction, while adjacent viable tissue maintained normal electrophysiological properties, creating critical slow conduction zones necessary for reentry circuit formation and maintenance. The refractory nature of the patient's ventricular tachycardia, evidenced by the requirement for multiple high-energy cardioversions and progressive shortening of sinus rhythm intervals, suggests the presence of multiple reentrant circuits or enhanced automaticity secondary to severe ischemic injury and cardiogenic shock. Ultimately, definitive rhythm stabilization was achieved only after aggressive electrical cardioversion combined with urgent percutaneous coronary intervention, highlighting the critical importance of rapid revascularization in disrupting the ischemia-arrhythmia cycle and restoring myocardial electrical stability.

Keyword: Ventricular Tachycardia, Electrical Storm, Refractory Arrhythmia

[12INAHRS-CR31]
Supraventricular Tachycardia Converted to Sinus Rhythm Using Modified Valsalva Maneuver in A Patient with Wolff-Parkinson White Syndrome: A Case Report

A. A. Putri¹, G. Rizkyta¹

¹Faculty of Medicine, Andalas University, Padang

Background: Supraventricular tachycardia (SVT) is a common cardiac arrhythmia that can cause hemodynamic instability and necessitate hospitalization. Although the Valsalva maneuver is a simple and safe initial treatment for SVT, modified versions of this technique have demonstrated superior outcomes compared to the conventional Valsalva maneuver.

Case Illustration: A 27-year-old female patient presented to the emergency department with a chief complaint of chest discomfort. Her heart rate was 203 beats per minute, blood pressure was 102/76 mmHg, and she was alert. The patient was known to have Wolff-Parkinson White syndrome and was scheduled to undergo catheter ablation the following month. An electrocardiogram (ECG) revealed supraventricular tachycardia with a ventricular rate of 204 beats per minute. To maximize venous return, the patient performed a standard Valsalva maneuver in a semirecumbent position for 15 seconds. Immediately after the strain, she was laid flat with her legs raised passively to 45 ° for another 15 seconds. Her ECG converted to sinus rhythm shortly after the maneuver. The patient immediately felt better, but unfortunately refused further hospitalization and management.

Conclusion: The modified Valsalva maneuver is a simple, noninvasive procedure that may reduce the need for antiarrhythmic drugs and even the need for electrical cardioversion. It is also more effective than the standard Valsalva maneuver and may be considered a first-line measure, unless contraindicated.

Keywords: *modified Valsalva maneuver, Valsalva maneuver, supraventricular tachycardia, arrhythmia, management*

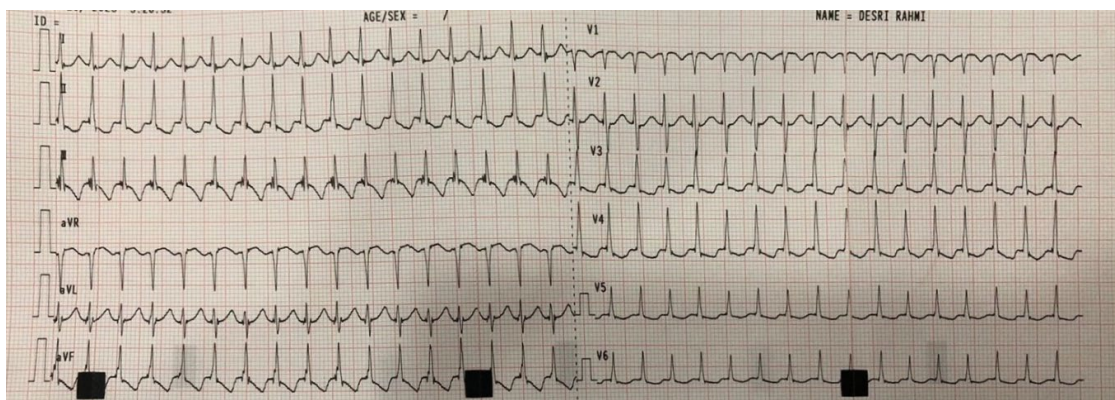


Figure 1. Figure 1: ECG demonstrating ventricular tachycardia with a ventricular rate of 204 bpm.

[12INAHRS-CR32]

Heart Gone Wild : When Your Ventricles Party Harder Than Your Exercise Plan

M. Ruslim¹, B. Ardell², I. N. Guntur³, W. Kwandou⁴

¹General Practitioner in Primaya Hospital, Makassar

²General Practitioner in Pusat Pertahanan Negara (RSPPN) Hospital, Jakarta

³General Practitioner in Pelamonia Hospital, Makassar

⁴Cardiologist in Primaya Hospital, Makassar

Background: Exercise-induced ventricular tachycardia (EIVT) is a rare condition that can occur in both structurally normal and abnormal hearts. It has been widely reported in patients with preexisting structural heart disease or underlying ischemia. However, its occurrence in structurally normal hearts is infrequently reported. Recognizing EIVT is essential to guide evaluation and management, and to differentiate it from more serious causes of exertional syncope.

Case Illustration: A 54-year-old man presented for a medical check-up, reporting exertional palpitations and recurrent syncopal episodes. His cardiovascular profile revealed obesity and dyslipidemia. Resting vital signs were stable: blood pressure 120/80 mmHg, heart rate 71 bpm, and respiratory rate 16/min. During a treadmill exercise stress test, he developed a sustained wide-complex monomorphic ventricular tachycardia at 180 bpm, exhibiting a left bundle branch block (LBBB) pattern, and capture and fusion beats, suggestive of a right ventricular origin. Subsequent evaluation via transthoracic echocardiography and coronary angiography demonstrated no apparent structural heart disease. He initiated treatment with metoprolol succinate 50 mg daily and simvastatin 20 mg daily for symptom control and risk factor management. He was planned for referral to an electrophysiology study and an evaluation for an implantable cardioverter-defibrillator. At follow-up, he remained asymptomatic, with no further ventricular tachycardia episodes.

Conclusion: Exercise-induced ventricular tachycardia (EIVT) does not invariably occur in patients with structural heart disease and can also present in individuals without such abnormalities, including channelopathies. Early recognition and prompt management of this condition by clinicians are crucial to mitigate mortality risk. Furthermore, clinicians recommend avoiding competitive sports and strenuous activities to prevent sudden cardiac death.

Keywords: Ventricular Tachycardia, Exercise Stress Test

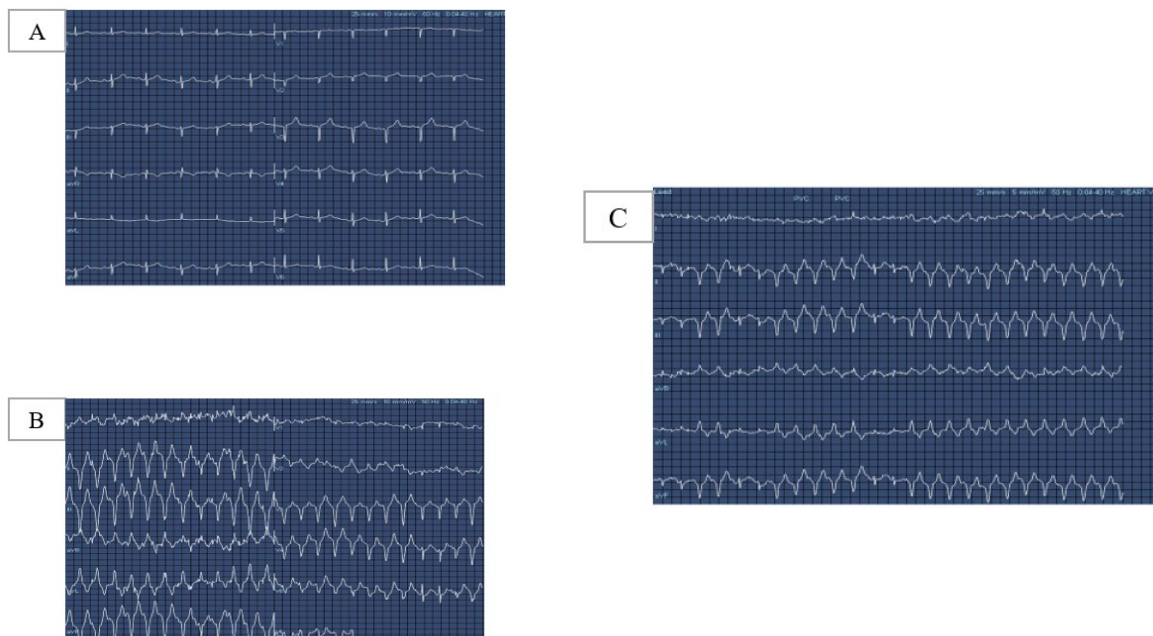


Figure 1. (A) ECG before treadmill exercise stress test, (B) ECG during treadmill exercise stress test, (C) Ventricular tachycardia.

[12INAHRS-CR33]

From Fever to Arrhythmia: A Rare Progression of Dengue to Myocarditis induced Ventricular Tachycardia

Gani, W¹; Resliany¹; Akbar, SMS¹

¹Inche Abdul Moeis General Hospital, Samarinda, Indonesia

Background: Dengue fever is a disease caused by the dengue virus and spreads through mosquito bites, particularly *Aedes aegypti*.¹ The 2009 World Health Organization (WHO) criteria classify dengue according to levels of severity: dengue without warning signs; dengue with warning signs, and severe dengue.² Severe dengue may be associated with fatal complications such as myocarditis.¹ Almost all cases of dengue myocarditis are self-limiting, and severe myocarditis leading to dilated cardiomyopathy is extremely rare.^{3,4}

Case Illustration: A 35-year-old man was referred to our hospital from a Puskesmas with an initial diagnosis of dengue hemorrhagic fever (DHF). Patients complained of fever for 3 days. No other symptoms were reported. The patient was initially consulted by internal medicine with a working diagnosis of dengue haemorrhagic fever (DHF) with warning signs. Patient's initial vital signs showed hypotension, tachycardia, and fever. The patient was then treated with fluid resuscitation in accordance with DHF guidelines. On the second day of hospitalization, the patient's general condition worsened. Melena was reported, hypotension was found, along with palpebral oedema, and generalized icterus. The patient was subsequently transferred to the intensive care unit (ICU). On the third day, palpitations were reported, and hemodynamics stabilized. An electrocardiogram (ECG) demonstrated a sinus rhythm with R-on-T waves, ventricular extrasystole with a bigeminy pattern, and an episode of junctional rhythm. Shortly thereafter, the patient's vital sign monitor recorded multiple episodes of ventricular tachycardia (VT) (Fig 1). Cardiologists were consulted, and amiodarone and colchicine were administered. Laboratory examination revealed a significant increase in erythrocyte sedimentation rate (ESR), C-reactive protein (CRP), high-sensitivity troponin I, and N-terminal pro-hormone brain natriuretic peptide (NT-proBNP). Echocardiography was not performed due to the unavailability of the modality in our ICU. The patient was then diagnosed with severe dengue complicated by myocarditis. After treatment, no further palpitations or VT episodes were detected. The patient was then discharged 5 days later.

Conclusion: Severe dengue may be associated with fatal complications, including myocarditis. Most cases of dengue myocarditis are self-limiting. Early recognition of myocardial involvement in dengue illness, prompt restoration of hemodynamic instability while avoiding fluid overload, and sparing unnecessary invasive management are important in treating dengue myocarditis.³

Keywords: dengue, ventricular tachycardia, myocarditis

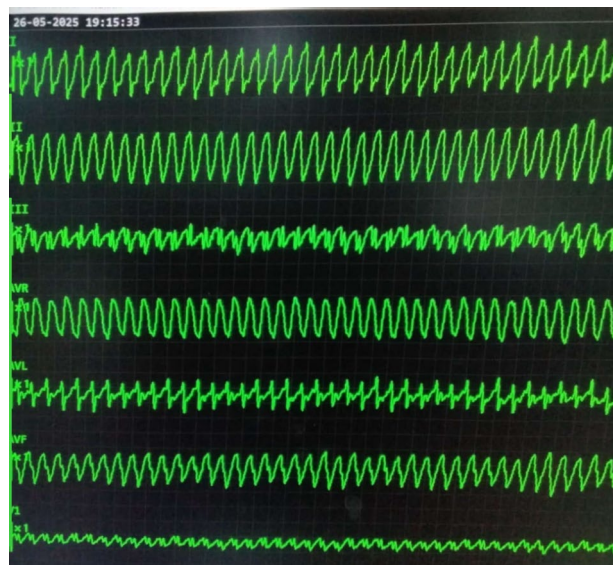


Figure 4. The patient's vital sign monitor showed ventricular tachycardia.

[12INAHRS-CR34]

Successful 3D-Guided Combined Pulmonary Vein Isolation and Cavo-Tricuspid Isthmus Ablation in a Young Male with Paroxysmal Atrial Fibrillation: A Case Report

D. Satriojati¹, R. Julario¹, R. I. Gunadi¹, M. J. Al-Farabi¹

¹*Department of Cardiology and Vascular Medicine, Dr. Soetomo General Academic Hospital, Surabaya, Indonesia*

Background: In young adults presenting with symptomatic palpitations and nondiagnostic Holter monitoring, an invasive electrophysiological (EP) study may reveal latent atrial tachyarrhythmias. Early identification and subsequent ablation could be particularly beneficial in individuals with underlying metabolic risk factors that contribute to atrial remodeling.

Case Illustration: A 35-year-old man presented with a two-year history of palpitations and a single episode of blackout. His comorbidities included class I obesity (body mass index 31), type 2 diabetes mellitus, hyperlipidemia, and mild coronary artery disease. A 24-hour Holter recording revealed sinus rhythm with infrequent PVCs and PACs. The highest-grade supraventricular event was paroxysmal supraventricular tachycardia (SVT), possibly atrial tachycardia (6 beats at 120 bpm). The patient was planned to undergo EP study and 2D ablation. The EP study, utilizing 2D mapping, revealed inducible paroxysmal atrial fibrillation (AF) and typical atrial flutter. Subsequently, the patient was planned for 3D ablation. A repeat EP study with 3D mapping was performed. Wide-area circumferential pulmonary vein isolation (PVI) was performed using point-by-point radiofrequency ablation (45–50 W, 45°C, 10 seconds/lesion, impedance 300 Ω). All four pulmonary veins (RSPV, RIPV, LSPV, LIPV) showed complete entrance and exit block post-ablation. Typical atrial flutter was spontaneously induced during the procedure. Pre-ablation conduction times were LLRA–CSO 70 ms and CSO–LLRA 64 ms. Cavo-tricuspid isthmus (CTI) ablation was delivered at 40 W, 50°C for 200 seconds. Post-ablation conduction times were LLRA–CSO 142 ms and CSO–LLRA 144 ms, confirming bidirectional CTI block. The procedure was completed without complications. Despite the absence of sustained arrhythmia on ambulatory ECG, prior EP revealed inducible AF and flutter, justifying early substrate elimination. High-power, short-duration RF ablation with 3D mapping allowed safe, effective PVI and CTI block in a single session. Early intervention may be particularly important in young patients with metabolic risk factors to reduce progression and recurrence.

Conclusion: 3D-guided PVI and CTI ablation is a safe and effective approach in young patients with inducible paroxysmal AF/flutter despite nondiagnostic Holter monitoring. In patients with metabolic comorbidities, early invasive evaluation and tailored ablation may offer long-term symptomatic relief and arrhythmia suppression.

Keywords: Atrial Fibrillation; Atrial Flutter; Pulmonary Vein isolation; Cavo-Tricuspid Isthmus ablation; Young adult arrhythmia

[12INAHRS-CR35]

Ratchet Syndrome: A Rare Cause of Left Ventricular Lead Cardiac Resynchronization Therapy Defibrillator Dislodgement

Hasannudin^{1,3}, D.Y. Hermanto^{1,2}, S.B. Raharjo^{1,2}, D.A. Hanafy^{1,2};

¹National Cardiovascular Center Harapan Kita, Jakarta, Indonesia

²Faculty of Medicine Universitas Indonesia, Jakarta, Indonesia

³Undata Hospital, Palu, Indonesia

Background: Cardiac resynchronization therapy defibrillators (CRTDs) have been shown to reduce recurrent hospitalization and improve survival in selected symptomatic patients with systolic heart failure. However, among CRTD recipients, lead dislodgement, particularly of the left ventricular (LV) lead, occurs more frequently than with non-LV leads. We report a case of LV lead dislodgement following CRTD implantation.

Case Illustration: A 54-year-old woman with non-ischemic cardiomyopathy (LV ejection fraction of 14%), left bundle branch block (QRS duration of 150 ms), and NYHA class III symptoms underwent CRTD implantation in 2024. The device implanted was a St. Jude Quadra Assura MP CD 3371-40qc with the following leads: right ventricular (RV) lead - Medtronic SPRINT QUATTRO MRI 6935M-62 cm, LV lead - St. Jude Quartet 1458Q-86 cm, and right atrium (RA) lead - Medtronic CAPSUREFIX Novus MRI 5076-52 cm.

Eight months post-implantation, the patient presented with chest discomfort and involuntary movement of the left shoulder. Device interrogation revealed loss of biventricular pacing secondary to dislodgement of the LV lead. Chest radiography demonstrated cardiomegaly and revealed that the LV lead had retracted and coiled within the device pocket, whereas the RA and RV leads remained in proper position (Figure 1). This rare complication is consistent with *ratchet syndrome*, a mechanism of lead dislodgement and retraction resulting from ratchet-like movement of the lead through a loose suture sleeve, leading to gradual retraction with body movements.

Conclusion: This case highlighted a rare instance of LV lead dislodgement resulting from the ratchet mechanism, attributed to inadequate tightening of the suture sleeve. Both conscious and unconscious arm or shoulder movements can contribute to this complication. During CRTD implantation or lead replacement procedures, careful attention should be paid to securing and reconfirming the tightness of the lead fixation sleeve to prevent such events.

Keywords: ratchet syndrome, CRTD, complication, left ventricular lead dislodgement.

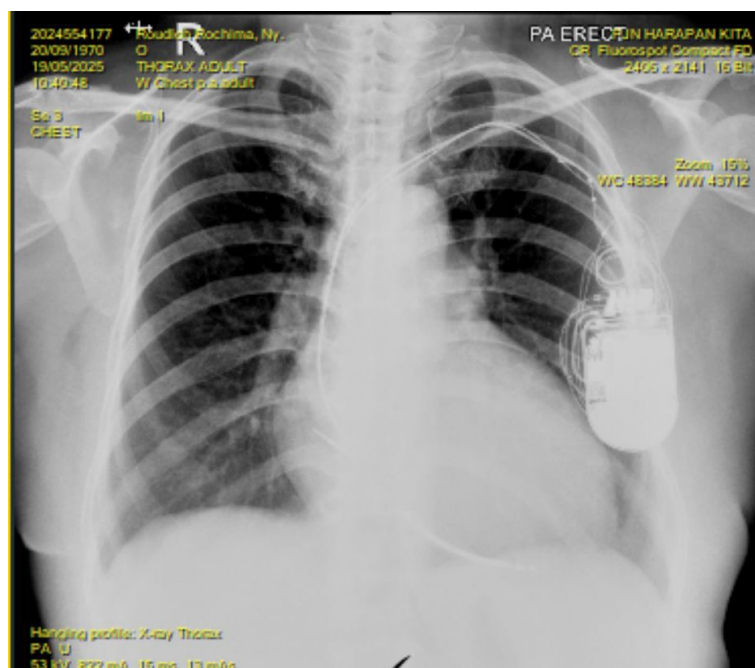


Figure 1. Chest X-Ray.

[12INAHRS-CR36]

Beyond Coronary Arteries: Painful Left Bundle Branch Block Syndrome, an Uncommon Cause of Chest Pain

J.P. Sianipar¹, A. Yudha¹, M. Heltha¹, P. Ardhianto¹, A. Y. A. B. Mochtar¹

¹Cardiology and Vascular Dept., Faculty of Medicine, University of Diponegoro

Background: Chest pain syndrome associated with intermittent left bundle branch block (LBBB) in the absence of myocardial ischemia has been described and later labeled “painful LBBB syndrome.” The mechanisms and treatment options for painful LBBB syndrome remain unclear. A faster heart rate may allow an impulse to reach left ventricular myocytes during the refractory period, initiating ventricular contraction in the right ventricle before the left, thereby inducing transient dyssynchrony, a characteristic feature of LBBB.

Case Illustration: A 54-year-old man was referred to Kariadi Hospital presenting with severe chest pain experienced four hours prior to admission during an episode of activity. The pain was described as a heavy pressure, lasting more than 30 minutes and not resolving with rest. An ECG from the previous hospital during a chest pain episode showed sinus rhythm, a heart rate of 95 bpm, a leftward axis with LBBB, and an anterior S/T ratio of 1.8. Physical examination findings were within normal limits. During an episode of chest pain, we performed an ECG that revealed sinus rhythm, a heart rate of 80 bpm, a leftward axis with LBBB, and an anterior S/T ratio of 1.4. Coronary angiography was performed, revealing normal coronary arteries. The patient was treated with 2.5 mg of bisoprolol and transferred to the ward for monitoring. A repeat ECG following resolution of chest pain demonstrated resolution of LBBB morphology, sinus rhythm at 70 beats per minute, a normal axis, and an inverted T wave in precordial leads. The patient’s chest pain improved, and he was discharged with bisoprolol therapy.

Conclusion: Left bundle branch block syndrome is an infrequent cause of angina and should be considered in the absence of evidence of coronary artery disease or cardiomyopathies that could explain the symptoms. Current management guidelines are undefined, and several therapeutic strategies have yielded unsatisfactory results.

Keywords: chest pain, LBBB, normal coronary artery

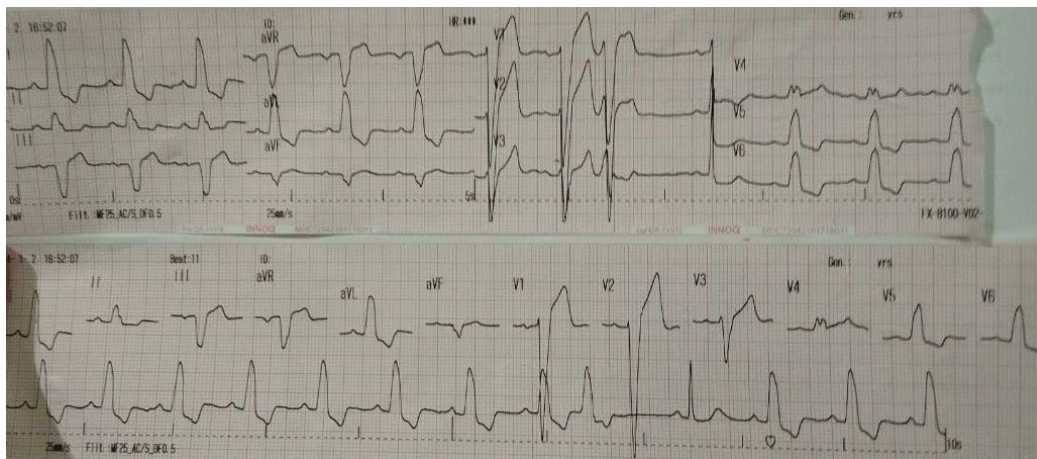


Figure 5. ECG in ER Kariadi Hospital during an episode of chest pain.

[12INAHRS-CR37]

Recurrent Supraventricular Tachycardia Following Carboplatin-Docetaxel Chemotherapy: A Hidden Threat in High-Risk Cancer Survivors

NME Mayasari¹, M Lerista², NK Abelfa¹

¹Faculty of Medicine Muhammadiyah Palembang University/ Muhammadiyah Palembang Hospital

²Faculty of Medicine Sriwijaya University

Background: As cancer survival rates improve, oncologists and cardiologists increasingly face the challenge of chemotherapy-induced cardiotoxicity. Although anthracyclines are well-established culprits, platinum-based agents, such as carboplatin, are frequently overlooked as arrhythmogenic triggers. However, when combined with taxanes, such as docetaxel, their cardiotoxic potential may be amplified. This case illustrates a rare, life-threatening occurrence of recurrent supraventricular tachycardia (SVT) in a high-risk patient, highlighting the under-recognized cardiovascular risks associated with non-anthracycline regimens.

Case Illustration: A 57-year-old man with hypertension, diabetes, a prior stroke, and a history of nasopharyngeal carcinoma treated with six cycles of carboplatin-docetaxel presented with acute chest pain and palpitations. ECG revealed unstable SVT requiring synchronized cardioversion, followed by two recurrent episodes in the ICU. Echocardiography showed preserved LVEF (69%) but reduced strain (Δ GLS 23.8%) and prolonged QTc (480 ms), indicating subclinical myocardial injury. Laboratory markers and electrolytes were within normal limits. After stabilization with bisoprolol, amiodarone, and dual antiplatelet therapy, coronary angiography revealed a subtotal proximal LAD occlusion, successfully managed with PCI. The case fulfilled criteria for high-risk HFA–ICOS cardiotoxicity and likely secondary CTIA—chemotherapy-triggered arrhythmia in a structurally vulnerable heart. The patient remained hemodynamically stable and was discharged after five days of inpatient care. Although electrophysiologic studies were not performed, this limitation underscores the importance of rhythm surveillance in cardio-oncology.

Conclusion: This case highlights the need for increased vigilance in detecting arrhythmic complications in cancer survivors, particularly those receiving platinum-based and taxane chemotherapy. Even in the absence of prior structural heart disease, pre-existing cardiovascular risk factors can synergize with chemotherapeutic toxicity to precipitate life-threatening arrhythmias, such as supraventricular tachycardia. Early identification, utilizing advanced imaging (e.g., strain echocardiography), and aggressive rhythm management are critical to reducing morbidity and mortality. As cardio-oncology continues to evolve, multidisciplinary collaboration and individualized risk stratification are essential for optimizing care in this vulnerable population.

Keywords: Cardiotoxicity, Carboplatin, Docetaxel, Supraventricular tachycardia, chemotherapy-induced

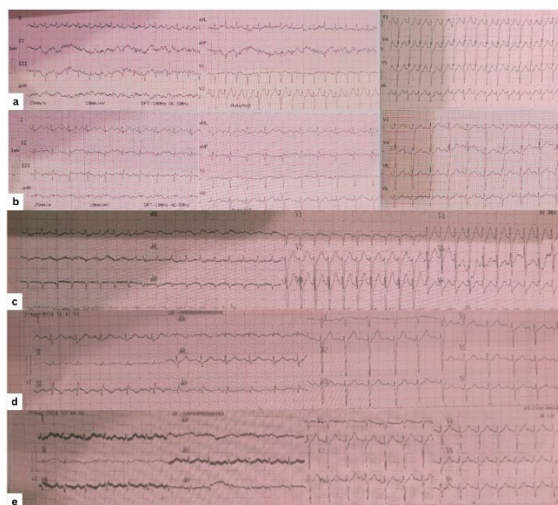


Figure 1. Collective findings of patient Pre-cardioversion 1 in the emergency unit; (b) Post-cardioversion 1 in the emergency unit; (c) Pre-cardioversion 2 in the ICU; (d) Post-cardioversion 2 in the ICU; (e) Post-cardioversion 3 in the ICU.

[12INAHRS-CR38]

Thromboembolic Events Following Sinus Rhythm Conversion in Atrial Fibrillation: Two Clinical Manifestations

A.M. Yapanto¹, K. A. Lestari¹, F. D. Maharani¹, E. Zuhri²

¹Faculty of Medicine, YARSI University Jakarta, Indonesia 10510

²Cardiology Department, Pelni Hospital, Jakarta, Indonesia 11410

Background and Aims: Atrial fibrillation (AF) increases the risk of thrombus formation, particularly within the left atrial appendage (LAA), owing to atrial hypo-contraction and stasis. Spontaneous or pharmacologic conversion to sinus rhythm (SR) can trigger thromboembolic events, especially when effective anticoagulation is lacking. This case series reports two male patients who experienced acute embolic complications following SR restoration.

Case illustration:

Case 1: An 82-year-old male. History of paroxysmal AF, hypertensive heart disease, preserved ejection fraction (EF 74%), CHA₂DS₂-VASc score 5. Initial ECG: AF with rapid ventricular response. One day later, spontaneous conversion to SR was documented. Warfarin initiated, but INR 0.98. No heparin bridging. Forty-eight hours post-conversion, the patient experienced sudden-onset left-sided weakness and slurred speech. A brain CT demonstrated a non-hemorrhagic ischemic stroke in the middle cerebral artery distribution. The etiology was determined to be cardioembolism secondary to a left atrial thrombus dislodged post-conversion.

Case 2: A 52-year-old male. History of diabetes, hypertensive crises, advanced systolic heart failure (EF 21%), biatrial enlargement, CHA₂DS₂-VASc score ≥ 4 . ECG: persistent AF with RVR. Administered intravenous amiodarone. Rhythm control was achieved. Five days later: right lower limb pain, coldness, and pulselessness. Doppler ultrasonography revealed occlusion of the right popliteal artery and bilateral anterior tibial stenosis. The patient was diagnosed with acute limb ischemia secondary to distal embolization. Warfarin was newly started. INR status unavailable. No prior peripheral vascular disease.

Both patients developed embolic complications shortly after SR restoration. Pre-conversion transesophageal echocardiography was not performed. No therapeutic INR achieved at event onset. No bridging anticoagulation. The temporal relationship between SR conversion and the embolic event is consistent with atrial stunning and thrombus mobilization.

Conclusion: Conversion to sinus rhythm may transiently improve atrial contractility, mobilizing preformed thrombi. Atrial stunning delays mechanical function recovery, increasing embolic risk. Without adequate anticoagulation, thrombi may dislodge into systemic or cerebral circulation. Stroke and acute limb ischemia represent territory-specific embolization. These cases illustrate that sinus rhythm conversion, even spontaneous, carries a significant embolic risk in unprotected atrial fibrillation. Therapeutic anticoagulation must precede and follow rhythm restoration. Spontaneous SR does not confer safety. Clinicians must maintain anticoagulation vigilance regardless of rhythm status.

Keywords: Atrial fibrillation, sinus rhythm conversion, thromboembolism, ischemic stroke, acute limb ischemia.

[12INAHRS-CR39]

A New Hope for Debilitating Vasovagal Syncope

ARB Sitorus^{1,2}, WS Chee², AR bin Abd Ghani²

¹*Department of Cardiology and Vascular Medicine, Faculty of Medicine, Hasanuddin University, Makassar, Indonesia*

²*Serdang Heart Center, Serdang, Malaysia*

Background: Vasovagal syncope (VVS) is the most common cause of syncope. An exaggerated parasympathetic response to a trigger may induce syncope through bradycardia and hypotension, potentially resulting in cerebral hypoperfusion. Cardioneuroablation (CNA) is a novel interventional procedure used to treat recurrent VVS. By selectively damaging cardiac parasympathetic ganglia, CNA can suppress excessive vagal activity and enhance patient outcomes.

Case Illustration: A 32-year-old male presented with recurrent syncope over 1 year. Syncope episodes were associated with chest discomfort and headache. The physical examination was unremarkable. Electrocardiography showed a normal sinus rhythm. Echocardiography demonstrated preserved ejection fraction and a structurally normal heart. Holter monitoring showed no significant pauses. A head-up tilt test yielded a mixed response. The patient was well informed regarding the pacing indication but expressed reluctance about a long-life pacemaker and opted for cardiac nerve ablation.

General anesthesia was administered. A decapolar catheter was placed into the right jugular vein to deliver extracardiac vagal stimulation (ECVS). A 70 mA ECVS, delivered for 5 seconds, elicited a prolonged sinus pause. A high-density Pentaray mapping catheter was used to map the vagal ganglion plexus (GP) around the Ao-SVC junction. Multiple radiofrequency ablations (RFAs) were performed at 40 watts for 30 seconds, with careful attention to the sinus node and phrenic nerve areas. Heart rate increased by more than 20% from baseline. The right jugular ECVS was subsequently redelivered, and an episode of complete heart block was observed, necessitating left-sided GP ablation. Transseptal puncture was performed under transesophageal echocardiography guidance. The left-sided GP was mapped around the right superior pulmonary vein and the posteromedial left atrium. Multiple RFAs were delivered at 40 watts for 30 seconds. After biatrial CNA, during right ECVS, no more sinus pause and atrioventricular block were noted. Left ECVS was performed with rapid atrial pacing and showed 1:1 conduction @350ms. After CNA, the patient was symptom-free for 6 months and still counting.

Conclusion: Vasovagal syncope is a debilitating cardiovascular condition. Selective atrial ablation of GP may be a promising catheter-based alternative therapy for VVS. Successful vagal denervation could potentially eliminate the need for permanent pacemaker implantation.

Keyword: Vasovagal syncope, Cardio-Neural Ablation

[12INAHRS-CR40]

Acute Pulmonary Embolism Following Radiofrequency Ablation in a Young Asian Female on Hormonal Injection: A Case of Diagnostic and Therapeutic Challenges.

N. N. Triatmojo¹, A. Rizal², S. Anjarwani², N. Kurnianingsih², A. P. Wikananda²

¹Resident of Cardiovascular Medicine, Saiful Anwar Hospital, Malang, Indonesia

²Cardiologist at Saiful Anwar Hospital, Malang, Indonesia

Background: Acute pulmonary embolism (APE) is a rare but severe complication following radiofrequency catheter ablation (RFCA) for arrhythmic disorders, with reported incidences ranging from 0% to 1.7%. Hormonal contraceptive injections, specifically Depot Medroxyprogesterone Acetate, significantly increase the risk of venous thrombosis. Early identification of APE is challenging due to non-specific symptoms, but critical indicators include sudden shortness of breath, chest pain, and loss of consciousness. Timely and tailored treatment, including weight-based dose adjustments for fibrinolytic therapy in Asian patients, is crucial for optimal outcomes.

Case Presentation: We present the case of a 23-year-old Asian female with no prior history of thromboembolic diseases who was on depot medroxyprogesterone acetate for contraception. She underwent an uncomplicated RFCA procedure for frequent premature ventricular contractions. She was immobilized for nine hours post-procedure. Upon her initial attempt to mobilize and walk to the bathroom, she suddenly experienced shortness of breath, chest pain, and a brief loss of consciousness. Her vital signs were unstable: blood pressure, 85/55 mmHg; heart rate, 133 bpm; respiratory rate, 32 breaths/min; and oxygen saturation, 88%. Echocardiography demonstrated right ventricular dilatation and a positive McConnell sign. CT pulmonary angiography confirmed a filling defect in the left pulmonary artery, leading to an APE diagnosis. Considering her Asian ethnicity and low body mass index, the patient was successfully treated with a reduced dose of alteplase (50 mg) administered over two hours to minimize bleeding risk. Her vital signs stabilized during fibrinolytic therapy, with no hemorrhagic complications. Following three months of oral rivaroxaban treatment, follow-up CT pulmonary angiography revealed complete resolution of the embolism.

Conclusion: This case highlights that APE, though rare, represents a serious complication of RFCA, particularly when combined with prolonged immobilization and hormonal contraceptive use. The abrupt onset of symptoms, including shortness of breath and loss of consciousness upon initial mobilization, is a critical indicator of acute PE. Early mobilization within 2-4 hours post-RFCA is indicated to minimize the risk of embolism. Individualized treatment strategies, such as weight-based fibrinolytic dosing, are essential for managing APE in specific patient populations to optimize efficacy and safety. Clinicians should exercise caution when treating patients using hormonal contraception undergoing procedures involving vascular puncture.

Keywords: Pulmonary Embolism, Venous Thromboembolism, Radiofrequency Catheter Ablation, Hormonal Contraception, Thrombolysis

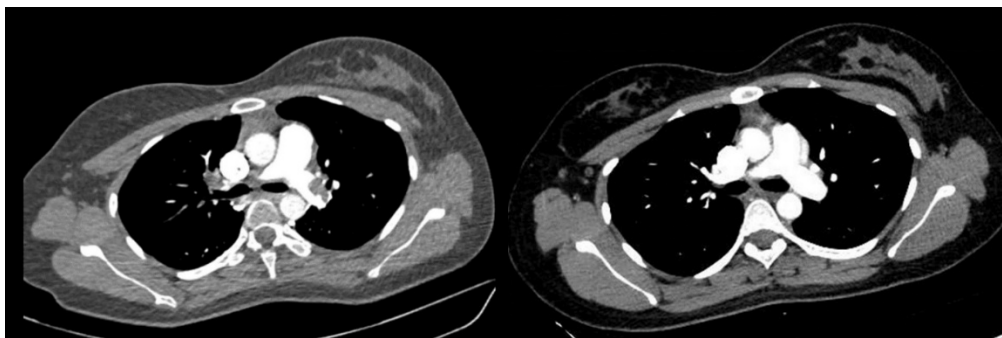


Figure 1. CT Pulmonary Angiography (CTPA) findings. (Left) CTPA revealed an acute pulmonary embolism characterized by a filling defect in the left pulmonary artery. (Right) A follow-up CTPA, three months after fibrinolytic therapy and direct oral anticoagulant (DOAC) treatment, demonstrated resolution of the thrombus.

[12INAHRS-CR41]

From Fibrillation to Frustration: Bradycardia Risk After Natural Termination

B. Ardell¹, S.D. Putra²

¹General Practitioner in Rumah Sakit Pusat Pertahanan Negara (RSPPN) Soedirman, Jakarta

²Cardiologist in Rumah Sakit Pusat Pertahanan Negara (RSPPN) Soedirman, Jakarta

Introduction: Atrial fibrillation with rapid ventricular response typically necessitates immediate intervention; however, its spontaneous termination can unleash equally perilous consequences. We present a remarkable case that presented to our emergency department initially as routine atrial fibrillation management. Nevertheless, what unfolded was an extraordinary demonstration of cardiac electrophysiology's unpredictable nature—where the treatment became as dangerous as the underlying condition itself, challenging our fundamental understanding of post-conversion complications and redefining emergency cardiac care protocols.

Case Report: A 72-year-old woman presented with acute-onset, sharp left-sided chest pain and persistent palpitations, necessitating emergent evaluation. Initial assessment revealed hemodynamic instability, characterized by hypertension, irregular tachycardia (151 bpm), tachypnea, and hypoxemia. Supplemental oxygen was administered to maintain adequate arterial oxygen saturation. Electrocardiographic analysis confirmed atrial fibrillation with rapid ventricular response as the underlying cardiac dysrhythmia. Continuous cardiac monitoring demonstrated spontaneous cardioversion from atrial fibrillation to junctional rhythm within hours of the initial presentation. However, the patient subsequently developed intermittent episodes of sinus arrest.

Conclusion: Following spontaneous atrial fibrillation termination, our patient demonstrated the remarkable phenomenon of post-conversion pause, a transient sinus node suppression, resulting from enhanced $\text{Na}^+\text{-K}^+$ ATPase activity and disrupted ionic homeostasis creating an "electrical refractory period." During this critical phase, subsidiary pacemakers are activated by progressive phase 4 depolarization through hyperpolarization-activated cyclic nucleotide-gated (HCN) channels and L-type calcium currents, generating escape rhythms as backup systems for the heart. This electrophysiological cascade, compounded by age-related sinoatrial node degeneration and potential ischemic conditioning, creates a scenario conducive to sequential rhythm disturbances. This case exemplifies the remarkable resilience and vulnerability of the aging cardiac electrical system, demonstrating how the heart can simultaneously exhibit sophisticated backup mechanisms while revealing the fragility of its primary pacemaker function in elderly patients.

Keywords: Atrial Fibrillation, Sinus Node Dysfunction, Post-conversion Pause

[12INAHRS-CR42]
Posterior Idiopathic Left Ventricular Tachycardia Caught in Action!

J. A. Setiawan¹, A. I. Supit¹

¹Department of Cardiology, RSUD dr. Soedarso, Pontianak, Indonesia

Background: Idiopathic Left Ventricular Tachycardia (ILVT) is an uncommon ventricular arrhythmia characterized by its occurrence in the absence of structural heart disease. It typically affects young individuals and originates from the Purkinje system, frequently involving the posterior fascicle. Here, we present a case of documented ILVT and its management.

Case Illustration: A 23-year-old male presented with recurrent palpitations accompanied by mild chest pain. ECG showed regular wide QRS complex tachycardia, with RBBB morphology, left axis deviation, and captured beat, suggestive of fascicular VT rather than SVT with aberrancy (Fig. 1A). IV diltiazem was administered to terminate tachycardia. Echocardiography revealed no structural and functional abnormalities.

The patient underwent an electrophysiology study incorporating three-dimensional electroanatomical mapping and local activation time (LAT) mapping, utilizing a duodecapolar catheter. Purkinje potential was recorded in the distal to proximal left posterior fascicle area. Radiofrequency ablation (RFA) was performed at the site of earliest activation using an irrigated-tip catheter. RF applications were delivered targeting the area of the reentry circuit. Following ablation, aggressive ventricular stimulation failed to induce ventricular tachycardia (VT), indicating procedural success. The patient reported no recurrence of palpitations at follow-up.

Conclusion: ILVT is a curable arrhythmia typically occurring in structurally normal hearts. Three-dimensional mapping facilitated precise localization of the arrhythmogenic substrate, enabling targeted ablation guided by Purkinje potential identification. Catheter ablation successfully eliminated inducible ventricular tachycardia. Timely diagnosis and precise mapping are therefore key to optimal management outcomes.

Keywords: ILVT; 3D ablation; catheter ablation

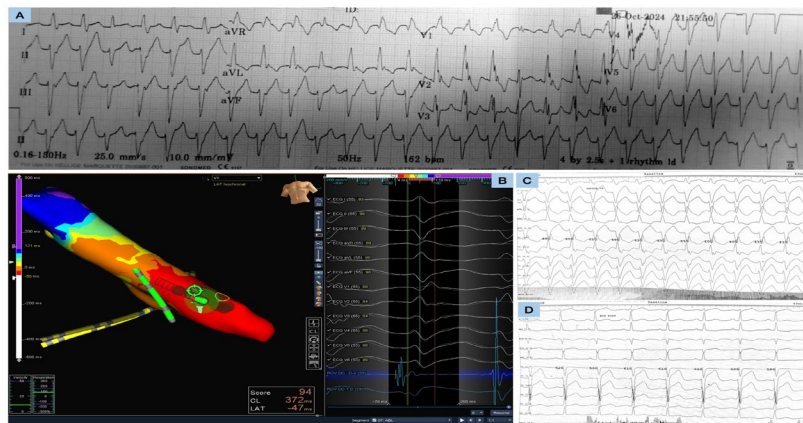

Figure 1. (A) ECG during VT; (B) 3D electroanatomical mapping of the site of activation; (C) Induced VT during EPS; (D) Post-procedural EGM.

[12INAHRS-CR43]
From Infection to Cure: Successful Treatment of Cardiac Implantable Electronic Device Infection (CIEDI)

D. Y. Kurniawan¹, P. Ardhianto¹, A. Y. A. B. Mochtar¹

¹*Department of Cardiology and Vascular Medicine, Kariadi General Hospital, Semarang, Indonesia*

Introduction: Cardiac implantable electronic device (CIED) infections are a serious complication associated with significant morbidity, mortality, and healthcare costs. Management is complex and typically requires a multidisciplinary approach, often involving complete device extraction and prolonged antibiotic therapy.

Case Illustration: A 63-year-old male presented with a one-week history of progressive pain, erythema, and purulent discharge from the permanent pacemaker pocket site. He had a history of type 2 diabetes, hypertension, smoking, and dyslipidemia. On examination, the right infraclavicular pocket was tender and warm, exhibiting skin erosion.

Laboratory tests revealed elevated inflammatory markers. Transthoracic echocardiography did not demonstrate any vegetations. Both blood and pocket swab cultures grew *Corynebacterium resistens*, confirming a CIED infection. The patient was initiated intravenous vancomycin. A multidisciplinary team, including an electrophysiologist, an infectious disease specialist, and a cardiothoracic surgeon, recommended complete system extraction. The permanent pacemaker generator and both leads were successfully extracted.

Following device extraction, the patient's signs of infection resolved. He completed a one-week course of intravenous vancomycin. A new, single-chamber permanent pacemaker was implanted on the contralateral side one week after the initial extraction, following confirmation that blood cultures remained negative for at least 72 hours. The patient was discharged in stable condition and remained infection-free at his three-month follow-up.

Conclusion: CIEDI represents a serious complication necessitating prompt recognition and aggressive management. Complete system extraction, combined with appropriate antibiotic therapy, is the standard of care and is associated with a high cure rate. This case demonstrates the successful application of these principles in a high-risk patient.

Keywords: Cardiac Implantable Electronic Device Infection (CIEDI), Pacemaker Infection, Device Extraction, Corynebacterium resistens

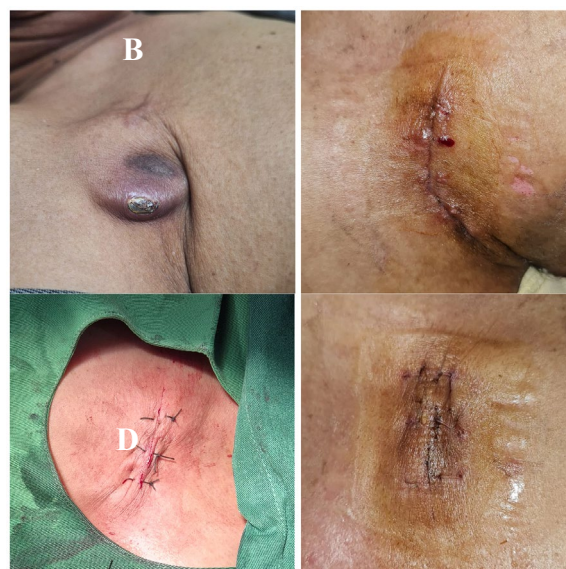


Figure 1. Presentation of wound of permanent pacemaker insertion in patient. (A) Right infraclavicular skin erosion with small part of permanent pacemaker was exposed, (B) Right infraclavicular 2 weeks after debridement, (C) Left infraclavicular region after contralateral pacemaker implantation, (D) Left infraclavicular region during follow-up 1 week after pacemaker implantation.

[12INAHRS-CR44]

Amyloidosis: The Mimicking Rhythm of Total Atrioventricular Block

Thengker A.¹, Kristianti S.¹, Aristo N.¹, Setiadi B. M.¹

¹Department of Cardiology and Vascular Medicine, Prof. Dr. R. D. Kandou Hospital – Faculty of Medicine, Sam Ratulangi University, Manado, North Sulawesi, Indonesia

Background: Conduction defects are prevalent in cardiac amyloidosis (CA), a condition characterized by the extracellular deposition of amyloid fibrils in tissues. CA is associated with increased left ventricular mass and diastolic dysfunction. The twelve-lead electrocardiogram (ECG) remains a valuable diagnostic tool in CA patients. Atrioventricular (AV) conduction delay is more frequently observed than sinus node dysfunction. First-degree AV block is typically attributable to a delay within the His-Purkinje system, and approximately 25–45% of patients require pacemaker implantation. Often, long PR first-degree AV block can lead to or mimic high-degree AV block.

Case Presentation: A 71-year-old male came to the Cardiovascular department of Prof. Dr. R. D. Kandou Hospital, Manado, North Sulawesi, with dyspnea and weakness. Electrocardiogram showed high-degree AV block, Echocardiogram showed concentric Left Ventricular Hypertrophy, Left Ventricular Ejection Fraction of 41%, Tricuspid Anulus Plane Systolic Excursion 1,1 cm. Electrophysiology study showed SNRT 1024 ms and a prolonged 477 ms A-H interval without AV dissociation. Between two subtypes of CA, transthyretin CA are cytotoxic to myocardial cells and lead to sympathetic denervation, which have higher incidence of symptomatic AV block and pacemaker implantation. Differentiating High-degree AV block from long PR-first-degree AV block can be challenging. It often requires an electrophysiology evaluation for diagnosis, which can lead to the suspicion of one of the subtypes of Cardiac Amyloidosis.

Conclusions: Electrophysiology studies are needed to differentiate between high-degree AV block in ECG and long PR-first degree AV block, which can also be suspected subtype diagnosis of CA in rural areas with limited examinations.

Keyword: Amyloidosis, AV block, Mimicking

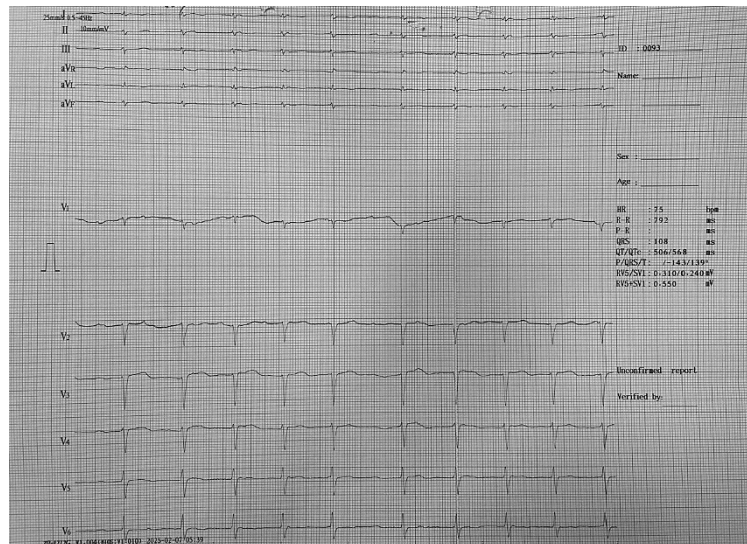


Figure 1. ECG showed High Degree AV Block.

[12INAHRS-CR45]

Conduction System Pacing in a Young Patient with Atrial Standstill: A Rare Case Report

M Lerista¹, AE Tondas^{1,2}

¹Department of Cardiology and Vascular Medicine, Dr Mohammad Hoesin General Hospital, Palembang, Indonesia

²Faculty of Medicine, Universitas Indo Global Mandiri (UIGM), Palembang, Indonesia

Background: Atrial standstill is an uncommon and severe form of arrhythmia defined by the absence of atrial electrical and mechanical activity, caused by mutations in NPPA, TAF1A, LMNA, and most commonly the SCN5A gene. This condition can lead to profound bradycardia, reduced cardiac output, and an increased risk of sudden cardiac death. Its occurrence in young individuals is uncommon, and optimal pacing strategies remain under investigation. Conduction system pacing (CSP) has emerged as a more physiological pacing modality, demonstrating promising results in patients with atrial or sinoatrial node dysfunction.

Case Illustration: A 20-year-old male presented with exertional dyspnea, dizziness, and fatigue. He reported no history of chest pain, palpitations, fever, or structural heart disease. Prior to admission, he had experienced bradycardia for 2 years, though he was lost to follow-up due to minimal symptoms. Vital signs on admission revealed a heart rate of 40 bpm and a blood pressure of 120/90 mmHg. An episode of atrial fibrillation was recorded on serial ECGs. Electrocardiography showed a junctional rhythm and absent P waves. Other physical examination and echocardiography were unremarkable.

An electrophysiology study (EPSL) confirmed an AV nodal rhythm and the absence of atrial excitability during pacing of the right atrium. A diagnosis of complete and persistent atrial standstill was established. No other inducible tachy-brady arrhythmia was observed during EPSL. Given the symptomatic nature of the bradycardia and the patient's inability to pace the atrium, a single-chamber ventricular-ventricular inhibited (VVIR) pacemaker was implanted. Considering the patient's age, an attempt at catheter-based pacing (CSP) was undertaken to prevent heart failure due to the anticipated prolonged pacing lifetime. A pacemaker lead was implanted using the stylet-driven lead (SDL) technique into the left bundle branch (LBB), resulting in selective LBB pacing, with a QRS duration of 110 ms and left ventricular activation time (LVAT) of 60 ms on the V6 lead.

Conclusion: This case highlights the importance of early recognition and pacemaker intervention in cases of atrial standstill disease, particularly in young patients. Conduction system pacing represents a more physiologic and effective long-term pacing site alternative, preserving ventricular synchrony while addressing severe bradycardia resulting from atrial inactivity.

Keywords: Atrial standstill, SCN5A gene, conduction system pacing, left bundle branch pacing

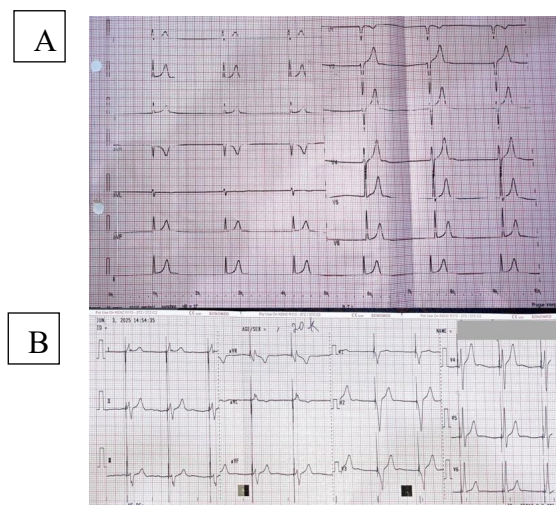


Figure 1. ECG findings (A) before PPM; (B) after PPM.

[12INAHRS-CR46]

New-Onset Atrial Fibrillation in STEMI Inferior with Bradycardia: A Case Report from Type-D Hospital

A.R. Ismail¹, V.R. Kumala¹, G.W. Pradipta², A.D. Harmoko³

¹Internship Doctor, Muhammadiyah Selogiri Hospital, Wonogiri

²Internship Doctor, Simo General Hospital, Boyolali

³Cardiologist, Muhammadiyah Selogiri Hospital, Wonogiri

Background: New-onset atrial fibrillation (NOAF) occurs in up to 10% of patients with ST-elevation myocardial infarction (STEMI) and is associated with increased morbidity and mortality. The pathophysiology involves atrial ischemia, autonomic imbalance, and elevated atrial pressure. Notably, when NOAF develops following initial bradycardia, it can obscure evolving infarction signs. This case highlights the need for dynamic electrocardiographic evaluation and timely intervention, even in type D hospitals.

Case Illustration: A 75-year-old man presented to the emergency room with a chief complaint of chest pain, similar to being crushed by a heavy object, for 1 hour before admission. The chest pain was continuous, radiating to the back and left shoulder, and accompanied by a sensation of penetration. The patient was lethargic and diaphoretic. He denied a history of syncope. The patient had uncontrolled hypertension.

The patient was conscious, with vital signs of BP 167/117 mmHg, HR 47 bpm, RR 20 breaths per minute, and SpO₂ 93% on room air. In the ER, ECG showed sinus bradycardia 44 bpm, normoaxis, T inversion (+) II, III, aVF; V4-V6, ST elevation (-). A thorax X-ray demonstrated cardiomegaly with aortosclerosis. The patient was diagnosed with unstable angina pectoris accompanied by symptomatic bradycardia. Subsequently, the patient received sulfas atropine, heparinization, and supportive therapy. Two hours after hospitalization, the patient's chest pain diminished, and the ECG transitioned to atrial fibrillation with rapid ventricular response (RVR) at 120 bpm, accompanied by a normal axis, ST-segment elevation in leads II, III, and aVF, and ST-segment depression in leads V2-V4, indicative of an acute myocardial infarction in the inferior region. The patient was then transferred to a tertiary care hospital for percutaneous coronary intervention (PCI). Angiography results showed critical stenosis of the proximal RCA with a thrombus (+), and 80% stenosis in LCx. The patient then underwent PCI 1-DES proximal-mid RCA TIMI Flow III. Three days later, the patient's condition was stable, and he was discharged.

Conclusion: This case illustrates that new-onset atrial fibrillation following initial bradycardia can be an early marker of evolving inferior STEMI. Prompt recognition via serial electrocardiograms and timely referral for reperfusion therapy are crucial, even in resource-limited settings.

Keywords: *New-onset atrial fibrillation (NOAF), ST-elevation myocardial infarction (STEMI) inferior, bradycardia*

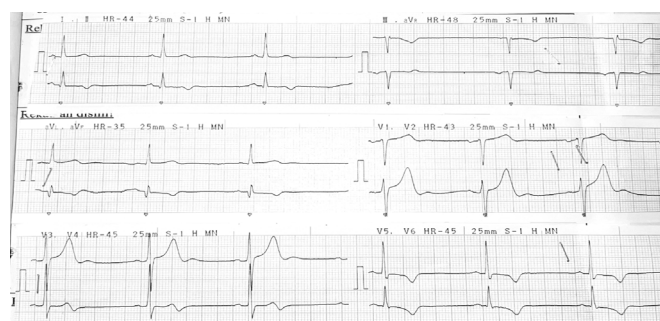


Figure 1. ECG in the emergency room showed sinus bradycardia 44 bpm, normoaxis, T inversion (+) II, III, aVF; V4-V6, ST elevation (-).

[12INAHRS-CR47]

Unmasking Acute Myocarditis in a Male Patient with Pulmonary Tuberculosis: A Case Report

B. P. T. Samudera¹, W. Rustanto²

¹*Emergency Department, Daan Mogot Army Hospital, Tangerang, Indonesia*

²*Faculty of Medicine, University of Surabaya, Surabaya, Indonesia.*

Background: Acute myocarditis, a recent-onset inflammation of the heart, exhibits heterogeneous clinical presentations, ranging from mild symptoms to high-risk cardiac conditions including severe heart failure, refractory arrhythmias, and cardiogenic shock. Although fever is known to induce acute myocarditis, this case report details a rare instance where acute myocarditis was specifically induced by pulmonary tuberculosis.

Case Illustration: A 53-year-old man presented to the Daan Mogot Army Hospital with an 8-day history of productive cough, hemoptysis, fever, progressive dyspnea, palpitations, weakness, chest pain, nausea, and vomiting. Past medical history: He had an emergency due to hypertension. Physical examination revealed a blood pressure of 155/82 mmHg, a heart rate of 115 beats per minute, a respiratory rate of 28 breaths per minute, an oxygen saturation of 85% on room air, and a temperature of 38.6 °C. Cardiovascular examination revealed an apical beat at the fifth intercostal space on the lateral midclavicular line and bilateral rhonchi. Initial laboratory workup demonstrated a hemoglobin of 12.8 mg/dL, a leukocyte count of 15,200/mm³, a platelet count of 326,000/mm³, a C-reactive protein level of 34 mg/dL, and normal serum electrolytes. Electrocardiography showed atrial fibrillation with rapid ventricular response, chest radiography showed cardiomegaly and multiple diffuse patchy infiltrates in bilateral lung fields. Management consisted of intravenous antibiotics, antipyretics, diuretics, and beta-blockers. His condition stabilized, and he was discharged after four days of isolation.

Conclusion: The rare case of acute myocarditis caused by pulmonary tuberculosis is uncommon and may lead to increased morbidity. It was identified through clinical examination, laboratory tests, electrocardiography, chest radiography, and echocardiography. This case should be considered early to ensure timely diagnosis, appropriate management, and improved outcomes.

Keyword: Myocarditis, Pulmonary Tuberculosis, Diagnostic Challenge

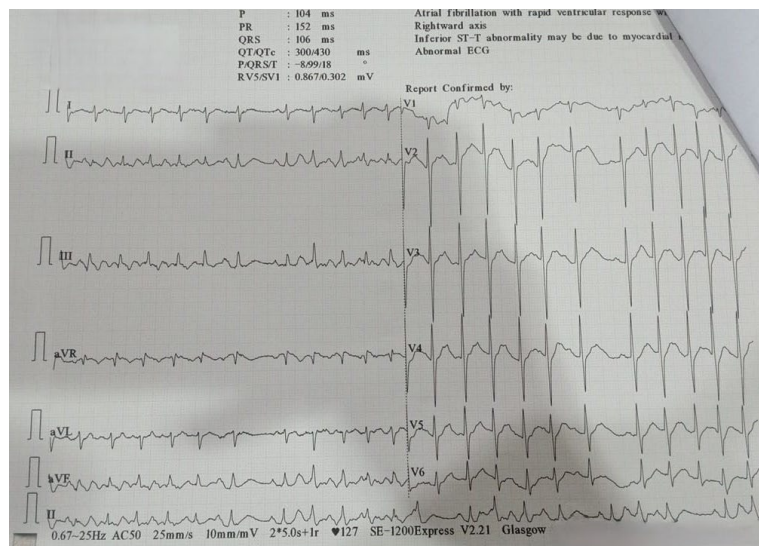


Figure 1. ECG showing atrial fibrillation rapid ventricular response.

[12INAHRS-CR48]

Symptomatic Sinus Arrest in a Post-Coronary Artery Bypass Graft Surgery Patient with Multiple Comorbidities: A Pacing Challenge

C. Milla¹, M.J. Al-Farabi^{2,3}, B. Baktijasa³, R. I. Gunadi³

¹Faculty of Medicine, Universitas Airlangga

²Cardiovascular Research and Innovation Center, Universitas Airlangga, Surabaya, Indonesia

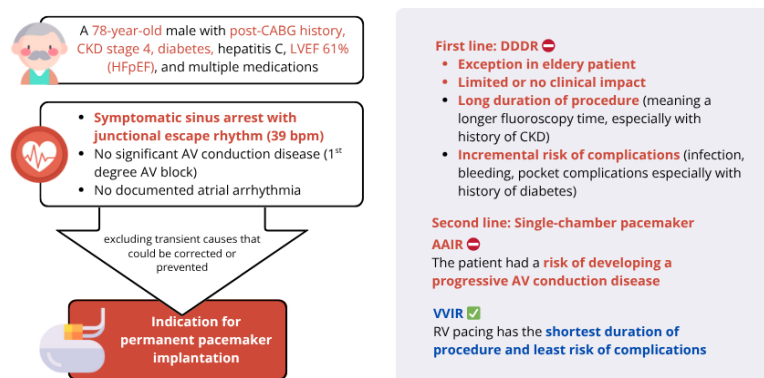
³Department of Cardiology and Vascular Medicine, Dr. Soetomo General Academic Hospital, Surabaya, Indonesia

Introduction: Sinus arrest is a common cause of symptomatic bradyarrhythmia in elderly patients, particularly those with structural heart disease. Managing sinus arrest in a patient with multiple comorbidities and a prior coronary artery bypass graft (CABG) necessitates an individualized pacing strategy to minimize procedural risks. This case illustrates the management challenges encountered in a post-CABG patient with multiple comorbidities.

Case Illustration: A 78-year-old male with a history of three-vessel disease and coronary artery bypass grafting (CABG) in 2006 presented with light-headedness, dizziness, and dyspnea on exertion. An electrocardiogram revealed sinus arrest with a junctional escape rhythm at 39 beats per minute. His medical history included heart failure with preserved ejection fraction (61%), diabetes mellitus (HbA1c 8.9%), controlled hypertension, hepatitis C, and stage IV chronic kidney disease (eGFR 29.9 mL/min/1.73 m²). Laboratory investigations revealed elevated high-sensitivity troponin (396 ng/L), creatinine (2.37 mg/dL), and hyperkalemia (6.2 mmol/L). Physical examination revealed stable hemodynamics without fluid overload. Echocardiography demonstrated preserved biventricular function (EF 61%) with no significant abnormalities, suggesting bradycardia as the primary cause of his symptoms. Potassium levels were corrected, and the patient was stabilized with temporary pacing (TPM). Post-TPM, an electrocardiogram showed an asymptomatic first-degree atrioventricular block. Considering the patient's age, post-CABG history, comorbidities, and risk of infection, a shorter, lower-risk procedure was selected. Under general anesthesia, the patient underwent implantation of a permanent single-chamber pacemaker (VVIR). Following several attempts, the lead was successfully placed in the right ventricular apex with optimal sensing and capture thresholds (CapSure Sense MRI; impedance: 886 Ω; threshold: 0.4 V; R-wave: 19.7 mV). The generator was set to an amplitude of 2.5 V and sensitivity of 2.8 mV (Sphera SR MRI SureScan). No post-procedural complications were observed.

Conclusion: This case illustrates the challenge of managing symptomatic sinus arrest in elderly patients with prior cardiac surgery and systemic comorbidities, necessitating prompt pacing while minimizing procedural risks. VVIR pacing is favored in such patients to reduce lead-related complications.

Keywords: Sinus arrest; Permanent pacemaker; Coronary artery bypass grafting; Bradycardia; Comorbidity; VVIR



Reference: ESC, 2021

Figure 1. Evidence-Based Decision-Making Pathway.

[12INAHRS-CR49]

Effective Ablation of Slanted Accessory Pathways in Wolff-Parkinson-White Syndrome: A Precision-Based Approach

R. Karimah¹, R. Julario^{2,3}, B. B. Dharmadjati^{2,3}, R. N. Rosyadi^{2,3}, M. R. Amadis^{2,3}, R. I. Gunadi^{2,3}, M. J. Al-Farabi^{2,3}, A. A. R. Sugiarto², A. F. Rachma²

¹Faculty of Medicine and Health, Institut Teknologi Sepuluh Nopember, Surabaya, Indonesia

²Faculty of Medicine, Universitas Airlangga, Surabaya, Indonesia

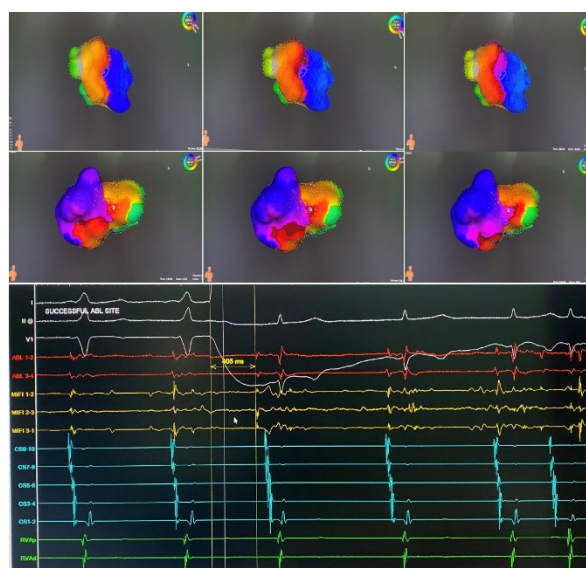
³Department of Cardiology and Vascular Medicine, Dr. Soetomo General Academic Hospital, Surabaya, Indonesia

Background: Wolff-Parkinson-White (WPW) syndrome is caused by the presence of an accessory pathways (APs) that bypasses the normal atrioventricular (AV) conduction system, leading to various forms of supraventricular tachycardia. Some APs actively participate in arrhythmias, while others function as bystanders. Atrial fibrillation in WPW patients can be life-threatening if rapid impulses are conducted through the AP to the ventricles, potentially resulting in ventricular fibrillation and sudden cardiac death. Among the various types of APs, slanted or oblique pathways present a particular challenge during catheter ablation because of their non-perpendicular orientation relative to the mitral or tricuspid annulus. These slanted APs often create anatomical separation between the earliest atrial and ventricular activation sites, thereby complicating accurate mapping and ablation. The likelihood of detecting AP potentials increases when pacing is performed against the slant's orientation (e.g., with longer AV intervals), and careful multisite pacing along the annulus can help infer the presence of a slanted trajectory based on changes in AV or VA intervals. This approach is particularly important for septal pathways, which typically exhibit a superoinferior slant, necessitating strategic pacing from both superior and inferior positions relative to the insertion site to delineate the pathway's course.

Case Illustration: A 28-year-old woman with a history of palpitations was referred for catheter ablation. An ECG showed an AP in the right anteroseptal region, confirmed by retrograde 3D pace mapping, which showed it in the mid-free wall of the right atrium (10 o'clock). Despite multiple radiofrequency ablation (RFA) attempts, intermittent atrioventricular (AV) dissociation persisted. An episode of atrial fibrillation occurred during the procedure and terminated spontaneously, suggesting a high-risk condition. Antegrade 3D pace mapping subsequently identified the pathway in the right mid-free wall (9 o'clock). Subsequent RFA resulted in AV dissociation, a narrow QRS complex, and the absence of a delta wave.

Conclusion: Accurate identification and successful ablation of slanted APs in patients with WPW syndrome require strategic pacing to reveal directional conduction changes, careful mapping along the annular course, and use of high-resolution multielectrode catheter recordings to precisely localize the AP and minimize the risk of collateral damage.

Keyword: wolff-parkinson-white syndrome; slanted accessory pathways; oblique accessory pathways



[12INAHRS-CR50]

Out of Rhythm, Into Isolation: Atrial Tachycardia Resolved by Left Pulmonary Vein Isolation - Case Report

R. Siburian^{1,2}, R. Julario^{1,2}, B. Dharmadjati^{1,2}, R. Rosyadi^{1,2}, R. Gunadi^{1,2}, M. Al-Farabi^{1,2}, J. Arnindita^{1,2}, R. Karimah³

¹Faculty of Medicine, Universitas Airlangga, Surabaya, Indonesia

²Department of Cardiology and Vascular Medicine, Dr. Soetomo General Academic Hospital, Surabaya, Indonesia

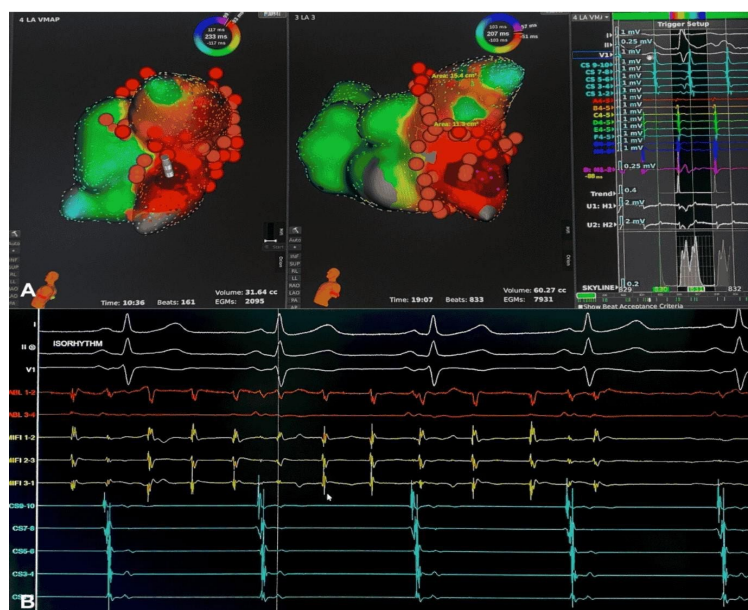
³Faculty of Medicine and Health, Institut Teknologi Sepuluh Nopember, Surabaya, Indonesia

Background: Focal atrial tachycardia (AT) constitutes approximately 10% of supraventricular tachycardia and typically exhibits poor responsiveness to pharmacological interventions. These arrhythmias can originate from various anatomical sites within both atria and their adjacent structures, including the pulmonary veins (PVs), albeit infrequently. Notably, the majority of PV-related AT cases occur on the left side, predominantly at the ostium of a single pulmonary vein, especially the superior PVs. The underlying arrhythmic mechanisms of PV ATs are primarily triggered activity or abnormal automaticity, resulting in a tachycardia cycle length that is generally longer than that observed in atrial fibrillation (AF), which is characterized by diffuse atrial remodeling and various reentrant arrhythmias. Radiofrequency ablation (RFA) for PV AT can be performed either by targeting the AT focus directly or by performing pulmonary vein isolation (PVI). Both approaches yield comparable success and low recurrence rates. The strategy of PVI is often employed in AF ablation due to the presence of multiple and deeper foci within the veins. In contrast, focal RFA for AT is more likely to target the ostium of the PV. However, if the AT focus is located in the distal region of the PV, RFA in that area risks causing phrenic nerve injury and pulmonary vein stenosis.

Case Illustration: A 35-year-old man with a 2-year history of palpitations and documented AT was referred for catheter ablation. Standard transseptal puncture was performed under fluoroscopic guidance. The earliest site of activation was identified in the left superior PV (LSPV) and left inferior PV (LIPV) using 3D mapping. The catheter ablation was advanced into the LIPV, and the LPV was isolated. After 30 minutes of observation, tachycardia could not be re-induced via decremental atrial burst pacing, and the electrogram (EGM) confirmed successful isolation of the LSPV. At the one-month follow-up, the patient was symptom-free, and the electrocardiogram (ECG) was normal.

Conclusion: In this case, we used the PVI approach rather than targeted focal ablation because the AT focus arose from both the distal LIPV and LSPV, resulting in an excellent and secure outcome for the patient.

Keywords: Atrial Tachycardia; Pulmonary Vein Isolation; Supraventricular Tachyarrhythmia



[12INAHRS-CR51]
Brugada Phenocopy in Suspected Hypokalemic Periodic Paralysis

A.Hartono^{1,2}, A.Nandika¹

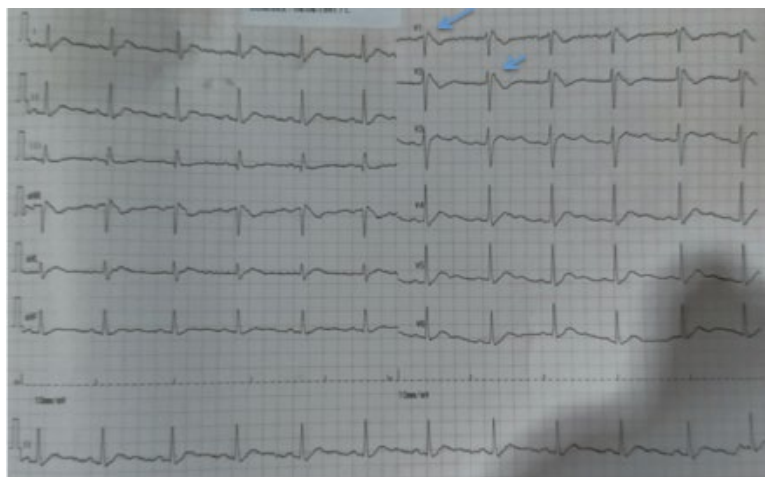
¹Faculty of Medicine, Padjadjaran University, West Java, Indonesia; ²General Practitioner, Kramat 128 Hospital, Jakarta, Indonesia

Background: Brugada phenocopy is an electrocardiogram (ECG) pattern resembling Brugada syndrome, yet it is characterized by reversibility upon resolution of the underlying conditions. This paper presented a case of suspected hypokalemic periodic paralysis (HPP) with Brugada phenocopy

Case Illustration: A 34-year-old male presented with weakness in all four extremities 12 hours prior to admission to our hospital. The weakness began following a large midnight meal. Other symptoms, including fever, nausea, vomiting, diarrhea, dyspnea, cough, palpitations, syncope, and anorexia, were denied. A similar history of bilateral leg weakness and hypokalemia was confirmed by the patient one month prior. There was no family history of similar complaints. Previous chronic conditions (type 2 diabetes, hypertension, asthma, tuberculosis, drug allergy, kidney and liver disease) were denied. Significant findings included bilateral leg weakness (motoric strength grade 2/5) and bilateral arm weakness (motoric strength grade 4/5), with intact sensorium; reduced physiological reflexes in the knee and ankle (+1); and no pathological reflexes. The ECG taken in the ED showed a sinus rhythm with significant coved ST-segment elevation in leads V1-V2 and a visible U wave in leads V3-V6. Laboratory examinations revealed significant hypokalemia (2.1 mEq/L) and mild leukocytosis (12,230 cells/ μ L); however, calcium and magnesium levels were not assessed due to limited resources at our facility. Chest radiography demonstrated normal heart and lung structures, with no significant abnormalities identified. Following potassium chloride supplementation (25 mEq in 500 mL normal saline administered intravenously over 8 hours, followed by 48 hours of oral potassium chloride replacement at 3×600 mg), the potassium level was re-evaluated, resulting in a value of 4.2 mEq/L. A repeat ECG was performed, and the ST-segment elevation in leads V1-V2 normalized.

Conclusion: The Brugada pattern is frequently observed in various clinical circumstances, such as suspected hypokalemic periodic paralysis. Numerous reversible causes should be considered when encountering this pattern on an electrocardiogram.

Keywords: Brugada phenocopy, Brugada syndrome, HPP, hypokalemia



[12INAHRS-CR52]

Bradycardia-Induced Torsades de Pointes in Complete Atrioventricular Block: Clinical Management in Resource-Limited Settings

M. Adityansah¹, K. Adiavira¹, H. Mutha'alimah¹, A. K. Putri², R. Hendiperdana²

¹General practitioner, Pandan Arang General Hospital, Boyolali, Indonesia

²Department of Cardiovascular, Pandan Arang General Hospital, Boyolali, Indonesia

Background: Torsades de pointes (TdP) complicating complete atrioventricular block (CAVB) affects 5–30% of patients, with a mortality rate of 10–20%. Resource-limited healthcare settings face significant challenges due to limited monitoring capabilities and delayed access to definitive therapy.

Case Illustration: A 77-year-old male with hypertension presented with two-month bilateral edema and dyspnea on exertion. Admission vitals revealed a hypertensive crisis (220/110 mmHg) and severe bradycardia (38 bpm). Electrocardiography confirmed CAVB with junctional escape rhythm and frequent premature ventricular contractions. Initial treatment consisted of nitroglycerin, furosemide 40 mg IV, and atropine 2 mg IV, which failed to elicit a response. Subsequently, dopamine 5 mcg was initiated, achieving a heart rate of 48 bpm. During observation, the patient experienced a one-minute seizure with a preserved pulse. Concurrent monitoring documented TdP that spontaneously terminated, resulting in complete heart block. In the absence of magnesium testing, empirical magnesium sulfate (1 g IV) was administered, preventing further TdP episodes. Following stabilization, the patient was referred for urgent permanent pacemaker implantation.

This clinical scenario demonstrates management challenges associated with bradycardia-induced TdP in resource-limited settings lacking laboratory monitoring. Bradycardia downregulates repolarizing currents (IKr, IKs), prolonging the QT interval and predisposing to TdP. A sequential therapeutic approach represents a practical strategy for emergency management under resource constraints. Dopamine prevents TdP by increasing heart rate. Dopamine prevents TdP by increasing heart rate; when chronotropic support proved insufficient, empirical magnesium suppressed early afterdepolarizations by decreasing IKr current. Following successful TdP control, inter-hospital referral highlighted the importance of established networks for definitive pacemaker therapy.

Conclusion: Bradycardia-induced TdP in CAVB can be managed in resource-limited settings utilizing systematic chronotropic support and empirical magnesium therapy as a bridge to definitive treatment. This case demonstrates a practical protocol for empirical magnesium use prior to laboratory confirmation in resource-limited settings.

Keywords: Torsades de pointes, complete atrioventricular block, magnesium sulfate, dopamine, resource-limited settings, emergency cardiology

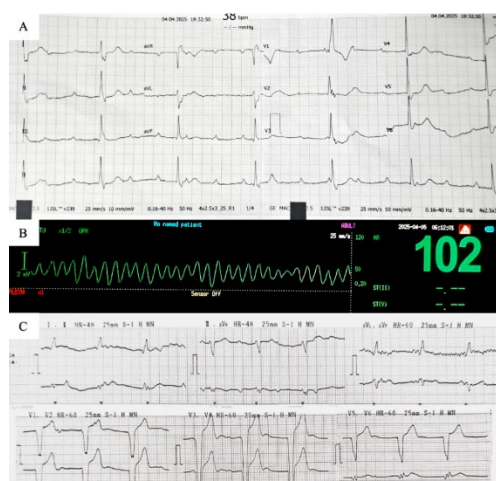


Figure 1. Sequential electrocardiographic progression: A) Complete atrioventricular block with a junctional escape rhythm; B) Torsades de Pointes episode; C) Stable ventricular pacing rhythm following pacemaker implantation.

[12INAHRS-CR53]

First Contact Discovery: SMART-WPW Algorithm Pinpoints an Accessory Pathway in a Young Male at a Primary Care Clinic

E. Siregar¹

Faculty of Medicine, Universitas Malikussaleh, North Aceh, Indonesia.

Background: Wolff-Parkinson-White (WPW) syndrome is characterized by ventricular pre-excitation through an accessory pathway (AP), predisposing patients to paroxysmal tachyarrhythmias and, rarely, sudden cardiac death.¹ Determining AP location from the resting 12-lead electrocardiogram (ECG) is clinically pivotal: it guides catheter-ablation strategy, predicts procedural complexity, and informs counselling about success rates and adverse-event profiles.² The SMART-WPW algorithm, derived and validated in a recent multicentre study, provides an accurate, efficient, and reproducible three-step decision tree for ECG-based accessory-pathway localization, potentially streamlining pre-procedural planning in everyday practice.³

Case Illustration: A 22-year-old man presented to a primary-care clinic with a first-ever episode of left-sided chest discomfort described as “tightness.” He denied syncope, palpitations, or a prior cardiac history. Vital signs were within normal limits. A standard 12-lead ECG revealed sinus rhythm with positive delta waves in the inferior leads, a pseudo-infarct pattern in aVL, and a right bundle branch block-like morphology, suggestive of WPW type A. To pinpoint the accessory pathway, the SMART-WPW algorithm was applied: the positive delta deflection in V1 directed attention to the mitral annulus; the persistence of positive delta waves across all inferior leads meant none were negative; consequently, the pathway was categorised as “L.” Taken together, these findings localised the AP to the lateral segment of the mitral annulus, corresponding to the one-to-three o’clock position on the clock-face model. The patient was subsequently referred to a cardiologist for a comprehensive cardiac evaluation and consideration of definitive electrophysiologic study and ablation.

Conclusion: This initial diagnostic assessment demonstrates that the SMART-WPW algorithm can rapidly and non-invasively identify a lateral mitral annular accessory pathway within a primary-care setting. Integrating this tool into frontline ECG interpretation may enhance timely referral and targeted ablation planning for patients with WPW syndrome.

Keywords: *Wolff-Parkinson-White syndrome, accessory pathway localization, SMART-WPW algorithm, 12-lead electrocardi*

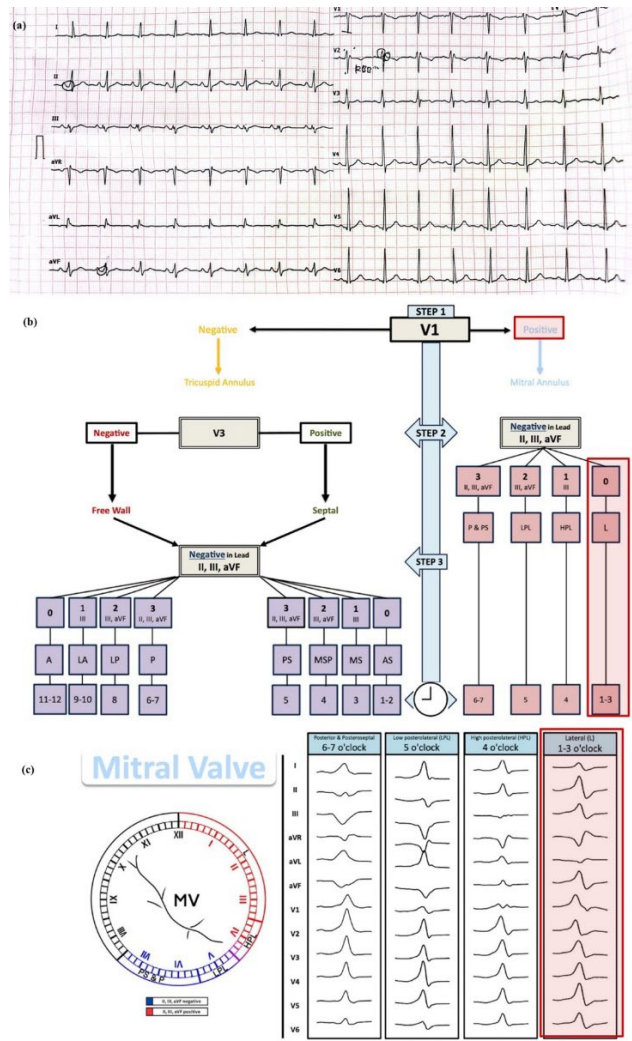


Figure 1. (a) Twelve-lead electrocardiogram recorded at first presentation. Sinus rhythm is accompanied by characteristic of **WPW type A**. (b) Application of the SMART-WPW algorithm pinpoints the accessory pathway to the lateral mitral annulus (clock-face position 1–3 o'clock).³ (c) Clock-face map of the mitral annulus referenced to the index ECG. The patient’s tracing shows a **positive delta wave with a modest r-wave upstroke in V₁–V₂** and upright complexes in II, III, and aVF, fitting the template for a **lateral accessory pathway (1 – 3 o’clock sector, red arc)**. The pattern also reproduces the small q “pseudo-infarct” deflection in aVL typical of left-lateral WPW, corroborating localisation to the lateral mitral annulus.³

[12INAHRS-CR54]

Non-Sustained Ventricular Tachycardia during Fibrinolytic Reperfusion Therapy in a Patient with ST-Elevation Myocardial Infarction: A Diagnostic and Management Challenge in a Rural Area

A. Ramadhanti¹, P. Phalguna², M. G. Kedang¹

¹ General Practitioner, Lewoleba General Hospital, Lembata, Indonesia;

² Internal Medicine Resident, Udayana University, Bali, Indonesia

Background: Myocardial ischemia and infarction can induce life-threatening arrhythmias resulting from severe metabolic and electrophysiological alterations, myocardial scarring, or increased automaticity in the injured myocardium. Arrhythmias may also occur within the first 20 minutes following fibrolytic administration, a phenomenon known as reperfusion arrhythmia. Nevertheless, diagnosis and management remain challenging, particularly in rural areas.

Case Illustration: We reported a 40-year-old man who presented with a sudden onset of retrosternal chest pain for 20 minutes. He also has dyspnea and diaphoresis. His vital signs were stable, with no crackles, murmurs, gallops, or signs of shock. The ECG showed ST-Elevation in anterolateral leads V1-V5, I, aVL, and hyperacute T wave in V4-V6. Ischemic changes were also noted in leads II, III, and aVF. Emergency management focuses on reperfusion per the STEMI algorithm. This strategy included dual antiplatelet therapy (320 mg aspirin and 300 mg clopidogrel), sublingual nitrate, fondaparinux, atorvastatin, and fibrinolytic therapy. The fibrinolytic checklist was implemented, with strict monitoring for signs of bleeding, arrhythmia, shock, and allergic reactions. During the fibrinolytic therapy, the monitor showed frequent PVCs and became non-sustained VT with a duration of less than 30 seconds. ECGs obtained immediately before and six hours after fibrinolytic therapy showed no decrease in ST-elevation exceeding 50%. The chest pain has gone, indicating successful fibrinolytic therapy. However, PVCs still occur frequently after fibrinolytic. The patient was subsequently referred to RSUD Yohannes Kupang for rescue PCI. The angiography showed 99% stenosis of proximal LAD, 40% stenosis of mid RCA, and 20% stenosis of distal RCA. A stent was deployed in the proximal LAD. The patient remained stable and was discharged 3 days post-PCI.

Conclusion: Myocardial infarction can induce PVCs leading to life-threatening ventricular arrhythmia due to automaticity or triggered activity in the region of ischemia or infarction. These arrhythmias may manifest as reperfusion arrhythmias, indicative of infarct vessel reopening through clot dissolution. However, non-sustained VT can cause hemodynamic instability and higher mortality.

Keywords: Fibrinolytic, STEMI, Ventricular Tachycardia

[12INAHRS-CR55]

Decoding the Hidden Threat: Unmasking High-Risk ECG Signs Beyond STEMI Criteria

M. F. Adda'i¹, B. Widyantoro¹

¹National Cardiovascular Center Harapan Kita, Department of Cardiology and Vascular Medicine, Faculty of Medicine, Universitas Indonesia

Background: The classification of ST-segment elevation myocardial infarction (STEMI) and non-STEMI (NSTEMI) has been in use for over 30 years. Despite its high specificity, several reports have demonstrated that STEMI criteria exhibit low sensitivity in detecting complete occlusions. This results in missed diagnoses of occlusive myocardial infarction (OMI) in over one-third of cases, leading to delays in detection and primary percutaneous coronary intervention (PCI), and ultimately worsening patient prognosis. Therefore, there is growing consideration for revising the OMI/NOMI STEMI criteria. Here, we present a case of total coronary occlusion without significant ST-segment elevation on electrocardiography (ECG).

Case Illustration: A 41-year-old male presented to the emergency department with typical angina occurring five hours prior, without nausea or dyspnea. The physical examination was unremarkable, with a history of smoking, pre-diabetes, dyslipidemia, and hypertension. Serial electrocardiograms (ECGs) showed ST depression at V3-V6, without dynamic ST-T changes, and elevated high-sensitivity troponin-T (242 ng/L), leading to an initial diagnosis of NSTEMI and proceeding to an early invasive strategy. Surprisingly, angiography revealed a grade V thrombotic lesion with total occlusion in the proximal LAD and 70% stenosis in the distal RCA. Two drug-eluting stents were successfully deployed under intravascular ultrasound (IVUS) guidance, achieving excellent TIMI III flow. Post-procedure ECGs demonstrated a typical anterior STEMI evolution pattern with a right bundle branch block. Upon reevaluation of the initial ECG, a precordial swirling sign was identified, suggesting a high risk for OMI. This case highlights the limitations of current STEMI ECG criteria in detecting total occlusions. Despite the absence of significant ST elevation, the presence of high-risk ECG patterns may indicate a severe occlusion requiring immediate intervention. Emergency physicians should be trained to recognize these high-risk ECG findings, including the precordial swirling sign, Wellens pattern, hyperacute T waves, de Winter T-wave pattern, Aslanger pattern, South African flag sign, new-onset bifascicular block, posterior OMI, northern OMI, terminal QRS distortion, and modified Sgarbossa criteria.

Conclusion: This case underscores the importance of identifying high-risk ECG patterns beyond traditional STEMI criteria to prevent delays in diagnosing and treating near-complete or complete coronary occlusions. Revising STEMI criteria to incorporate these high-risk ECG features may improve early detection and intervention, ultimately leading to improved patient outcomes.

Keywords: ECG revisited, acute coronary syndrome, early detection, occlusive myocardial infarction

[12INAHRS-CR56]

Management of Supraventricular Tachycardia in a Neonate with Wolff-Parkinson-White Syndrome: A Case Report

K. Adiavira¹, M. Adityansah¹, H. Mutha'alimah¹, A. K. Putri², R. Hendiperdana³

¹General Practitioner, Pandan Arang General Hospital, Boyolali, Indonesia

²Cardiologist, Pandan Arang General Hospital, Boyolali, Indonesia

Background: Supraventricular tachycardia (SVT) is the most prevalent arrhythmia in children. SVT in 15-day-old neonates is rare and constitutes a medical emergency. Without prompt treatment, it can result in heart failure and mortality, highlighting the critical importance of early recognition and appropriate management.

Case Illustration: A 15-day-old male neonate presented with severe respiratory distress and poor feeding, indicative of an early presentation of SVT. Initial evaluation revealed SVT with a heart rate of 299 beats per minute and hypoglycemia (22 mg/dL). Emergency management with diltiazem (0.25 mg/kg) successfully converted the rhythm to sinus rhythm. The post-conversion electrocardiogram demonstrated delta waves, characteristic of WPW syndrome, confirming atrioventricular reentrant tachycardia (AVRT). Echocardiography revealed a normal cardiac structure with good ventricular function. The patient was discharged on oral bisoprolol 0.5 mg daily.

AVRT in WPW syndrome involves an accessory pathway (the bundle of Kent) that creates an abnormal electrical connection between the atria and the ventricles, bypassing the normal AV node. In orthodromic AVRT, electrical impulses travel down through the AV node and return via the accessory pathway, establishing a reentry circuit that sustains tachycardia.

Diltiazem treats AVRT by blocking L-type calcium channels in the AV node, slowing conduction, and increasing the refractory period. This interrupts the reentry circuit by eliminating the antegrade limb, terminating tachycardia. Although adenosine is a first-line treatment, diltiazem offers an alternative when adenosine is unavailable, as observed in Indonesia. Catheter ablation is definitive treatment for WPW syndrome, but is typically postponed until at least 9 years of age due to technical challenges in small cardiac structures. Long-term beta-blocker therapy is generally required until ablation becomes appropriate.

Conclusion: This case report is significant because it demonstrates successful management of a rare, life-threatening condition in a neonate using alternative pharmacological therapy when standard treatment was unavailable.

Keywords: Supraventricular tachycardia, Wolff-Parkinson-White syndrome, diltiazem, atrioventricular reentrant tachycardia, early neonatal presentation

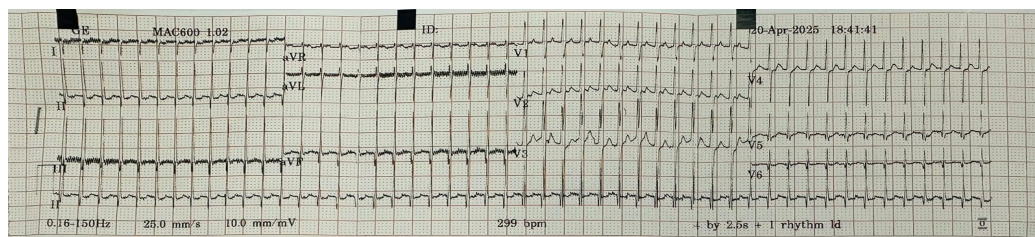


Figure 1. Electrocardiogram on initial presentation, revealing SVT.

[12INAHRS-CR57]

Dynamic QRS Changes During Supraventricular Tachycardia: Recognizing the Peelback Phenomenon

F. Tedjasukmana¹, B. Hartono¹, E.J. Gunawan¹, D.A. Munawar¹, D.L. Munawar¹, M. Munawar^{1,2}

¹*Binawaluya Cardiac Center, Jakarta, Indonesia*

Background: The peelback phenomenon is an electrophysiologic observation during supraventricular tachycardia (SVT), characterized by a transition from wide QRS tachycardia to narrow QRS morphology. This transition results from the resolution of functional bundle branch block, offering insight into the relationship between bundle conduction and the tachycardia circuit. Recognition of this phenomenon can guide diagnosis and ablation strategy.

Case Illustration: A 36-year-old male presented with a one-week history of recurrent palpitations. The longest episode lasted approximately one hour, with a smartwatch documenting a heart rate of 200 bpm. Baseline ECG and transthoracic echocardiography were normal. No SVT was captured prior to the procedure. An electrophysiological study revealed a narrow QRS tachycardia with a cycle length of 300 ms. Atrial activation was eccentric, with the earliest signal at CS 3-4, suggesting an orthodromic AVRT via a left posterolateral accessory pathway. Access to the left atrium was achieved via a patent foramen ovale. With isoproterenol infusion (4 µg/min), the tachycardia reinitiated with a right bundle branch block (RBBB) pattern. Notably, the tachycardia cycle length remained unchanged at 296 ms. His-synchronous pacing resulted in a transition from wide to narrow QRS morphology without any change in the tachycardia cycle length—demonstrating the peelback phenomenon. This electrophysiologic behavior indicated that the change in QRS morphology was due to the resolution of functional bundle branch block, with the tachycardia mechanism and circuit unaffected. Resetting the tachycardia with His-synchronous pacing confirmed pathway participation. Ventricular overdrive pacing showed V-A-V response, PPI-TCL < 115 ms, and VA time 88 ms, consistent with an orthodromic AVRT. Radiofrequency ablation of the left posterolateral accessory pathway terminated the arrhythmia. Post-ablation testing confirmed non-inducibility of SVT.

Conclusion: The peelback phenomenon indicates recovery of conduction within the bundle branches without altering the tachycardia mechanism or cycle length. Recognizing this during an EP study offers valuable insight into the localization and behavior of the tachycardia circuit, thereby facilitating accurate diagnosis and successful ablation.

Keywords: Peel back mechanism, supraventricular tachycardia, electrophysiology study, RFA

[12INAHRS-CR58]

Late Consequences of Atrial Septal Defect: Navigating Atrial Arrhythmias and WPW Syndrome in Adulthood

R. Karimah¹, A. A. R. Sugiarto², A. F. Rachma², R. Julario^{2,3}, B. B. Dharmadjati^{2,3}, R. N. Rosyadi^{2,3}, M. R. Amadis^{2,3}, R. I. Gunadi^{2,3}, M. J. Al-Farabi^{2,3}

¹Faculty of Medicine and Health, Institut Teknologi Sepuluh Nopember, Surabaya, Indonesia

²Faculty of Medicine, Universitas Airlangga, Surabaya, Indonesia

³Department of Cardiology and Vascular Medicine, Dr. Soetomo General Academic Hospital, Surabaya, Indonesia

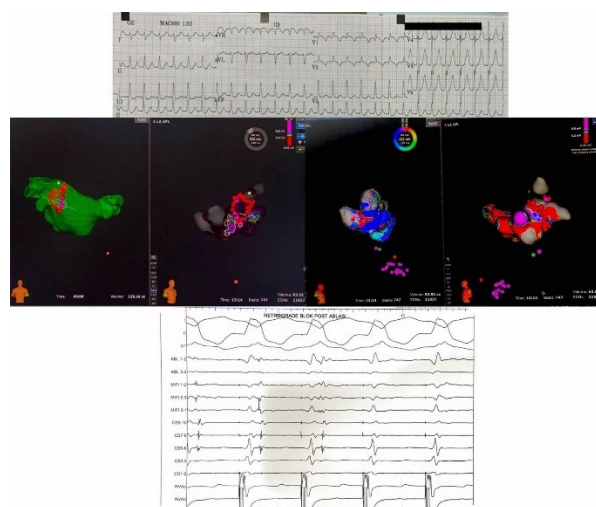
Background: Atrial septal defects (ASD) contribute to atrial arrhythmogenesis via pathophysiological mechanisms, including volume overload and left-to-right shunting, which increase right atrial pressure and stretch the atrial myocardium. These changes prolong the atrial effective refractory period (AERP), delay interatrial conduction, and heighten susceptibility to atrial fibrillation (AF), particularly when triggered by premature stimuli. Wolff-Parkinson-White (WPW) syndrome, involving an accessory pathway that bypasses the normal AV conduction system, adds further arrhythmic risk. In WPW syndrome, AF can rapidly conduct to the ventricles via this accessory pathway, potentially leading to ventricular fibrillation and sudden cardiac death. Consequently, early ASD closure is essential to prevent chronic atrial remodeling and reduce the likelihood of life-threatening arrhythmias.

Case Illustration: A 62-year-old male presented to the emergency department with persistent palpitations and was hemodynamically unstable. An electrocardiogram (ECG) revealed SVT, successfully cardioverted to sinus rhythm with a delta wave, indicative of WPW syndrome. Echocardiography revealed a 2.0 cm ASD, left atrial dilation, and likely pulmonary hypertension.

Electrophysiology study (EPS) procedure revealed Atrial Flutter (AFL) and AF with rapid ventricular response; no form of SVT was induced. Subsequently, EPS with 3D activation mapping was conducted. Pulmonary vein isolation was achieved using multiple radiofrequency ablations (RFA) at 40-50 watts, 45°C, and 250 ohms for 10 seconds. During ablation, spontaneous SVT was induced, with eccentric atrial activation and fusion at CS 5-6, consistent with AVRT. Thus, multiple RFAs were performed on the left posterior accessory pathway area at 30 watts, 50°C, and 250 ohms for 30 seconds. A reverse typical atrial flutter with a 2:1 conduction ratio was also spontaneously induced, followed by multiple RFAs at the cavotricuspid isthmus (CTI) using 30 watts, 50°C, and 250 ohms for 30 seconds. Ablation was deemed successful after 30 minutes of rhythm monitoring. Holter evaluation one month post-procedure revealed first-degree atrioventricular block without other arrhythmias.

Conclusion: Ablation represents the primary treatment option for complex arrhythmias in adults, and early atrial septal defect closure remains crucial for preventing complications.

Keyword: atrial septal defect; atrial fibrillation; atrial flutter; wolff-parkinson-white syndrome



[12INAHRS-CR59]

The Role of Sulfas Atropine in Junctional Bradycardia with Hyperkalemia in a Chronic Kidney Disease Patient Undergoing Regular Hemodialysis

Indah W. Hergaf¹, Yolanda J. Ardi¹, Haryadi²

¹General Practitioner of the Emergency Department Eka Hospital, Pekanbaru, Indonesia

²Department of Cardiology and Vascular Medicine Eka Hospital, Pekanbaru, Indonesia

Background: Hyperkalemia is a potentially life-threatening electrolyte disorder, defined as a serum potassium level of ≥ 5.5 mEq/L. It can precipitate lethal arrhythmias, including ventricular fibrillation and asystole, carrying a mortality risk of up to 30%. Management strategies include myocardial membrane stabilization, potassium shifting into cells, and enhanced elimination. Sulfas atropine acts by inhibiting vagal tone and stimulating the sinoatrial node, making it effective in specific bradyarrhythmias, particularly when the distal conduction system remains functional.

Case-Illustration: A 62-year-old male with end-stage renal disease on biweekly hemodialysis presented with progressive weakness and chest discomfort. He had a past medical history of hypertension, type 2 diabetes mellitus, and coronary artery disease post-PCI in 2019. Upon admission, vital signs were as follows: blood pressure 90/75 mmHg, heart rate 34 bpm, and respiratory rate 20 breaths/min. Electrocardiography showed junctional bradycardia with sinus pause, tall T waves, and prolonged QTc (480 ms). Serum potassium was 8.0 mmol/L. The patient was diagnosed with cardiogenic shock, symptomatic bradycardia, and severe hyperkalemia. Initial treatment in the emergency department consisted of 1 g of intravenous calcium gluconate, a rapid-acting insulin IV bolus of 10 units, and 50 mL of a 40% dextrose solution. A dopamine infusion was initiated at 5 mcg/kg/min, resulting in hemodynamic improvement (blood pressure: 130/70 mmHg, heart rate: 42 bpm, respiratory rate: 20 breaths/min). A repeat serum potassium measurement showed a decrease to 5.1 mmol/L; however, the ECG continued to display a junctional rhythm and tall T waves. Subsequently, a trial dose of 1 mg of intravenous sulfas atropine was administered, after which the ECG converted to sinus rhythm at a rate of 79 bpm.

Conclusion: Hyperkalemia can manifest as junctional bradycardia resulting from conduction disturbances at the sinoatrial and atrioventricular nodes. Even modest elevations in serum potassium can significantly disrupt cardiac conduction. In selected emergency cases, atropine sulfate may be considered to manage bradyarrhythmias associated with hyperkalemia, particularly when ECG abnormalities persist despite initial correction.

Keywords: hyperkalemia, junctional bradycardia, atropine sulfate.

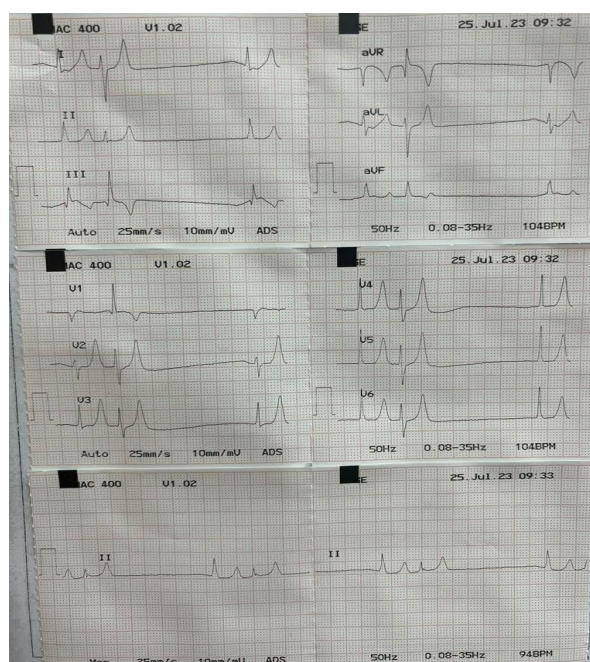


Figure 1. ECG in the emergency department.

[12INAHRS-CR60]
Managing Narrow Complex Tachyarrhythmia: How to Tackle when Resources are Limited

A. Hartono^{1,2}, A. Nandika¹, O. Widyasari²

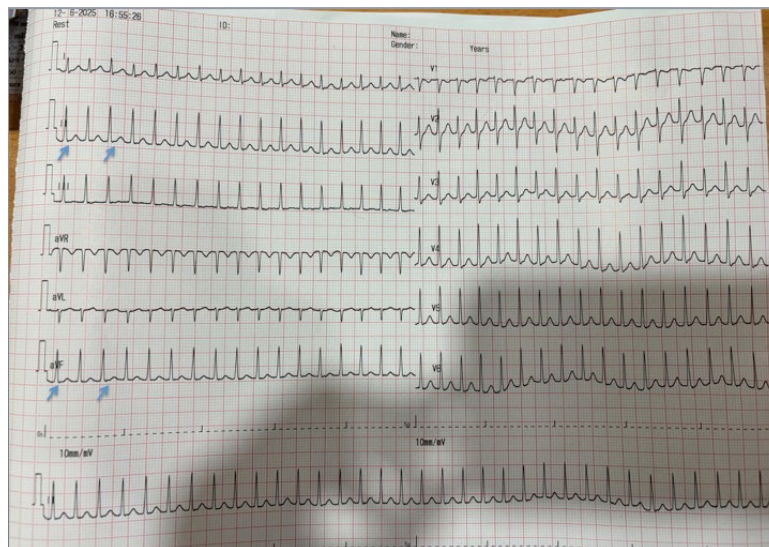
¹Faculty of Medicine, Padjadjaran University, West Java, Indonesia; ²General Practitioner, Kramat 128 Hospital, Jakarta, Indonesia

Background: Atrioventricular nodal reentrant tachycardia (AVNRT) is a frequently encountered narrow-complex tachyarrhythmia. Here, we present a case of AVNRT and its management in resource-limited settings.

Case Illustration: A 21-year-old female presented with a sudden onset of palpitations lasting 2 hours, without associated symptoms such as fever, cough, dyspnea, diarrhea, nausea, or vomiting. Other precipitating factors, such as illicit drug or alcohol use, excessive caffeine intake, lack of sleep, and exercise, were denied by the patient. She also denied a history of similar palpitations. Physical examination revealed tachycardia with a heart rate of 220 beats per minute and a regular rhythm, with no other signs of hemodynamic instability. A 12-lead electrocardiogram (ECG) demonstrated regular, narrow-complex tachycardia (rate: 188 beats/minute) characterized by a retrograde P wave visible as a pseudo-S wave in leads II and aVF, and an RP interval of 40 ms; the working diagnosis was AVNRT. Laboratory findings were unremarkable, revealing no electrolyte abnormalities, and echocardiography did not identify any structural heart abnormalities. A vagal maneuver was unsuccessful in terminating the AVNRT. Due to the absence of intravenous adenosine, beta-blockers, or calcium channel blockers at the hospital, pharmacological cardioversion was attempted with amiodarone (150 mg intravenously over 10 minutes), which was also ineffective. Subsequently, digoxin 0.5 mg was administered intravenously, followed by bisoprolol 2.5 mg orally. A repeat ECG after 10 minutes revealed sinus rhythm (rate: 83 beats/minute, regular), a normal PR interval, and the absence of delta waves.

Conclusion: Managing narrow complex tachycardias presents challenges in resource-limited settings, where several drugs recommended by the Advanced Cardiac Life Support (ACLS) guideline may not be readily available. Alternative antiarrhythmic agents could be administered, provided they lack absolute contraindications.

Keywords: AVNRT, Tachyarrhythmia, RP interval, Cardioversion



[12INAHRS-CR61]

Challenging Pacemaker Implantation in a Patient With Incidental Finding Persistent Left Superior Vena Cava: Is It an Innocent Bystander or Predisposing to Sinus Node Dysfunction?

A. A. R. Sugiarto¹, R. Karimah², A. F. Rachma¹, R. Julario³, B. B. Dharmajati³,
M. J. Al-Farabi³, R. I. Gunadi³.

¹Faculty of Medicine, Airlangga University, Surabaya, Indonesia

²Faculty of Medicine and Health, Institut Teknologi Sepuluh Nopember, Surabaya, Indonesia

³Cardiology and Vascular Medicine Department, Dr. Soetomo Regional General Hospital, Faculty of Medicine, Airlangga University, Surabaya, Indonesia.

Background: While most patients with persistent left superior vena cava (PLSVC) are asymptomatic, it can become clinically significant when central venous access is required. Furthermore, an increased risk of conduction system abnormalities has been observed in PLSVC patients; however, the precise pathogenesis remains unclear.

Case illustration: A 70-year-old female presented with recurrent near-syncope that worsened over the last 2 days. Previously, the patient was scheduled for elective permanent pacemaker (PPM) implantation due to sinus arrest. She reported a history of hypertensive heart disease and diabetes mellitus for the last 2 years. All findings upon the vital signs and physical examinations were normal. Echocardiography showed normal results; no congenital abnormalities were found.

A single-chamber PPM implantation was performed. However, the wire from the left subclavian vein was peculiarly positioned towards the right atrium (RA). Venography confirmed a PLSVC draining into a dilated coronary sinus, alongside a right superior vena cava. Afterwards, an active lead was successfully implanted in the right ventricular outflow tract via the right subclavian vein and is functioning well with VVIR mode. Nevertheless, a week later, the patient presented with dizziness and near-syncope. The ECG demonstrated sinus arrest with a junctional escape rhythm and pacemaker spikes, without capture beats, suspected to be due to lead dislodgement. The patient subsequently underwent a lead repositioning procedure.

Conclusion: Implanting a PPM in patients with PLSVC poses significant technical challenges and appears to carry a higher risk of lead dislodgement. Implantation through the right subclavian vein is expected to augment lead stability. Nevertheless, in the future, implantation of a leadless device would probably be the optimal choice. There are several hypotheses of the possible pathogenetic correlation between PLSVC and the development of SND; thus, PLSVC may not be just an innocent bystander. One hypothesis posits that SND may be linked to embryological abnormalities that contributed to the formation of PLSVC. Moreover, chronic hemosiderin deposition in myocardial tissue, resulting from sustained volume and pressure loads on the coronary sinus, could suppress sinoatrial node automaticity. Nevertheless, further experimental and clinical investigation is required to fully elucidate this relationship.

Keywords: Persistent left superior vena cava, Sinus Node Dysfunction, Pacemaker Implantation

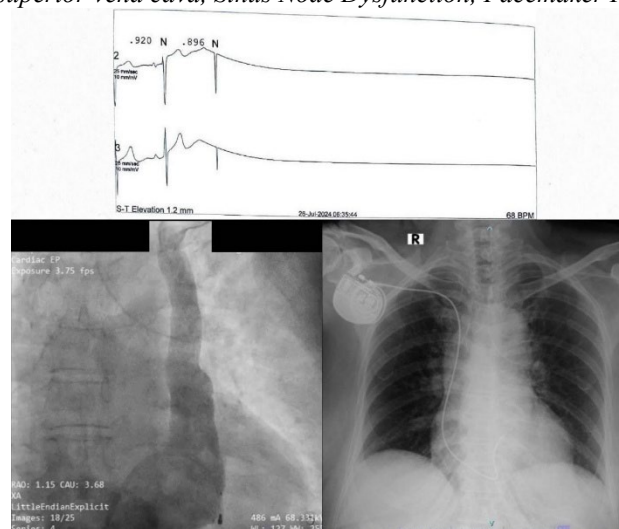


Figure 1. Picture of sinus arrest on Holter monitoring, PLSVC on venography, and implanted PPM.

[12INAHRS-CR62]

Atrial Fibrillation with Wolff-Parkinson-White Syndrome in A Young Patient With a History of Juvenile Dermatomyositis: A Cardio-Oncology Case Report

K. Fahrurozi¹; P. Sekar²; M. Akbar³; D. Luthfiyah⁴; Yulianto⁵; D. P. Andryan³

¹*Emergency Department, Klaten Islamic General Hospital, Klaten, Indonesia*

²*Department of Cardiology and Vascular Medicine, Umar Wirahadikusumah General Hospital, Sumedang, Indonesia*

³*Al Islam General Hospital, Bandung, Indonesia*

⁴*Department of Pediatrics, Dr Moewardi General Hospital, Surakarta, Indonesia*

⁵*Department of Cardiology and Vascular Medicine, Klaten Islamic General Hospital, Klaten, Indonesia*

Background: Juvenile dermatomyositis (JDM) is a rare autoimmune condition characterized by chronic inflammation of the skin and muscles. Its annual incidence in the US is 2.7–3.4 per million children. Although muscle weakness and cutaneous manifestations are prominent clinical features, subclinical cardiac involvement is increasingly recognized as a significant contributor to long-term morbidity.

Case Illustration: A 19-year-old male with a history of JDM and immunosuppression presented to the emergency room with palpitations, dyspnea, and chest pain. He reported experiencing extreme palpitations while working at a restaurant in the morning, continuing until the night before his presentation to the ER. He was hypertensive (172/119 mmHg), and ECG revealed extremely rapid AF with WPW, bizarre QRS complex with LBBB morphology, with a heart rate of up to 300 bpm. This patient was managed using a slow amiodarone drip, then continued using oral bisoprolol. The rate was stabilized within three hours. We suspected that the accessory pathway originated from the anteroseptal region of the tricuspid annulus. Echocardiography revealed mild tricuspid regurgitation and right ventricular dilatation. At a three-month follow-up, the patient was well controlled with bisoprolol, ramipril, furosemide, and warfarin.

Vasculopathy and endothelial dysfunction are hallmarks of JDM, driven by cytokine-mediated damage and microvascular ischemia. Chronic inflammation promotes myocardial remodeling, leading to diastolic dysfunction and conduction system abnormalities. Up to 26% of young and middle-aged adults with inflammatory myositis develop arrhythmias. In JDM, AF may arise from myocardial inflammation, autonomic dysregulation, or fibrotic remodelling. Methotrexate demonstrates significant cardioprotective effects in patients with inflammatory diseases. Meta-analyses show that methotrexate use is associated with a reduction in cardiovascular disease risk in patients with inflammatory conditions. The drug's cardiovascular benefits occur through the reduction of pro-inflammatory cytokines. For patients with Wolff-Parkinson-White syndrome and AF, catheter ablation of the accessory pathway remains the definitive treatment, with success rates exceeding 95%. However, addressing the underlying inflammatory substrate through continued immunosuppressive therapy is equally important for long-term arrhythmia control.

Conclusion: JDM most likely represents the primary etiology for the development of atrial fibrillation with pre-excitation in this clinical scenario. Methotrexate should be continued when indicated, as it provides cardioprotective benefits through its anti-inflammatory effects.

Keywords: Juvenile Dermatomyositis, Atrial Fibrillation, Wolff-Parkinson-White Syndrome, Methotrexate

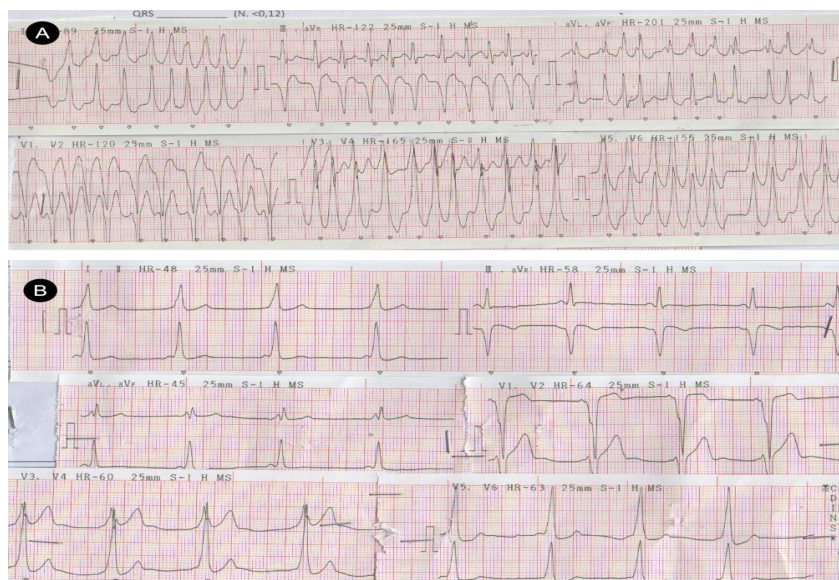


Figure 1. A. ECG at admission showed very rapid AF RVR, delta wave indicating WPW; B. Evaluation ECG showed significant improvement.

[12INAHRS-CR63]

Hidden in Plain Sight : STEMI Equivalent Presentation of Critical LAD Lesion in a Patient with Right Bundle Branch Block

R. A. Nugraha¹, J. Nugraha², S. Widodo³, Suhardi⁴

¹General Practitioner, BSH Hospital, Bogor, Indonesia;

²General Practitioner, PAMA Clinic Site, East Kutai, Indonesia;

³Cardiology Resident, National Cardiovascular Center Harapan Kita, Jakarta, Indonesia

⁴Cardiologist, Taman Husada General Hospital, Bontang, Indonesia

Background: Right Bundle Branch Block (RBBB) is rarely found in patients with myocardial infarction (MI). It occurs in approximately 6% of MI cases. Current guidelines recommend that RBBB with high suspicion for ongoing MI should be assessed as a STEMI equivalent and prompt triage for immediate reperfusion therapy.

Case Illustration: A 50-year-old male mining worker presented to the clinic on site complaining of chest discomfort, palpitations, diaphoresis, nausea, and fatigue. He denied a history of hypertension, diabetes mellitus, or coronary heart disease; however, his blood pressure was 160/90 mmHg, heart rate 72 beats per minute, and respiratory rate, oxygen saturation, and body temperature were within normal limits. The ECG showed a complete RBBB pattern with characteristic duration of QRS ≥ 120 ms, rsR' wave pattern in lead V1 and or V2, S wave $> R$ wave or > 40 ms in lead I and V6. The patient was immediately transferred to the hospital for cardiac catheterization and reperfusion therapy. Coronary angiography revealed an 80% critical stenosis in the left anterior descending (LAD) artery, and primary coronary intervention (PCI) was subsequently performed.

Conclusion: Managing patients presenting with signs and symptoms suggestive of ongoing myocardial ischemia can be challenging; however, the ECG revealed a RBBB (non-ST elevation). The case was managed as a STEMI equivalent and underwent immediate reperfusion therapy, aligning with current guidelines, which may reduce delays in treatment.

Keyword: Right Bundle Branch Block, RBBB, STEMI Equivalent

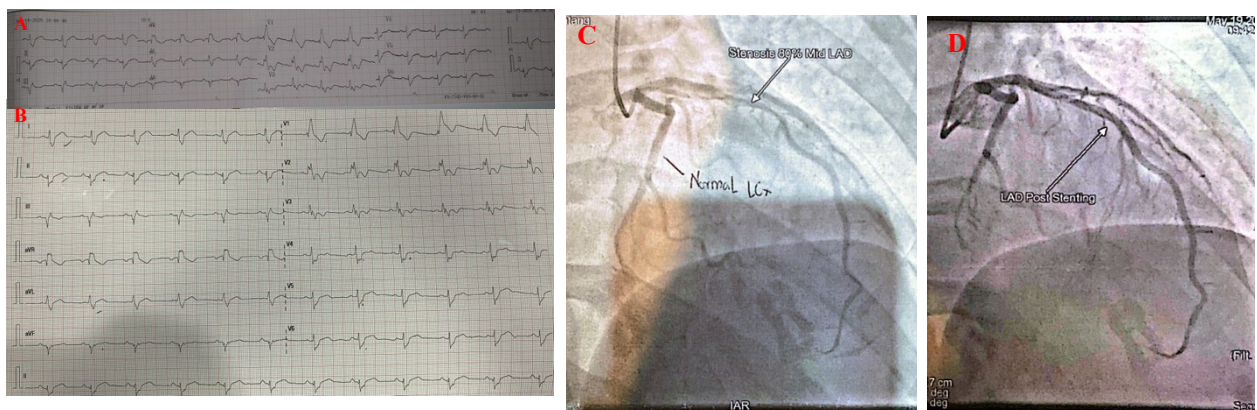


Figure 1. ECG at clinic on site (A); ECG at hospital (B); Angiography showed 80% LAD stenosis (C); After stent placement (D).

[12INAHRS-CR64]

Eight Shocks to Sinus: Surviving Electrical Storm in Inferoposterolateral STEMI

K. M. Pravidani¹, D. Pravian²

¹Budhi Asih General Hospital, East Jakarta, Indonesia

²Department of Cardiology, Budhi Asih General Hospital, East Jakarta, Indonesia

Background: An electrical storm (ES), defined as three or more sustained ventricular arrhythmias occurring within 24 hours, is a critical cardiac emergency. Although typically associated with prior myocardial infarction, heart failure, or electrolyte imbalance, its onset during the acute phase of ST-elevation myocardial infarction (STEMI) is rare. We report a case of ischemia-induced polymorphic ventricular tachycardia (VT) and Torsade de Pointes (TdP) in a previously healthy male, which was resolved with timely percutaneous coronary intervention (PCI).

Case Illustration: A 55-year-old male with a history of heavy smoking and no known comorbidities presented with crushing chest pain for three hours following strenuous weightlifting. ECG showed inferoposterolateral STEMI and borderline prolonged QTc (492 ms). Minutes later, he developed pulseless monomorphic VT that degenerated into Torsade de Pointes (TdP). CPR was initiated with eight consecutive defibrillation shocks over 37 minutes. Intravenous amiodarone, epinephrine, airway management, and sedation were administered. Return of spontaneous circulation (ROSC) was achieved. Laboratory results revealed potassium 3.3 mmol/L, normal magnesium and calcium levels, and hyperglycemia (random blood sugar 456 mg/dL), suggesting an arrhythmia not primarily driven by electrolyte imbalance. The patient underwent emergency PCI, revealing total mid-RCA occlusion; revascularization restored TIMI 3 flow. Echocardiography demonstrated an LVEF of 47%, inferior wall hypokinesia, and right ventricular dysfunction (TAPSE 12 mm). No further arrhythmias occurred post-PCI.

Conclusion: This case illustrates that acute ischemia, particularly in the inferoposterolateral territory supplied by the RCA, can trigger malignant arrhythmias in the absence of significant electrolyte abnormalities. The ischemic insult likely disrupted the Purkinje network and created regional heterogeneity in repolarization, manifesting as TdP. The patient's age and lack of structural heart disease further accentuate the unusual severity of the electrical storm. It challenges the conventional paradigm that TdP is primarily due to congenital or acquired QT prolongation, emphasizing that acute coronary occlusion may act as a sole driver. In this scenario, rapid recognition, prompt defibrillation, and immediate PCI proved lifesaving. Clinicians must remain vigilant for ischemic electrical storms as an early STEMI complication, where swift, targeted intervention can restore rhythm and preserve life, even after extensive electrical instability.

Keywords: Electrical Storm; Torsade de Pointes; STEMI; RCA Occlusion; Ischemia-Induced Arrhythmia; Ventricular Tachycardia

[12INAHRS-CR65]

Ventricular Standstill in Hypertrophic Cardiomyopathy: A Rare but Life-Threatening Complication Requiring Urgent Intervention

S.N. Kadafi¹, M. Fatchi¹, H.A.K.C Prasetyo, P. Ardianto¹

¹Department of Cardiology and Vascular Medicine, Faculty of Medicine, Universitas Diponegoro, Semarang, Indonesia

Background: Ventricular standstill is an uncommon arrhythmia resulting from interrupted ventricular conduction, despite continued sinoatrial node function, and can lead to rapid hemodynamic collapse and sudden cardiac death (SCD). In patients with Hypertrophic Cardiomyopathy (HCM), ventricular standstill can occur, leading to a rapid decline in cardiac output. Stabilization and immediate placement of a temporary pacemaker (TPM) is the primary management approach for ventricular standstill.

Case Illustration: A 40-year-old woman with a history of hypertrophic cardiomyopathy, atrial fibrillation, and a previous episode of unstable ventricular tachycardia requiring cardioversion, presented to the Emergency Department (ED) following a loss of consciousness approximately 20 minutes prior to arrival. The patient had received optimal medical therapy according to established guidelines for 12 months and had experienced four hospital readmissions. Upon assessment in the ED, the patient exhibited no palpable pulse; the monitor displayed ventricular standstill, leading to a diagnosis of pulseless electrical activity. Resuscitation according to ACLS cardiac arrest guidelines was successfully performed. Following return of spontaneous circulation, the ECG rhythm converted to total AV block with a ventricular escape rhythm and a palpable pulse. A bedside temporary pacing (TPM) was immediately inserted under echocardiography guidance. Electrical capture was achieved; however, during stabilization, the patient experienced recurrent episodes of seizures and repeated cardiac arrest. Despite continuous resuscitation efforts for a total duration of three hours, the patient was ultimately pronounced deceased.

Conclusion: In patients with HCM, ventricular standstill carries a high mortality risk. For high-risk patients, implantation of an implantable cardioverter-defibrillator (ICD) is a Class I recommendation to prevent SCD, however, immediate TPM placement in acute cases offers the best option for supporting ventricular contraction and saving the patient.

Keywords: ventricular standstill, hypertrophic cardiomyopathic, temporary pacemaker

[12INAHRS-CR66]

Ivabradine as an Unexpected Treatment Option of Bradycardia

C.J. Hardi¹, I. Posangi², B.M. Setiadi²

¹Manado City General Regional Hospital, Manado, Indonesia; ²Department of Cardiology and Vascular Medicine, Prof. Dr. R. D. Kandou General Hospital, Manado, Indonesia

Background: Ivabradine is a bradycardic agent typically indicated for patients with refractory angina. It acts on I_f (funny channels) within the sinoatrial (SA) node, thereby reducing its firing rate. Unlike other negative chronotropic agents, ivabradine exhibits no negative inotropic effects.

Case Illustration: A 44-year-old male presented to the clinic complaining of sudden palpitations. A resting 12-lead ECG showed sinus rhythm with Mobitz 2 type I atrioventricular (AV) block. Echocardiography demonstrated normal left ventricular function. A 24-hour Holter confirmed intermittent Mobitz type I AV block during palpitations, occurring only at rest, not during sleep or activity. The patient declined an electrophysiologic study. Based on Holter observations, a predominantly parasympathetic tone at rest was suspected. He was initiated on Ivabradine 5 mg twice daily, resulting in symptom resolution. He is currently asymptomatic, and subsequent ECG recordings and exercise treadmill testing confirmed sinus rhythm without AV block.

Currently, no large, controlled human trials have assessed the effects of ivabradine on pathologies associated with AVN or its physiological function. Notably, safety studies and clinical trials have suggested that first- and second-degree AV blocks are adverse effects of ivabradine. It is hypothesized that at lower heart rates, ivabradine affects the SA node during periods of rest by reducing the rate of firing, primarily impacting I_f channels within the SA node more than the AV node. Consequently, the AVN exhibited full conduction of impulses from the atrium to the ventricle because it was below its antegrade Wenckebach period. Despite its dose and use dependency, increased sympathetic tone during exercise or activity may enhance AV conduction, offsetting the effects of ivabradine.

Conclusion: Ivabradine may be considered an alternative agent for patients with AV nodal block due to its decremental properties, which lower baseline heart rate.

Keyword: Ivabradine, Bradycardia, Atrioventricular Block

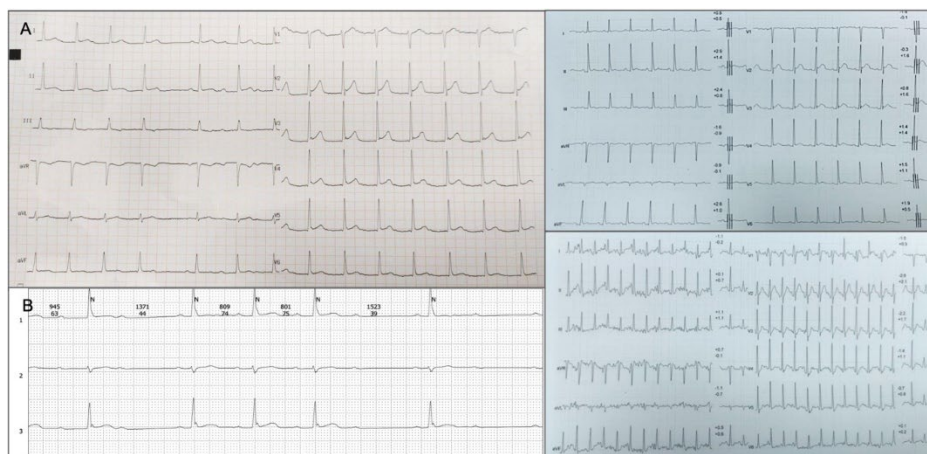


Figure 1. A) Patient's resting ECG showing Mobitz 2 type I AV block; B) Patient's initial Holter strip; C) Patient's follow-up exercise treadmill test showing resolution of AV block.

[12INAHRS-CR67]

Intravascular Ultrasound Guided Percutaneous Coronary Intervention in ST-Segment Elevation Myocardial Infarction Superior to Angiography: An Interesting Case Report

G.F. Nahan¹, I G. A. B. K. Jayantika¹

¹*Department of Cardiology, Bali Mandara Regional General Hospital, Denpasar, Indonesia*

Background: ST-segment elevation myocardial infarction (STEMI) is a critical manifestation of coronary artery disease necessitating urgent revascularization. Although angiography remains the standard imaging modality for percutaneous coronary intervention (PCI), intravascular ultrasound (IVUS) provides detailed insights into plaque morphology, lesion severity, and stent optimization. Emerging evidence suggests that IVUS-guided PCI may improve procedural outcomes and long-term prognosis in STEMI patients compared to angiography-guided interventions.

Case Illustration: A 46-year-old male with chronic kidney disease presented with an ST-segment elevation myocardial infarction (STEMI). Fibrinolytic was successfully given. Fibrinolytic therapy was successfully administered, effectively dissolving blood clots and restoring blood flow to affected areas. It's crucial for treating conditions like STEMI, where prompt action can significantly improve outcomes. Routine early angiography showed diffuse stenosis of 70-90% at the mid to proximal left anterior descending artery (LAD), which is the culprit lesion. PCI was postponed, and the patient was scheduled for elective PCI with IVUS. IVUS imaging demonstrated a fibrous lesion morphology with calcification of 90–180 degrees, a lesion length of 28 mm, and a distal reference diameter of 3.5 mm. A drug-eluting stent (DES) Promus, 3.0 mm × 32 mm, was deployed at the mid to proximal LAD at 12 atm/11 inches. Post-dilatation using NC Emerge 3.5 x 15 mm, inflated three times at 12-20 atm/8-10". Following stent placement, IVUS was repeated, revealing no medial dissection, a well-apposed stent, and no malposition. Angiography demonstrated TIMI 3 flow in the LAD.

Conclusion: This study presents a case for IVUS-guided PCI in a STEMI patient. IVUS data enabled a detailed assessment of plaque geometry, morphology, vessel sizing, and guidewire orientation. The characteristics of this lesion, including fibrous calcification, were demonstrated via IVUS. Although IVUS for STEMI interventions is not yet universally implemented due to logistical and cost-related factors, the growing body of evidence supports broader adoption of IVUS in contemporary interventional cardiology practice.

Keywords: IVUS, PCI, stent optimization, STEMI, angiography

[12INAHRS-CR68]

Approach to Atrial Fibrillation with Rapid Ventricular Response and Its Consequent Stroke in A Limited-Resource Setting

A.H. Laila¹

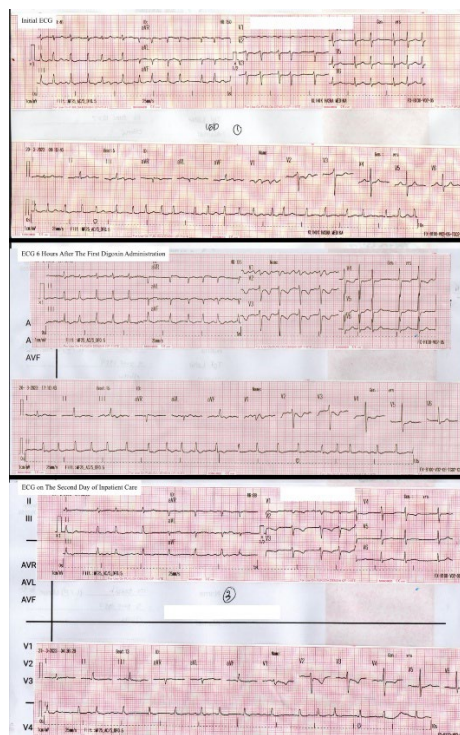
National Heart and Lung Institute, Imperial College London, London, United Kingdom

Background: Atrial fibrillation with rapid ventricular response (AFRVR) is a supraventricular arrhythmia characterized by uncoordinated atrial activation and a ventricular rate greater than 100 bpm. Management strategies include minimizing the risk of stroke and thromboembolism, alleviating symptoms through rate and rhythm control, and ongoing evaluation and reassessment.

Case Illustration: A 63-year-old female presented to the emergency room with palpitations and shortness of breath (SoB) for 2 days, with a history of AF and rheumatic heart disease (RHD). Her regular medications included erythromycin, spironolactone, furosemide, bisoprolol, and warfarin. She was alert, with an irregular heart rate of 140–150bpm, a grade III/IV mitral diastolic murmur, gallop heart sounds, and crackles in two-thirds of her lungs. Her electrocardiography showed AFRVR. Echocardiography revealed severe mitral stenosis (mitral valve area 0.81 cm²) and moderate mitral regurgitation, with an ejection fraction of 55.66%. Her INR was 1.08. Chest X-ray and NT-proBNP were not done due to cost. She was diagnosed with AFRVR, acute decompensated heart failure, and RHD. The treatment plans included IV digoxin 0.25 mg bolus every 6 hours if the HR exceeded 120 bpm, IV furosemide 40 mg b.i.d., spironolactone 25 mg q.d., bisoprolol 5 mg q.d., and warfarin 2 mg q.d. Six hours after digoxin administration, her HR decreased to 115–120 bpm. The next day, the palpitations and SoB had significantly subsided, with HR of 90–100bpm. Given the absence of a CT scan at our institution, she was referred for a stroke work-up. Since there was no CT scan at our institution, she was referred for a stroke work-up.

Conclusions: Despite a limited diagnostic work-up, the acute presentation was promptly stabilized. Initial treatment with digoxin, a first-line rate-control therapy for AF with EF >40%, successfully reduced HR and symptoms. Furosemide, spironolactone, and a beta-blocker alleviated heart failure (HF) symptoms. To prevent ischaemic stroke, warfarin was chosen as oral anticoagulation with an INR target of 2.0–3.0. However, the INR did not reach the target level. Consequently, poor anticoagulation control resulted in an ischemic stroke. Prompt neurological management was required, and the patient was referred for a comprehensive stroke work-up.

Keywords: Atrial fibrillation, ischaemic stroke, management



[12INAHRS-CR69]

Decoding the ECG: Ebstein Anomaly with Accessory Pathway in an Adult Male

M Kannan¹, P Balachanran¹,

¹Department of Internal Medicine, Hospital Kemaman, Malaysia

Background: Ebstein's anomaly is a rare congenital heart defect, accounting for approximately 1% of all congenital heart diseases. It is characterized by apical displacement of the septal tricuspid valve leaflet, tricuspid regurgitation, and right ventricular myopathy. Clinical presentations vary widely; however, adults frequently present with arrhythmias. Accessory conduction pathways are found in 10–30% of patients, typically right-sided and located near the deformed tricuspid annulus.

Case illustration: We report a case of a 50-year-old man with no prior medical or cardiac history who presented with a three-day history of palpitations and sweating. He had experienced intermittent palpitations over the past year but denied syncope, dyspnea, or a family history of cardiac disease. Physical examination revealed hemodynamic stability, characterized by a pansystolic murmur at the left lower sternal edge without radiation. Laboratory results were unremarkable, and a chest X-ray demonstrated cardiomegaly.

The ECG demonstrates sinus rhythm at 62 bpm, right atrial enlargement, PR interval of 200ms, and QRS duration of 120ms. The QRS morphology is notable for the absence of a typical RBBB expected in Ebstein's anomaly, which suggests ventricular pre-excitation via an accessory pathway. Delta waves, positive in leads I, aVL, and V4, are indicative of pre-excitation across a posterior septal accessory pathway. A qR pattern was observed in lead V1, accompanied by fragmented QRS complexes in the precordial leads. QRS morphologies were similar in leads V1 and aVR.

Echocardiography revealed right atrial enlargement and an apical displacement of the septal leaflet of the tricuspid valve, measuring 24 mm from the anterior mitral leaflet insertion. The displacement index (DI) was 15 mm/m². The anterior leaflet of the tricuspid valve is elongated to give a characteristic "sail-like" appearance. Moderate tricuspid regurgitation was observed. The functional right ventricle was small. The LVEF was preserved. Both the interatrial and interventricular septa were intact.

Conclusion: This case underscores the diagnostic utility of ECG in Ebstein's anomaly. The absence of RBBB on baseline ECG should prompt a search for a right-sided accessory pathway. A normal PR interval can occur with pre-excitation due to intratrial conduction delay. Abnormal conduction through the atrialized right ventricle leads to QRS fragmentation and its presence suggests a more severe abnormality and an increased risk of arrhythmia.

Keywords: Arrhythmia, Ebstein's anomaly

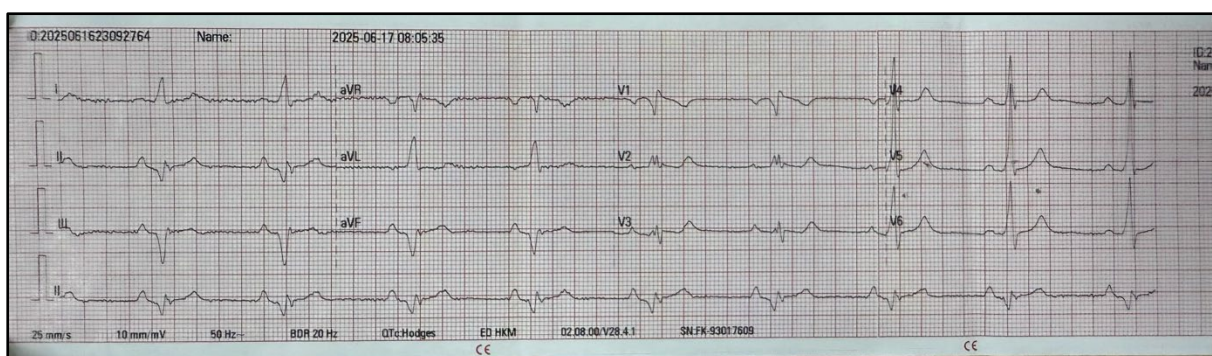


Figure 1. ECG 1.

[12INAHRS-CR70]

Stepwise Ablation of Left Parahisian Premature Ventricular Contractions: Enhancing Safety and Efficacy while Reducing Procedure Time

A. Handayani¹, A. C. Lubis², M. P. Hutasuhut², M. C. Hutapea²

¹Universitas Muhammadiyah Sumatera Utara

²Universitas Sumatera Utara

Background: Para-Hisian ventricular arrhythmias (VAs) account for approximately 3.2% of idiopathic VAs, with left para-Hisian VAs representing only 0.8%. Ablation in this region is challenging due to its proximity to the His bundle. We report a case utilizing a stepwise ablation strategy for left para-Hisian premature ventricular contractions (PVCs), with the goal of enhancing safety and efficacy while minimizing procedure time.

Case Illustration: A 54-year-old male presented with a 6% PVC burden on Holter monitoring and persistent palpitations despite combination antiarrhythmic therapy. ECG revealed PVCs with a moderate inferior axis, an R wave in lead I, an r wave in aVL, and early precordial transition (V1–V2), suggestive of a left outflow tract or para-Hisian origin.

We employed a five-step strategy: (1) precise mapping to identify the earliest activation site (pre-QRS >30 ms and/or high-density map $\geq 95\%$), (2) maintaining a minimum 3.5 mm distance from the His bundle, (3) utilizing a retrograde C-curve single-catheter technique to ensure optimal stability, (4) continuous atrial signal monitoring to detect junctional rhythms, and (5) gradual power titration to minimize complications.

The procedure combined activation and pace mapping, utilizing an ablation catheter. Ablation was directed at the earliest activation site (-58 ms) in the left para-Hisian region, accessed via a retrograde C-curve approach. The distance between this site and the largest His potential was 6 mm. Atrial signals were continuously monitored, and ablation power was titrated from 25 Watts. PVCs were eliminated after five ablation attempts. The total procedure time, from mapping to final ablation, was 26 minutes. No PVC recurrence was observed during a 15-minute post-ablation period, and subsequent Holter monitoring revealed no abnormalities.

Conclusion: This five-step strategy offers a safe, effective, and time-efficient approach for managing left para-Hisian PVCs, demonstrating that procedural speed can be achieved without compromising safety.

Keywords: Para-Hisian premature ventricular contractions, ablation, AV nodal safety

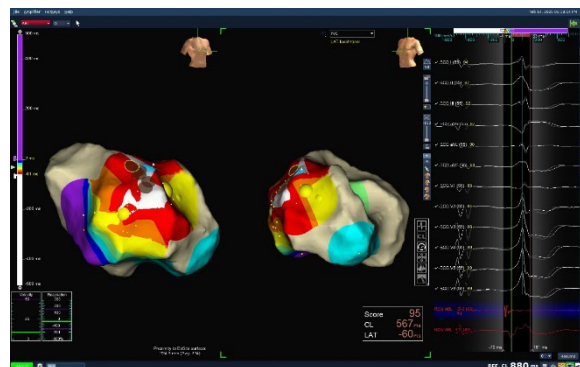


Figure 1. *Left panel:* Three-dimensional activation maps in RAO and LAO projections demonstrate the earliest activation site (white area), occurring more than 50 ms before QRS onset. His bundle recordings are indicated by yellow dots, and ablation lesions are shown by brown tags. *Right panel:* Surface ECG showing the morphology of the PVCs, characterized by a moderate inferior axis, an R wave in lead I, a small R wave in aVL, and early precordial transition between V1 and V2.

[12INAHRS-CR71]
Reinstating the Potential Role of Non-invasive Testing to Unveil Concealed Accessory Pathway

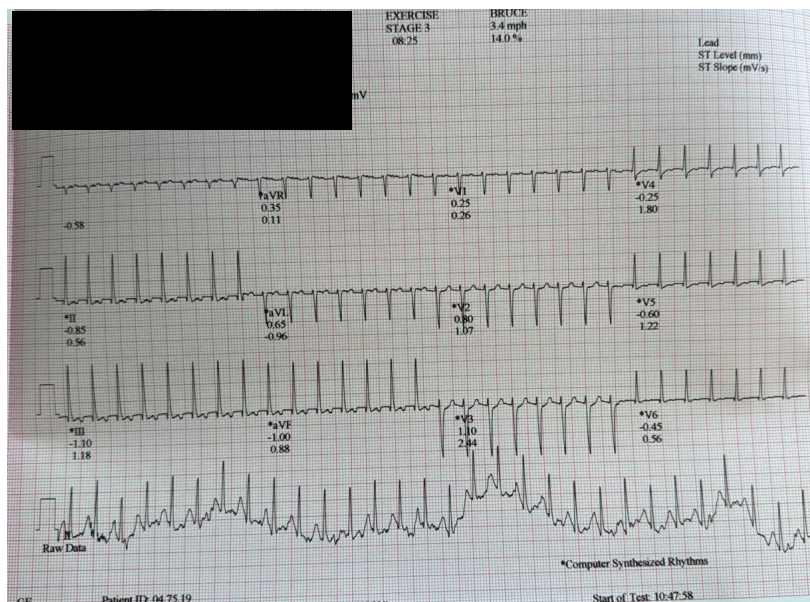
T. S. R. Sembiring¹
¹RSUD Komodo Labuan Bajo

Background: Accessory pathway (AP), in addition to atrium, atrioventricular node, His-Purkinje system, and ventricle, is a part of the orthodromic atrioventricular re-entrant tachycardia (AVRT) circuit. APs may be detected from surface electrocardiography by the presence of a delta wave, indicative of pre-excitation or Wolff-Parkinson-White syndrome; however, this is not always the case with concealed APs. Concealed APs conduct retrogradely and are, therefore, more challenging to confirm than pre-excitation syndrome, typically requiring invasive electrophysiology testing. This case investigates the potential role of exercise stress testing, particularly in AP cases where invasive testing may not be readily available.

Case Illustration: A 27-year-old female presented with a history of recurrent palpitations. She reported no prior syncope or dizziness. Physical examination revealed normal findings. Electrocardiography showed a sinus rhythm, a short PR interval, and no signs of a delta wave. Echocardiography indicated a normal heart structure. A treadmill test, employing the Bruce protocol, was performed to elicit possible episodes of tachyarrhythmia. The test was terminated after 8 minutes due to fatigue, achieving a maximum heart rate of 92%. At peak exercise, a sudden onset of narrow-complex tachycardia with a short RP interval of 120 ms was observed, representing less than half of the RR interval. An orthodromic AVRT diagnosis was established. Subsequently, the ECG returned to sinus rhythm during the recovery period.

Conclusion: In specific cases of atrial fibrillation (AP) where invasive testing is unavailable, non-invasive testing can be utilized. Performing an exercise stress test to the point of fatigue may provoke an orthodromic AVRT episode and serve as a guide for further management of concealed AP.

Keyword: *concealed accessory pathway, non-invasive testing, orthodromic atrioventricular re-entrant tachycardia*



[12INAHRS-CR72]

Radiation-Free Catheter Ablation for Frequent PVCs During Third Trimester Pregnancy: A Case Report

R. R. Dewi^{1,3}, C. Milla², R. R. Muhammad^{1,3}, R. Julario^{1,2,3}, M. J. Al-Farabi^{2,3}, M. R. Amadis^{2,3}

¹*Department of Cardiology and Vascular Medicine, RSUD Dr. Soetomo, Surabaya, Indonesia;*

²*Heart Rhythm Unit, RSUD Dr. Soetomo, Surabaya, Indonesia;*

³*Faculty of Medicine, Universitas Airlangga, Surabaya, Indonesia*

Background: Premature ventricular contractions (PVCs) are common arrhythmias that can become symptomatic or lead to PVC-induced cardiomyopathy with a high burden. Managing ventricular arrhythmias during pregnancy presents particular challenges, primarily due to concerns regarding fetal safety, especially when fluoroscopic imaging is utilized. Although catheter ablation is effective, it frequently involves radiation exposure, which carries potential teratogenic risks, particularly during the third trimester.

Case illustration: A 30-year-old woman (G4P3A2) at 33–34 weeks of gestation presented with frequent PVCs (13% burden) and a history of unexplained loss of consciousness. Electrocardiography and Holter monitoring revealed bigeminy PVCs originating from the right ventricular outflow tract (RVOT). Transthoracic echocardiography showed preserved left and right ventricular function with no structural abnormalities. Electrophysiological study and 3D mapping-guided catheter ablation were performed using a zero-fluoroscopy approach. The PVC focus was localized to the anteroseptal RVOT with the earliest activation at 16 ms and a 97% pace map match. Radiofrequency ablation was performed at this site, resulting in the successful elimination of the PVCs. The procedure was completed without complications, and both maternal and fetal conditions remained stable.

Conclusion: Radiation-free catheter ablation using 3D mapping is a safe and effective alternative for managing symptomatic PVCs during late pregnancy. This approach can be considered in selected cases where medical therapy is limited and the arrhythmia burden is significant.

Keywords: PVC, catheter ablation, pregnancy, zero-fluoroscopy, 3D mapping

[12INAHRS-CR73]

Reverse Remodeling Following Cardiac Resynchronization Therapy With Pacing in Hypertrophic Cardiomyopathy With Diffuse Conduction Abnormality: A Rare Electrophysiologic Phenotype

G.N. Prana Jagannatha¹, I.M. Putra Swi Antara¹

¹Department of Cardiology and Vascular Medicine, Udayana University/ Prof. dr. I.G.N.G Ngoerah General Hospital, Denpasar, Bali, Indonesia

Background: Hypertrophic cardiomyopathy (HCM) is classically associated with preserved systolic function and sudden cardiac death risk, with implantable cardioverter-defibrillators (ICD) often prioritized for risk mitigation. In contrast, cardiac resynchronization therapy with pacing (CRT-P) is rarely indicated unless marked conduction disease or systolic dysfunction is present. We present an unusual case of HCM with diffuse conduction system disease, symptomatic bradycardia, and dyssynchrony, ultimately benefiting from CRT-P

Case Illustration: A 24-year-old man with asymmetric non-obstructive HCM and a history of unstable ventricular tachycardia (VT) presented with fatigue, exertional intolerance, and recurrent seizure-like episodes. ECG revealed complete left bundle branch block (CLBBB) with sinus bradycardia (43–60 bpm). Echocardiography showed asymmetric LV hypertrophy, LA dilatation, and borderline reduced LVEF (biplane 47.5%), whereas cardiac MRI revealed diffuse fibrosis and global hypokinesis. An electrophysiological study demonstrated diffuse conduction system disease without inducible arrhythmias. Despite optimal medical therapy, the patient remained symptomatic with a low cardiac index (1.69) and persistent electrical dyssynchrony. Given the unusual combination of conduction system degeneration, CLBBB, and a low-output state, a CRT-P was implanted. Follow-up imaging showed EF improvement to 58%, indicating reverse remodeling. Clinically, the patient experienced significant functional improvement and an arrhythmia-free follow-up. This case illustrates a non-traditional yet physiologically sound use of CRT-P in HCM, driven by conduction system failure rather than LVOT obstruction or EF-based criteria. Comprehensive EP assessment and multimodal imaging enabled personalized pacing decisions.

Conclusion: CRT may offer significant benefits in select patients with HCM. This case highlights the value of early electrophysiological phenotyping in guiding advanced pacing strategies beyond the traditional guidelines.

Keywords: Hypertrophic cardiomyopathy, Cardiac Resynchronization Therapy, Conduction system disease, Brady arrhythmia, Ejection fraction,

[12INAHRS-CR74]
Blocking and Unblocking, Behaviors of a Man's Broken Heart

A. Rohman¹

Oen Solo Baru General Hospital, Sukoharjo, Indonesia

Background: Ischemic heart disease (IHD) is a major global health problem and a leading cause of death. High-grade atrioventricular block (HAVB) is a known but uncommon complication of acute coronary syndrome (ACS), with an incidence of 3–14% and higher in-hospital mortality. It is more often seen in inferior STEMI, typically due to AV nodal ischemia from right coronary artery involvement. In rare cases, HAVB may be transient, with spontaneous resolution and recurrence, which presents diagnostic and therapeutic challenges.

Case Illustration: A 46-year-old male was brought to the emergency department with left-sided chest pain that began 3 hours prior to admission while he was working as a stonemason. The pain radiated to the epigastric region and the left side of the neck and did not subside with rest. The patient also reported a sensation of impending loss of consciousness during the episode. Further history revealed a history of heavy smoking with no known hypertension or diabetes mellitus.

Vital signs on admission revealed hypotension (67/54 mmHg) and bradycardia (46 beats/min). On physical examination, the patient was diaphoretic with a slow, regular heart rate and weak radial pulse. Electrocardiography (ECG) demonstrated an infero-posterior ST-elevation myocardial infarction (STEMI) with total (third-degree) atrioventricular block (TAVB). The patient was connected to a bedside monitor, which showed a heart rate of 80 beats/min with improvement in his vital signs. Follow-up ECG revealed a first-degree atrioventricular block, but the patient subsequently developed TAVB again. Laboratory examination revealed elevated high-sensitivity troponin I levels and hypokalemia. Hemodynamic stabilization was achieved using intravenous atropine sulfate and a dopamine pump. The patient was subsequently referred to a type A hospital for further treatment.

Conclusion: This case highlights the dynamic course of AV conduction disturbances in inferior STEMI patients. Early recognition, continuous monitoring, and pharmacological support are essential. In hemodynamically unstable cases, the use of a temporary pacemaker is crucial as a bridge to revascularization or permanent pacemaker implantation.

Keywords: Inferior STEMI, Atrioventricular Block, Cardiogenic Shock

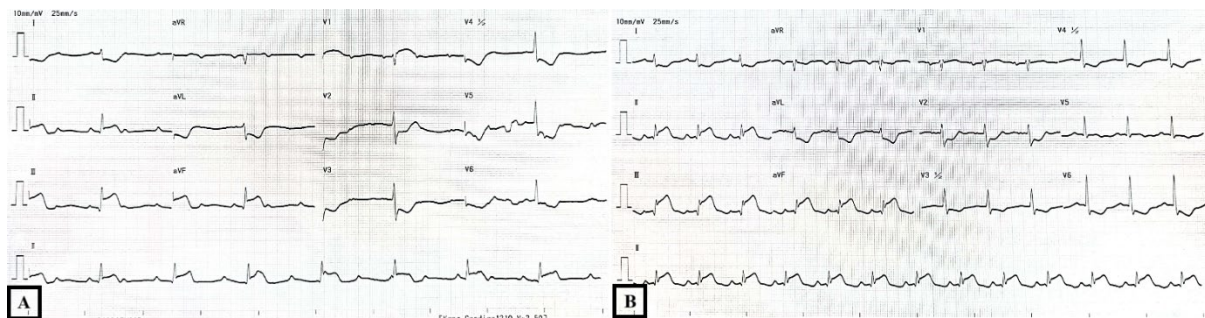


Figure 1. AV-Blocking and Unblocking A. First ECG shows STEMI with total AV-Block B. Follow-up ECG shows 1st degree AV-Block

[12INAHRS-CR75]

Ablation of Persistent Atrial Fibrillation and Scar-Related Ventricular Tachycardia in a Single Procedure: The Role of Pulse Field Ablation

M.C. Hutapea¹, A. Handayani¹, M. P. Hutasuhut^{1,2}, D.A. Munawar³, T.W. Ardini^{1,2}, A.C. Lubis^{1,2}

¹ Faculty of Medicine, Universitas Sumatera Utara, Medan, Indonesia

² Adam Malik Hospital, Medan, Indonesia

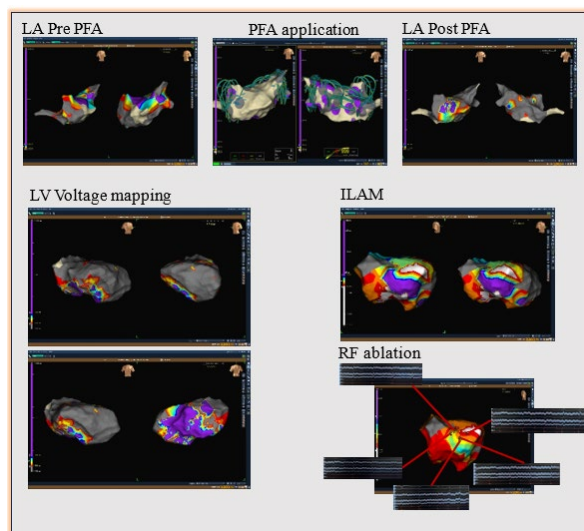
³ Lyell McEwin Hospital, Adelaide, Australia

Background: Pulsed-field ablation (PFA) is a novel ablation technique that delivers energy within milliseconds, substantially improving procedural efficacy and safety and shortening procedure duration. The longer procedural time was a major problem for the conventional RF technique, whereas PFA might enhance several aspects of complex cases in a concomitant procedure.

Case Illustration: A 67-year-old male with a history of CABG in 2007, EVAR in 2017, Heart Failure with reduced EF, long-standing persistent AF, history of LAA and LV thrombus, and an ICD was implanted in 2023 for secondary prevention of VT. His VT was controlled after GDMT optimization; however, 2 years after ICD implantation, he presented with recurrent VT. VT ablation was performed at another overseas center; however, VT recurred with episodes of VT storm. Considering the advanced stage of his disease, we decided to ablate his AF and VT to improve his short- and long-term outcomes. The ECG performed at our center showed VT, which was terminated with ICD therapy or electrical cardioversion. The procedure was performed under general anesthesia and TOE guidance. The geometry and 3D map were created using a high-density catheter HD grid, and a large scar zone was observed in the LA posterior wall. Pulsed-field ablation (PFA) was used to isolate the PVs and LA posterior wall with 74 PFA applications. The procedure was followed by 3D voltage/scar mapping of the left ventricle. VT was easily induced with pacing or catheter maneuvers at baseline. RF ablation was used to homogenize the scar in the area of interest, and after the procedure, VT was no longer inducible, even with aggressive maneuvers. The total procedural time was less than 5 hours. The patient was in stable condition during follow-up, maintaining sinus rhythm and having one VT episode over 3 months of follow-up.

Conclusion: PFA reduces the procedure time for AF ablation, enabling the simultaneous treatment of two malignant arrhythmias.

Keyword: PFA, simultaneous atrial and ventricular ablation



[12INAHRS-CR76]

Successful Ablation of Bidirectional Accessory Pathway Atrioventricular Re-entrant Tachycardia Patient

S.N. Kadafi¹, M. Fatchi¹, P. Ardianto¹

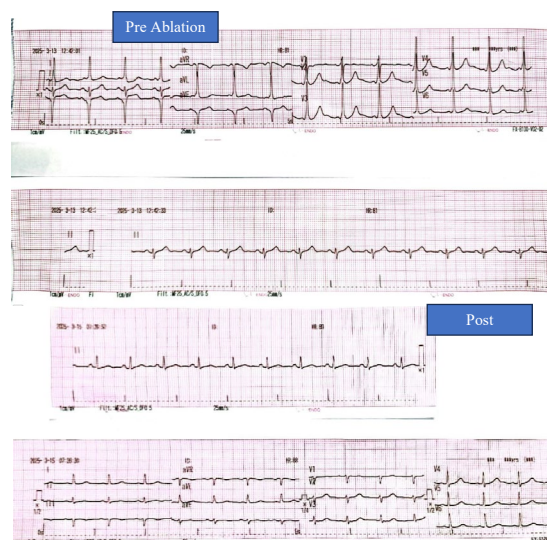
¹Department of Cardiology and Vascular Medicine, Faculty of Medicine, Universitas Diponegoro, Semarang, Indonesia

Background: In patients with Atrioventricular Re-entrant Tachycardia (AVRT), the presence of a bidirectional accessory pathway (AP) can conduct impulses in both anterograde and retrograde directions, representing a rare but clinically significant electrophysiological substrate. Such pathways often demonstrate enhanced conduction properties or abbreviated refractory periods, predisposing patients to pre-excited atrial fibrillation and rapid ventricular response, which may deteriorate into a ventricular fibrillation. Additionally, the possibility of multiple AP or atypical insertion sites increases the complexity of electrophysiological mapping and catheter ablation and is associated with an elevated risk of sudden cardiac death.

Case Illustration: A 51-year-old man presented with intermittent palpitations since the age of 20 years. Five months prior to hospital admission, the palpitations recurred and were accompanied by shortness of breath, chest pain, and cold sweats. The patient sought treatment at a peripheral hospital and was diagnosed with ventricular tachycardia and Wolff-Parkinson-White syndrome. The patient was then referred for an ablation procedure. Surface ECG showed sinus rhythm with delta waves, suggestive of an AP originating from the left posterolateral pathway. During the electrophysiological study, supraventricular tachycardia was easily induced by catheter manipulation. Coronary sinus activation mapping showed eccentric atrial activation, with the earliest ventriculoatrial (VA) fusion at CS 7-8, indicating orthodromic AVRT utilizing a left posteroseptal (LPS) AP for retrograde conduction. Right ventricular (RV) pacing maneuvers demonstrated a VAV response, a post-pacing interval minus tachycardia cycle length (PPI-TCL) < 115 ms, a VA interval of 72 ms, an SA-VA interval > 85 ms, and WP retrograde showing no decremental properties, indicating antidromic AVRT. Multiple ablations were performed at the LPS AP, and the delta wave disappeared within the first five beats during ablation. After a 20-minute observation period, RV apical pacing demonstrated a persistent retrograde block. The procedure was successfully completed without complications.

Conclusion: A patient exhibiting both orthodromic and antidromic AVRT represents an uncommon and complex electrophysiological phenomenon. This presentation is clinically significant due to its diagnostic and therapeutic challenges, and it carries important implications for risk stratification and the prevention of malignant arrhythmias, including sudden cardiac death.

Keywords: Bidirectional Accessory Pathway, Atrioventricular Re-entrant Tachycardia, Electrophysiological Study, and Ablation



[12INAHRS-CR77]

**Smoke and Mirrors by Additional Players:
Rhythm Riddle, Decoding the AVNRT and Accessory Pathway Coexistence**

Rohmatussadeli¹, D. Yoga¹, H. Hutabarat¹, A.Y.B. Mochtar¹, P. Ardianto¹

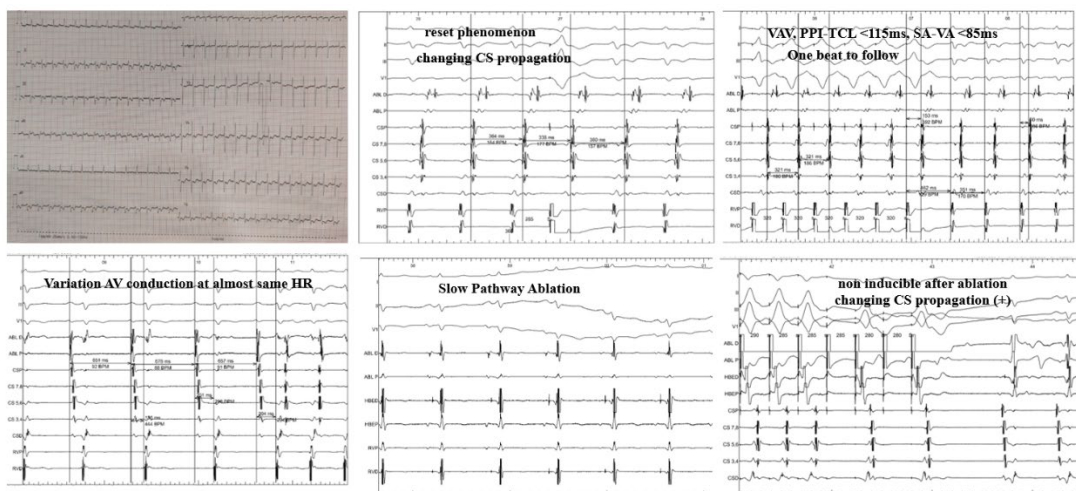
¹Departement of Cardiology and Vascular Medicine, Diponegoro University, Semarang, Indonesia

Background: AVNRT is the most common form of PSVT. AVNRT can present in several forms that can be distinguished on ECG and EPS. However, the diagnosis becomes more challenging when AP is involved in the tachycardia event, given the similar findings with AVRT during the EPS maneuver. This case explores the intricacies of AVNRT with the coexistence of bystander AP.

Case Illustration: A 49-year-old woman presented with palpitations and a history of failed ablation for SVT. Her documented ECG showed narrow-complex tachycardia with a slightly prolonged R-P interval and inverted P waves in the inferior leads. This initial finding suggested AVRT as a diagnosis with a differential diagnosis of AVNRT and AT. The EPS revealed normal basic intervals. Atrial extra stimulation successfully induced tachycardia. The AH interval was shorter than the HA interval. RV pacing maneuver was performed, HRVBP showed reset, and RV apical pacing showed SVT entrainment with VAV response, PPI-TCL <115ms, one beat to follow, then SA-VA < 85ms. Based on several EPS maneuvers, we concluded that the tachycardia was more likely to be AVRT rather than AVNRT. Mapping using an ablation catheter revealed that most VA fusions occurred at the tricuspid annulus near the os of the CS. Multiple RFAs did not produce a retrograde block. We found different VA fusion at CS 1-2 during RV apical pacing and CS 5-6 during the HRVBP maneuver. We performed linear ablation of the left posterior wall. Once again, a retrograde block could not be achieved in the patient. Upon detailed evaluation, there was a variation in AV conduction before the spontaneous tachycardia. Ablation of the slow pathway was performed, rendering tachycardia non-inducible by programmed and burst atrial pacing. These findings favor AVNRT with a bystander retrograde AP.

Conclusion: Distinguishing between AVNRT and AVRT can be challenging when bystander AP coexists with AVRT. The meticulous application of the EPS maneuver has been proven to accurately delineate the true arrhythmic substrate, enabling the correct identification and diagnosis of PSVT.

Keyword: AVNRT, AVRT, PSVT, Bystander AP



[12INAHRS-CR78]

Premature Ventricular Complexes in a Patient with Hyperthyroidism: A Case Report

N.A. Putri¹, P.R.K. Karmanita¹, S. G. A. Grice¹, N.K. Rahmadanty¹,
A. M. Sarayar^{1,2}, V. Bandana^{1,2}

¹*School of Medicine and Health Sciences, Atma Jaya Catholic University of Indonesia, Jakarta 14440, Indonesia*

²*Department of Cardiology and Vascular Medicine, Faculty of Medicine, Atma Jaya Catholic University of Indonesia, Jakarta 14440, Indonesia*

Background: Premature ventricular complexes (PVCs) are common ventricular arrhythmias in healthy individuals, often detected on electrocardiograms (ECGs) or during rhythm monitoring. It can mimic the symptoms of thyroid heart disease (THD), such as palpitations or dizziness, and may negatively affect left ventricular function over time, potentially leading to heart failure. Hyperthyroidism increases the risks of cardiac arrhythmias and THD. Hyperthyroidism is known to cause sinus tachycardia, a shortened PR interval, and increased P-wave duration due to prolonged interatrial conduction. However, to date, there are limited studies on the association between PVCs and hyperthyroidism. Understanding the suspected cardiac implications is crucial for managing hyperthyroidism in patients with PVCs.

Case Illustration: A 53-year-old woman presented to the emergency department (ED) with a 6-week history of persistent palpitations and prolonged chest discomfort that did not resolve upon arrival. Laboratory evaluation showed hyperthyroidism (FT4: 2,44; TSH: 0.01; T3: 1.98), and electrolyte imbalance (hypokalemia [3,2 mmol/L], hypocalcemia [8,4 mmol/L], hypomagnesemia [1,51 mmol/L]). Propylthiouracil 3×100 mg was administered at the ED, and the patient was referred for evaluation by an endocrinologist and cardiologist. The ECG results recorded at the ED showed sinus rhythm, frequent PVC, and alternating periods of trigeminy and bigeminy, suspected to originate from the septal right ventricular outflow tract (RVOT). Echocardiography showed a left ventricular ejection fraction (LVEF) of 46%. Electrocardiogram Holter results showed 31,430 ventricular ectopic beats, with a PVC burden of 24.8%, consisting of 14,531 isolated, 286 Couplets, 1,410 bigeminy, and 697 Trigeminy. Regarding malignant PVCs, the patient was referred to a cardiac electrophysiologist for consideration of PVC ablation.

Conclusion: Hyperthyroidism may cause PVCs by altering the cardiac electrophysiology, ion channels, and vascular function. We suspect that this imbalance leads to increased sympathetic activity and reduced heart rhythm regulation. Hyperthyroidism also increases the expression of potassium receptors, leading to arrhythmias. The direct correlation between PVCs and hyperthyroidism, alongside THD, remains ambiguous; thus, it is imperative to evaluate the ablation treatment regarding the frequency of PVCs in patients with hyperthyroidism.

Keyword: Arrhythmia; Premature Ventricular Contractions (PVC); hyperthyroidism; thyroid heart disease; electrolyte imbalance

[12INAHRS-CR79]

Optimizing Ablation Success: A Modified Approach for Right Lateral Accessory Pathway

M. Fatchi¹, P. Ardhianto¹

¹Department of Cardiology and Vascular Medicine, Kariadi Central Hospital Semarang, Indonesia

Background: Supraventricular tachycardia (SVT) is a common tachyarrhythmia. Accessory pathways (APs) are substrates for atrioventricular reentrant tachycardia (AVRT), the second most common form of supraventricular tachycardia. Radiofrequency ablation (RFA) can be an effective treatment for SVT, with cure rates exceeding 95% for AVRT and AVNRT.

Case Illustration: A 15-year-old girl presented with recurrent palpitations since the age of 8 years. The previous ECG showed narrow QRS complex tachycardia with an obvious P wave after the QRS complex and a long RP interval (160 ms). An EP study was performed. His-refractory ventricular premature beat (VPB) showed reset. A VA (Ventricular-Atrial) fusion beat can be observed during narrow complex tachycardia and ventricular pacing, indicating atrioventricular reentrant tachycardia. Coronary sinus (CS) propagation showed that atrial activation was earlier at the HRA catheter than at the His or CS. This finding suggests the presence of a septal or right-sided accessory pathway.

The basic interval measurements during sinus rhythm were normal. Incremental atrial pacing showed a block of antegrade ventricular activation at 340 ms with decremental properties. Incremental ventricular pacing showed a block of retrograde conduction at < 300 ms without decremental properties.

The ablation catheter was directed along the tricuspid annulus (TA). Mapping around 9-10 o'clock of the TA showed VA fusion and concentric atrial activation, suggesting a right lateral accessory pathway as the retrograde limb of the supraventricular tachycardia.

Ablation was performed in this area. Multiple RFAs (30 watts, 55 °C, 60 s) were performed, and a retrograde VA conduction block was observed during ventricular pacing. The procedure was successful and was terminated. Unfortunately, the SVT recurred early after the procedure. A repeat ablation was performed one month later and was successful. In this second attempt, a long sheath catheter was used to maintain the stability of the ablation catheter during multiple RFA deliveries

Conclusion: Recurrence of atrioventricular reentrant tachycardia (AVRT) has been reported in up to 12% of patients during follow-up after successful ablation. Patients with right free wall and right posteroseptal AP have been shown to have a higher recurrence rate than those with left-sided AP. For the right lateral accessory pathways, poor contact accounted for 70% of failures.

Keywords: SVT; AVRT; accessory pathway; ablation; recurrence

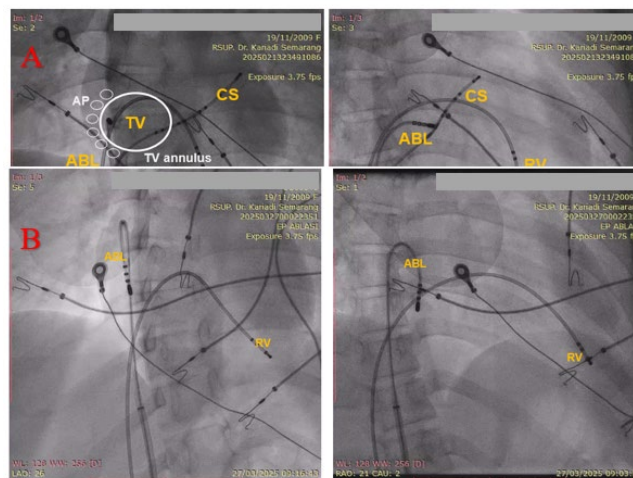


Figure 1. (A) First ablation attempt and (B) second ablation attempt using a long sheath catheter.

[12INAHRS-CR80]

Supraventricular Tachycardia in Post-Partum Preeclampsia: A Case Report

F.J. Pranawa¹, M.Z. Kurniawan²

¹General Practitioner, Soedarsono General Hospital, Pasuruan, Indonesia

²Departement of Cardiology and Vascular Medicine, Soedarsono General Hospital, Pasuruan, Indonesia

Background: Supraventricular tachycardia (SVT) is the most common tachyarrhythmia observed during pregnancy or the immediate postpartum period. It can develop de novo or be exacerbated during pregnancy. While generally considered benign, SVT during pregnancy is associated with higher in-hospital mortality and morbidity. Some cases present with mild symptoms or go unrecognized, but in rare cases, as illustrated here, patients present with severe symptoms.

Case Illustration: A 22-year-old woman was admitted with premature rupture of membranes and preeclampsia. The patient had no history of cardiovascular abnormalities. Expectant management with close obstetrics and gynecology team monitoring was preferred. The patient had a spontaneous vaginal delivery in the maternity ward, complicated by a third-degree perineal tear with an estimated blood loss of 350 cc. Postpartum vital signs showed a blood pressure of 160/100 mmHg, heart rate of 96 beats/min, and respiratory rate of 24 breaths/min. One hour after delivery, the patient developed shortness of breath and palpitations, accompanied by a significant increase in vital signs: heart rate of 178 beats/min and respiratory rate of 30 breaths/min. A 12-lead electrocardiogram revealed tachyarrhythmia at a rate of 170 beats per minute, right bundle branch block morphology, left axis deviation, and a suspected prolonged QT interval. A cardiology consultation was obtained, and supraventricular tachycardia with bundle branch block electrical alternans was diagnosed, with an accessory pathway suspected in the patient. The patient was transferred to the intensive care unit and received intravenous diltiazem (50 mg), which successfully converted the patient to sinus rhythm. Further investigations, including echocardiography, indicated left ventricular hypertrophy with normal systolic and diastolic functions.

Conclusion: Supraventricular tachycardia during labor or immediately after delivery is a clinical challenge. Although the management is similar in non-pregnant patients, the unavailability of antiarrhythmic drugs and electrical cardioversion in the delivery room can delay the treatment of arrhythmias during pregnancy.

Keywords: Supraventricular Tachycardia, Pregnancy, Arrhythmia

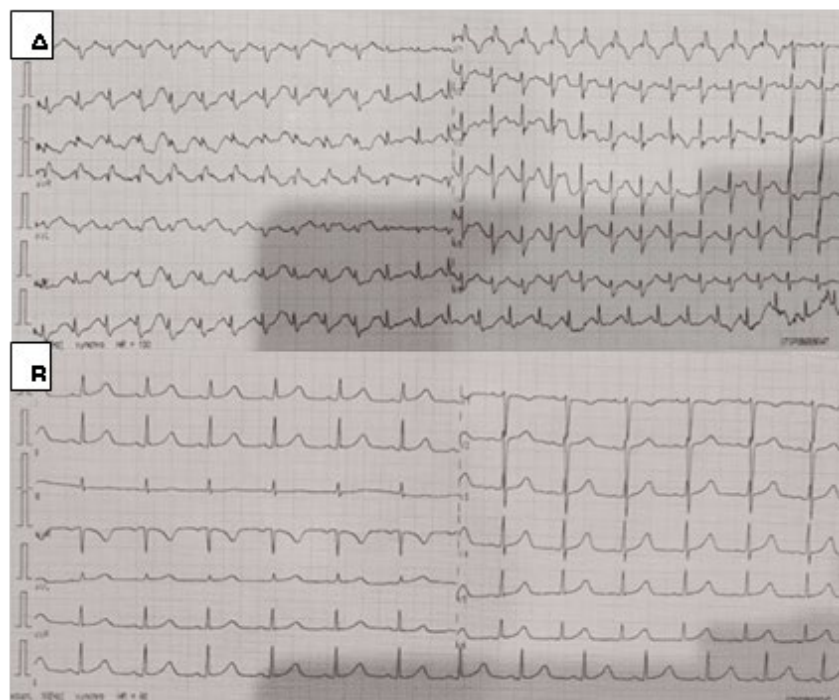


Figure 6. (A) ECG after delivery, (B) ECG after intravenous diltiazem administration.

[12INAHRS-CR81]

Every Minute Counts: The Role of Modified Valsalva in SVT with Varied Symptom Onset

I. N. Guntur^{1,2}

¹RSAD TK II Pelamonia, Makassar, Indonesia

²Faculty of Medicine, Universitas Hasanuddin, Makassar, Indonesia

Background: Supraventricular tachycardia (SVT) is a common acute arrhythmia that requires immediate management. The Modified Valsalva Maneuver (MVM) is a useful non-pharmacological intervention for acute SVT management. Early diagnosis and timely management are vital to prevent long-term cardiac damage and improve the overall outcomes of affected patients. This case series highlights how the timing of symptom onset may influence MVM success, offering insights into time-sensitive approaches in acute cardiovascular care.

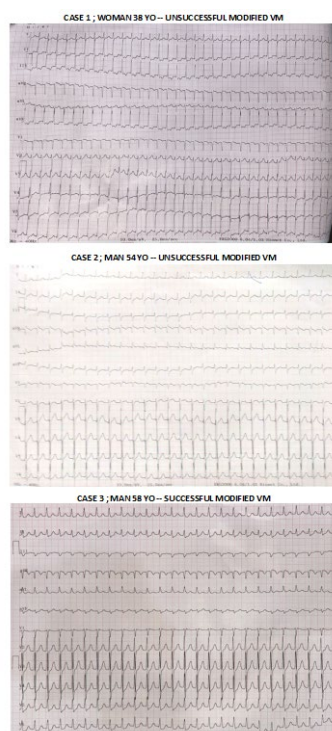
Case Illustration: We present three patients with SVT, with varying onset times and responses to MVM. Case 1: A 38-year-old woman experienced palpitations and chest discomfort 3 hours prior to admission. MVM failed after three attempts, and pharmacologic treatment with digoxin and oral bisoprolol was administered. Case 2: A 54-year-old man presented with persistent palpitations for over 12 hours before admission. MVM failed. He was then administered digoxin, amiodarone, and bisoprolol, which led to gradual rhythm control. Case 3: A 58-year-old man presented 30 minutes after symptom onset with sudden palpitations. MVM successfully restored sinus rhythm without pharmacological intervention. All patients showed clinical improvement and were discharged with oral beta-blocker therapy.

This case series highlights the time-sensitive nature of SVT management. MVM was effective only in patients with the shortest symptom onset (<1 hour), underscoring the importance of early recognition and immediate non-pharmacologic intervention. Pharmacological therapy remains essential when MVM fails, particularly in cases of delayed presentation. In our setting, the unavailability of adenosine, a recommended first-line agent, necessitated the use of alternative medications such as digoxin and amiodarone. Despite our urban location, adenosine remains inaccessible in Indonesia.

Conclusion: The effectiveness of MVM in terminating SVT may correlate with the timing of the intervention, suggesting that every minute counts in restoring the rhythm. These cases reinforce the need for early detection and prompt action in SVT, especially in resource-constrained settings, to maximize noninvasive success, reduce dependence on medications, and enhance overall outcomes. Further observational studies are needed to quantify the time-dependent success rate of MVM and promote timely rhythm management in Indonesian emergency settings, both urban and rural.

Keywords: supraventricular tachycardia, modified Valsalva maneuver

Figure 1. Patients' 12-lead ECG on ED admission.



[12INAHRS-CR82]

The Challenging Therapeutic Decision: Radiofrequency Ablation in Wolff-Parkinson-White Patient with Metastatic Lung Cancer – A Case-Based Review

A.P. Wulandari^{1,2}, A.F. Rahimah², A. Rizal²

¹Faculty of Medicine, Universitas Brawijaya, Malang, East Java, Indonesia

²Department of Cardiology and Vascular Medicine, Universitas Brawijaya, Saiful Anwar General Hospital, Malang, East Java, Indonesia

Background: Radiofrequency ablation (RFA) is effective and safe for patients with symptomatic Wolff-Parkinson-White (WPW) syndrome. However, there are limited case reports on the efficacy and safety of RFA in patients with WPW syndrome and metastatic lung cancer undergoing chemotherapy.

Case Illustration: We reported a case of a 52-year-old man with symptomatic WPW syndrome and metastatic lung cancer under routine chemotherapy with zoledronic acid. He had a history of recurrent ventricular tachycardia (VT) that mostly terminated by cardioversion. The first 12-lead electrocardiogram (ECG) from the previous hospital revealed AF with pre-excitation. He presented to the Emergency Room (ER) of our hospital with palpitations. The ECG in the ER showed SVT AVRT. We performed a Valsalva maneuver, which converted to sinus tachycardia with a WPW pattern originating from the left posteroseptal accessory pathway. Challenging therapeutic decision-making is required to address this issue. We must consider not only solving the WPW that induces recurrent life-threatening VT but also evaluating the presence of metastatic lung cancer. Several potential complications associated with RFA, including its radiation effects on lung cancer recurrence and bleeding risk, must be comprehensively assessed. We performed 2D radiofrequency ablation (RFA), which successfully resolved the WPW. The patient was discharged without any complications. During follow-up, the patient had no recurrence of symptoms and continued chemotherapy.

Conclusion: This case illustrates that 2D RFA has become a challenging therapeutic decision-making in a WPW patient with metastatic lung cancer and must be comprehensively assessed between potential risks and benefits. The result can provide evidence that 2D RFA is effective and safe for WPW patients with metastatic lung cancer.

Keywords: Wolff-Parkinson-White syndrome, Metastatic lung cancer, 2D Radiofrequency ablation

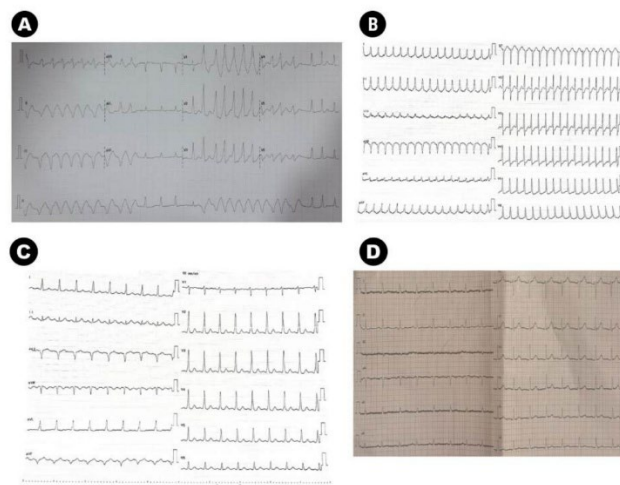


Figure 1A. The first 12-lead ECG showed Atrial Fibrillation with Preexcitation

Figure 1B. The 12-lead ECG showed a Supraventricular Tachycardia (SVT) AVRT

Figure 1C. The 12-lead ECG post Valsalva maneuver showed sinus tachycardia with episode of WPW syndrome

Figure 1D. The 12-lead ECG after 2D ablation revealed diminished delta wave

[12INAHRS-CR83]
**Femoral Snaring Retrieval of an Entrapped Anchoring Sleeve During Permanent Pacemaker
Implantation**

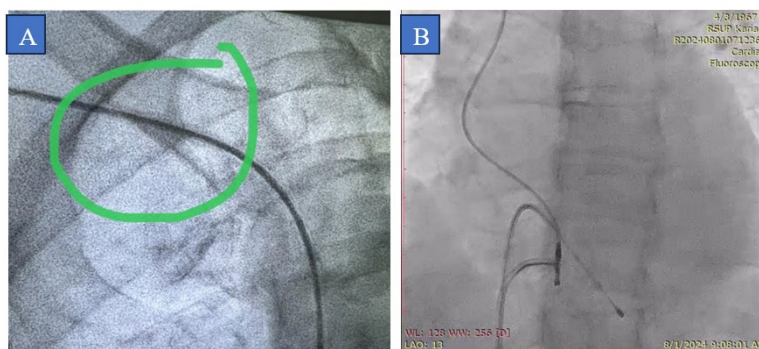
A.Y.Amany¹, D.Yoga¹, Efendi¹, P.Ardhianto¹, A.Y.A.B.Mochtar¹

¹Department of Cardiology and Vascular Medicine, Faculty of Medicine,
Diponegoro University – Dr. Kariadi Central General Hospital, Semarang, Indonesia

Background: Permanent pacemaker (PPM) implantation is the standard therapy for symptomatic sinus node dysfunction (SND). While generally safe, technical complications can occasionally occur, especially during lead placement and sheath manipulation. One rare but challenging issue is the unintentional migration or entrapment of the anchoring sleeve that guides the pacemaker lead. If not managed carefully, such a complication may risk vascular injury or lead to dislodgement. This report describes the successful resolution of a stuck anchoring sleeve using a femoral venous snare during a single-chamber atrial pacemaker implantation.

Case Illustration: A 57-year-old woman with documented SND had previously undergone temporary pacing. She was scheduled for permanent pacemaker implantation due to persistent bradyarrhythmia. Under local anesthesia, access was obtained via the right cephalic vein, and an active fixation atrial lead was successfully placed in the right atrial appendage with stable parameters (P wave 2.5 mV, threshold 2.2 V at 0.40 ms, impedance 539 ohms). During the procedure, the anchoring connector sleeve was inadvertently pushed into the vein and became lost. The device was not visualized using fluoroscopy. Gentle traction failed to retrieve it, and further force was avoided to prevent vascular damage. A retrieval attempt was employed via left femoral vein access. A snare catheter (CLS 3.5/7F) was advanced under fluoroscopic guidance, allowing successful capture and extraction of the sleeve. The lead remained in the optimal position throughout. The generator was connected, and atrial pacing was performed. It was implanted in AAIR mode, set at a rate of 60–130 bpm. The pocket was irrigated with ampicillin-sulbactam, and the wound was closed in a layered fashion. The temporary pacemaker was removed, and the procedure was completed without complications.

Conclusion: This case illustrates an uncommon complication during pacemaker implantation involving intravascular migration of the anchoring sleeve. Retrieval via femoral venous access using a snare catheter under fluoroscopic guidance is an effective approach in this situation. Timely recognition and careful technique helped avoid additional complications and allowed the procedure to proceed without disrupting lead position.



(A) Fluoroscopic image showing the entrapped pacemaker anchoring sleeve (outlined in green) during lead implantation, highlighting abnormal positioning and resistance to advancement.
(B) Successful retrieval of the entrapped sleeve using femoral vein snaring technique, confirmed by the fluoroscopic visualization of the extraction path.

[12INAHRS-CR84]

Navigating Complexity: A Case of Successful Management in Multifocal PVC-Related Heart Failure with Reduced Ejection Fraction

N.A.R.S.N. Putra¹, I.K. Susila²

¹*Emergency Department, BaliMed Buleleng Hospital, Buleleng, Bali*

²*Department of Internal Medicine, Cardiology and Vascular Medicine Division, Buleleng General Hospital, Buleleng, Bali*

Background: Premature ventricular contractions (PVCs) are common arrhythmias frequently encountered in clinical practice. A high burden of PVCs can induce or exacerbate cardiomyopathy, known as PVC-induced cardiomyopathy. The emergence of new-onset multifocal PVCs in a patient with Heart Failure with reduced Ejection Fraction is a significant clinical finding. The relationship between PVCs and HFrEF can be complex, often forming a vicious cycle in which each exacerbates the other.

Case illustration: A 61-year-old woman presented to the ER with a sudden and persistent headache that began one day before admission, with blurred eyesight and weakness. History of uncontrolled hypertension. Her BP was 180/100 mmHg with a HR of 104 BPM, accompanied by an initial ECG showing sinus tachycardia with multifocal PVCs. Chest X-ray also showed cardiomegaly, and laboratory results indicated mild hypokalemia and hyponatremia. The patient was admitted to the ICU, and bedside echocardiography revealed eccentric LVH (EF 26.27 %), accompanied by moderate MR and mild AS. The patient received Amiodarone 1x200 mg PO; Bisoprolol 1x1.25 mg PO; Candesartan 1x8 mg PO; Spironolactone 1x25 mg PO; NTG 5 mcg/min via SP; Furosemide 2x20 mg IV; Pantoprazole 1x40 mg IV; and IVFD RL 20 dpm. The patient was hospitalized for three days, improved, and discharged with the same medication.

Conclusion: This case serves as a valuable reminder for clinicians to maintain a high index of suspicion for PVC-induced cardiomyopathy in patients presenting with unexplained HFrEF and a substantial PVC burden, regardless of the complexity of PVC morphology.

Keywords: ejection fraction, heart failure, premature ventricular contraction

[12INAHRS-CR85]

Acute Coronary Syndrome After Catheter Ablation: Mechanism and Clinical Implications

N. A. R. S. N. Putra¹, K. H. V. Mardaningrat¹, I Ketut Susila³

¹*Emergency Department, Balimed Buleleng Hospital, Bali, Indonesia*

²*Department of Internal Medicine, Faculty of Medicine, Universitas Pendidikan Ganesha – Buleleng General Hospital, Buleleng, Bali, Indonesia*

Background: Cardiovascular disease (CVD), particularly acute coronary syndrome (ACS), is the leading global cause of mortality. Atypical presentations, such as isolated vertigo, pose significant diagnostic challenges, particularly in elderly patients with complex cardiac histories. Isolated vertigo is infrequently recognized as an initial symptom of myocardial ischemia, potentially delaying diagnosis and timely intervention.

Case Illustration: A 60-year-old male presented to the emergency department with severe spinning dizziness (vertigo) exacerbated by sitting and eye-opening, accompanied by nausea and repeated vomiting episodes. Although initially overshadowed by vertigo, chest pain characterized as compressive, radiating to the shoulder and back, was also reported. His medical history was notable for atrial fibrillation managed by catheter ablation in November 2023 and February 2024. Initial vital signs indicated an elevated pulse (105 bpm), blood pressure of 140/70 mmHg, and normal oxygen saturation. Examination revealed a systolic murmur in the mitral area without pulmonary abnormalities or peripheral edema. Electrocardiography showed significant ischemic changes, with ST-segment elevations in leads V2-V4 and reciprocal depressions in leads I and V6, consistent with anterior myocardial infarction. Initial management included intravenous fluids, dual antiplatelet therapy, nitrates, beta-blockers, statins, and diuretics administration. After clinical stabilization, echocardiography revealed concentric left ventricular dilation, grade 2 diastolic dysfunction, normal systolic function (EF 72.07%), mild aortic regurgitation, and moderate mitral regurgitation.

Conclusion: This case underscores the critical importance of recognizing isolated vertigo as a potential ACS symptom, particularly in elderly patients with significant cardiac history and previous interventions. Prompt electrocardiographic and echocardiographic evaluations are vital for accurate diagnosis, reducing diagnostic delays, and improving outcomes in atypical presentations of myocardial ischemia.

Keywords: Acute coronary syndrome, Vertigo, Catheter ablation, Atrial fibrillation

[12INAHRS-CR86]

Nightmare of Temporary Pacemaker Insertion: Post Cardiac Injury Syndrome and Myocardial Perforation mimicking as Acute Coronary Syndrome: A Case Report

R. R. Muhammad, MD¹, M. Y. Alsagaff, MD, PhD¹, F. F. Qolbina, MD¹, R. M. Putra, MD¹

¹Department of Cardiology and Vascular Medicine, Faculty of Medicine, Universitas Airlangga, Surabaya, East Java, Indonesia.

Background: Temporary cardiac pacing, including the use of a transvenous temporary pacemaker, is indicated in cases of severe bradyarrhythmia and plays an important role in critical care and emergency services. However, rare and life-threatening complications may occur. Lead displacement and myocardial perforation can cause perforation-related symptoms, pericarditis, pericardial effusion, cardiac tamponade, and an increased risk of mortality.

Case Illustration: A 48-year-old man was referred for evaluation of chest discomfort lasting 5 days. He had previously been implanted with a temporary transvenous pacemaker due to a total atrioventricular block at a rural hospital. Chest X-ray and transthoracic echocardiography (TTE) revealed cardiomegaly with moderate pericardial and pleural effusions. Electrocardiography (ECG) upon admission showed ST-segment elevation in the anteroseptal leads. Emergent coronary angiography was performed due to ongoing chest pain and elevated troponin levels, which revealed normal coronary anatomy without occlusion. However, right ventricular (RV) ventriculography showed that the tip of the pacemaker lead was outside the RV. The pacemaker lead was subsequently explanted, and surgical repair of the myocardial perforation was performed. The criteria for post-cardiac injury syndrome (PCIS) were fulfilled, and a thoracic Computed Tomography (CT) scan performed after the surgical procedure confirmed thickening of the pericardium. Anti-inflammatory drugs were administered on the following days.

Conclusion: Cardiac perforation should be considered a rare but potentially life-threatening complication in patients who have undergone invasive cardiac procedures and present with unrelenting chest discomfort. Chest X-ray (CXR), transthoracic echocardiography (TTE), and thoracic CT scans are effective diagnostic tools for detecting iatrogenic cardiac perforation. PCIS may impact disease progression and should be treated and closely monitored.

Keywords: Transvenous Pacemaker, Temporary transvenous pacemaker, Myocardial perforation, Post Cardiac Injury Syndrome

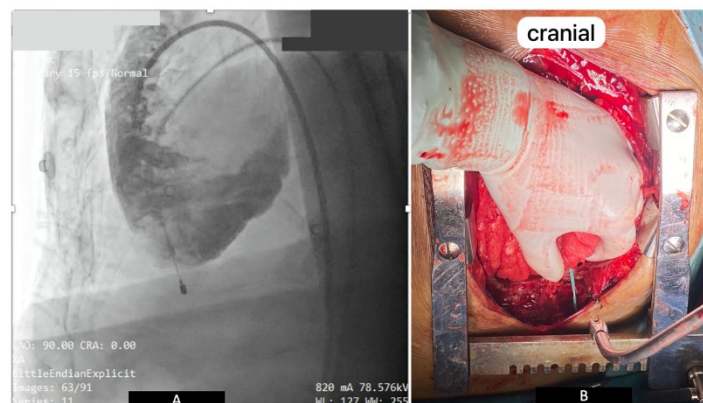


Figure 1A,1B. Ventriculography and Intrasyrgery of the Patient showed Lead Perforation of the Transvenous Temporary Pacemaker

[12INAHRS-CR87]

**Aborted Cardiac Arrest in Arrhythmic Mitral Valve Prolapse with Mitral Annular Disjunction:
Diagnostic Challenges and Management Strategies**

A.A. Adam¹, D.V. Chrismara², S.B. Raharjo²

¹*Department of Cardiology and Vascular Medicine, Faculty of Medicine,
Universitas Indonesia, Jakarta, Indonesia*

²*Division of Arrhythmia, Department of Cardiology and Vascular Medicine,
Faculty of Medicine, Universitas Indonesia, Jakarta, Indonesia*

Background: Mitral valve prolapse (MVP) is a common valvular disorder affecting 1-3% general population. While often harmless, certain features, particularly mitral annular disjunction (MAD), are associated with a higher risk of ventricular arrhythmias (VAs) and sudden cardiac death (SCD). MAD is characterized by a displacement of the mitral leaflet implantation from the ventricular myocardium, increasing the likelihood of arrhythmias if concomitant with MVP. Arrhythmic MVP (AMVP) may cause palpitations, chest pain, presyncope, or syncope. Here, we present a case of aborted cardiac arrest as the sole sign of AMVP in a MAD patient.

Case Illustration: A 41-year old woman experienced cardiac arrest after a 1.5-hour moderate-intensity exercise session. CPR and defibrillation were immediately performed by a bystander until ROSC was achieved, before the patient was transported to the hospital. She had no previous complaints, history of cardiovascular disease, or family history of sudden cardiac death. Laboratory examination revealed mild hypokalemia (3.2 mmol/L). She was then referred to the National Cardiovascular Center Harapan Kita for further investigation. Electrocardiography revealed sinus bradycardia (54 beats/minute), T-wave inversions (TWI) in the inferior leads, and left ventricular hypertrophy. The 24-hour Holter monitoring revealed multifocal benign premature ventricular contractions consistent with the origin from the anterior papillary muscle. Echocardiography showed a normal left ventricular ejection fraction, moderate mitral regurgitation, and MAD, which was then confirmed to be bileaflet MVP with MAD by cardiac magnetic resonance imaging. Given the history of aborted cardiac arrest, implantable cardioverter defibrillator (ICD) implantation was deemed the most appropriate strategy for secondary SCD prevention.

Conclusion: MVP is a benign but significant risk factor for SCD, especially in the presence of MAD. MVP patients are required to undergo a comprehensive evaluation to identify those at high risk of VAs. Holter monitoring and echocardiography should be routinely performed to diagnose AMVP, MAD, and other MVP phenotypes, despite the absence of classic VA manifestations. Regardless of the cardiac arrest episode, the presence of several phenotypical risk features, such as TWI, multifocal PVCs, and MAD, deemed this patient necessary for more comprehensive investigation, and an ICD should be considered to reduce the mortality of this high-risk patient profile.

Keywords: Mitral valve prolapse, Mitral annular disjunction, Ventricular arrhythmia, Sudden cardiac death

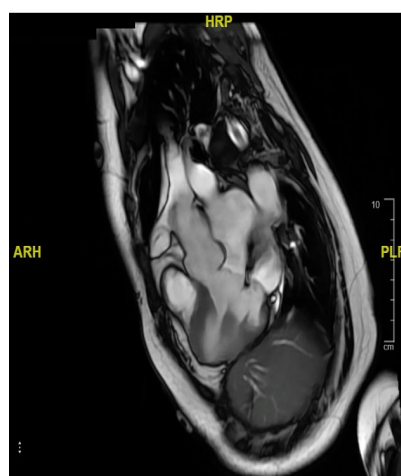


Figure 1. Cardiac magnetic resonance imaging showing bileaflet mitral annular disjunction.

[12INAHRS-CR88]

Degenerative Conduction Disease in the Elderly: A Case Series of Symptomatic Sinus Node Dysfunction and Total Atrioventricular Block

A. R. Fadhlan¹, W. Pipiet², S. Suryono², S. M. Adhita², A. Dwi²

¹General Practitioner Intern in the Cardiology Division, Soebandi Regional General Hospital, Jember, East Java, Indonesia

² Department of Cardiology, Soebandi Regional General Hospital, Jember, East Java, Indonesia

Background: Bradycardia remains a significant clinical challenge worldwide, particularly in developing countries, where diagnostic and therapeutic resources may be limited. This case series aims to describe the clinical presentation, diagnostic considerations, and management strategies for symptomatic degenerative bradycardia in elderly patients, highlighting the role of individualized treatment decision-making in complex cases.

Case Illustration: This case series highlights symptomatic degenerative bradycardia in elderly patients, focusing on individuals aged over 75 years who experienced witnessed syncope with no history of atrioventricular (AV) nodal blocking agents, electrolyte disturbances, myocardial infarction, valvular surgery, or early onset syncope. Three cases were included, with a mean age of 81.6 ± 3.7 years. Two patients exhibited sinus node dysfunction manifesting as sick sinus syndrome with junctional escape rhythms, whereas one presented with complete AV block. One patient with sinus node dysfunction had a sequela of ischemic stroke, likely related to arrhythmia-induced hypoperfusion and thrombus formation. Permanent pacemaker (PPM) implantation was indicated in two patients with hemodynamic instability. In contrast, one patient was not implanted with a permanent pacemaker due to the patient's age, severe frailty, bedridden status, sinus rhythm conversion, and clinical response to beta-2 agonists.

Conclusion: Degenerative bradycardia in the elderly requires a comprehensive clinical approach. A comprehensive assessment, including cardiac monitoring and hemodynamic evaluation, is critical in determining the appropriateness of permanent pacemaker implantation, especially when balancing the treatment benefits against the risks in frail elderly patients.

Keywords: Degenerative, Symptomatic Bradycardia, Permanent Pacemaker

Table 1. Summary of the Case Characteristics.

Characteristic	Patient 1	Patient 2	Patient 3
Demographic			
Age	79	87	79
Gender	Male	Female	Female
Race	Asian	Asian	Asian
BMI	20.2	18	20
Comorbidities			
Diabetes	No	No	No
History Hypertension	Yes	No	Yes
Obesity	No	No	No
Coronary Artery Disease	No	No	No
Clinical Features			
Symptom related to Bradycardia	Yes	Yes	Yes
Length of Stay	5 days	4 days	7 days
ICCU Hospitalization	Yes	Yes	Yes
Requiring O2 supplementation	Yes	No	No
BP at admission	190/110	110/60	200/104
Management	Permanent Pacemaker	Salbutamol 3x4mg	Permanent Pacemaker
Diagnostic Examination			
Electrocardiography	Sick sinus syndrome with junctional bradycardia escape rhythm and PVC	Sinus node dysfunction junctional bradycardia escape rhythm	Complete AV block and accelerated idioventricular escape rhythm
CXR	Cardiomegaly, pleural effusion bilateral	Normal	Cardiomegaly
Echocardiography	LVEF 32.9%	LVEF 64% Diastolic dysfunction gr I	LVEF 74.8% Diastolic dysfunction gr I
Holter-24 hours	-	Sinus pause 8.842 ms, atrial fibrillation <1%, HR max 112 bpm HR min 18 bpm, PVC 2%	-
CT Scan	Acute thrombotic cerebral infarction corona radiata dextra	Acute thrombotic cerebral infarction basal ganglia dextra	-

[12INAHRS-CR89]

Syncope and Extreme Bradycardia with Ventricular Escape Rhythm due to Non ST-Elevation Acute Coronary Syndrome and Hyperkalemia: Diagnostic and Management Challenges in Rural Area

A. Ramadhanti¹, K. S. L. Sugitha²

¹Lewoleba General Hospital, Lembata, NTT, Indonesia

²Internal Medicine Department, Udayana University, Bali, Indonesia

Introduction: A ventricular escape rhythm occurs whenever higher-level pacemakers in the atrioventricular (AV) junction or sinus node fail to control ventricular activation, with a rate of 20-40 bpm and broad QRS complexes. The etiologies range from AV block, sinus arrest, ischemia, to electrolyte abnormalities, especially hypercalcemia. This condition is life-threatening because of a sudden decrease in cardiac output, leading to syncope. Recognizing the etiology remains important for appropriate management. Diagnosis and management are challenging in rural areas.

Case Illustration: A 68-year-old man was admitted with a sudden loss of consciousness for 15 minutes. He had no complaints, no history of prior cardiac disease, and had previously normal activity. Blood pressure and respiration were normal, but the heart rate was only 28 bpm. No lateralization. The ECG shows extreme bradycardia, no P wave, ventricular escape rhythm with LBBB morphology suggesting from the right bundle branch, and ST depression with tall T in V3-V5. Atropine sulfate was administered immediately, and the heart rate increased to 56 bpm. Evaluation of the ECG showed that tall T waves became greater with ST depression, indicating subendocardial ischemia. Loading doses of aspirin, clopidogrel, and heparin were administered. Kalium was 7,2 then calcium gluconate, insulin, and salbutamol were also administered. Two hours later, ST depression in V5-V6 and T inverted or biphasic T waves in the inferior leads were observed. The patient gradually regained consciousness and complained of mild chest pain. Eight hours later, the ECG showed sinus rhythm, T waves were normal in all leads, vital signs were normal, and chest pain was resolved.

Conclusion: ECG is the fastest and most readily available bedside tool for identifying life-threatening arrhythmias. However, interpreting an ECG for diagnostic purposes requires extensive practice and experience. Moreover, the identification of acute coronary occlusion is critical for determining the need for emergency reperfusion therapy. The diagnosis was Non-ST-Elevation Acute Coronary Syndrome because troponin testing is unavailable in rural areas, and referrals are difficult. Although emergency therapy was administered, extreme bradycardia requires advanced management based on etiology and expert consultation.

Keywords: Ventricular Escape Rhythm, Acute Coronary Syndrome, Syncope, Extreme Bradycardia

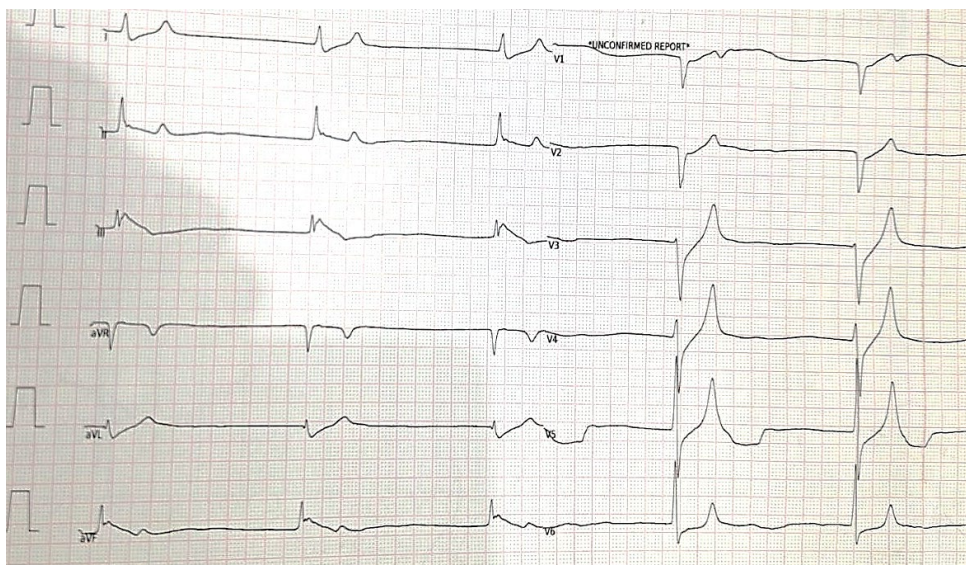


Figure 1. ECG on Admission.

[12INAHRS-CR90]

Taming the Storm Within: Left Cardiac Sympathectomy in Congenital Long QT Syndrome with Frequent Shocks—A 2-Year Case Perspective

F.R. Tua¹, G. Karwiky¹, M. Iqbal¹, C. Achmad¹

¹*Department of Cardiology and Vascular Medicine, Universitas Padjadjaran, Bandung, Indonesia*

Background: Concomitant acute lymphocytic myocarditis and congenital long QT syndrome (LQTS) is a rare but life-threatening condition that can precipitate electrical storms and incessant Torsade de Pointes (TdP). Inflammatory stress and autonomic imbalance may exacerbate repolarization abnormalities in genetically predisposed patients. Multimodal therapy is often required for acute stabilization and long-term prevention of arrhythmia.

Case Illustration: An 18-year-old Southeast Asian woman, one-week postpartum following cesarean section for severe preeclampsia, presented with electrical storm and sustained TdP. Electrocardiography showed a prolonged QTc interval up to 696 ms. Despite the administration of lidocaine, magnesium sulfate, sedation, and overdrive pacing, the arrhythmia persisted. Cardiac magnetic resonance imaging and endomyocardial biopsy confirmed the diagnosis of lymphocytic myocarditis. Initial beta-blockade with bisoprolol was escalated to propranolol and then switched to carvedilol with clinical improvement. The patient underwent left cardiac sympathetic denervation (LCSN) and implantable cardioverter-defibrillator (ICD) implantation. Corticosteroids were initiated for myocarditis. Two months later, the QTc shortened to 624 ms, and no further premature ventricular contractions or ventricular tachycardia (VT) episodes were observed. At the 2-year follow-up, echocardiography showed normalization of the left ventricular systolic function (LVEF 58%) and chamber sizes. ICD interrogation documented 25 ventricular tachyarrhythmia episodes; most were terminated by antitachycardia pacing (ATP), and four required 35-joule shocks. Ventricular sensing was 100% with <0.1% ventricular pacing burden. The patient was clinically stable on bisoprolol 5 mg once daily (de-escalated from 12.5–6.25 mg/day), ramipril 2.5 mg twice daily (up-titrated from once daily), and spironolactone 12.5 mg once daily. No recurrence of myocarditis symptoms or complications from LCSN or ICD, such as Horner's syndrome or infection, was observed. All domains of the SF-36 improved significantly, reflecting enhanced quality of life, clinical stability, and absence of ICD shocks.

Conclusion: This case illustrates the complex management of dual pathology involving myocarditis and congenital LQTS. LCSN and individualized beta-blockade were effective in reducing arrhythmic burden, whereas ICD therapy ensured secondary prevention. QTc duration remained prolonged, consistent with congenital LQTS, but inflammatory and autonomic triggers were successfully mitigated. Long-term follow-up confirmed the normalization of systolic function and stable arrhythmia control, emphasizing the value of a comprehensive, tailored approach in high-risk arrhythmogenic syndromes.

Keywords: long QT syndrome; lymphocytic myocarditis; electrical storm; left cardiac sympathetic denervation; implantable cardioverter-defibrillator

[12INAHRS-CR91]

Fat Infiltration and Atrial Remodeling in Atrial Fibrillation: Comprehensive Evaluation Using Cardiac Magnetic Resonance Imaging

M. Eria¹, H. Arifianto²

¹Department of Cardiology and Vascular Medicine, Faculty of Medicine, Sebelas Maret University

²Sebelas Maret University Hospital, Surakarta, Indonesia

Background: Atrial fibrillation (AF) is a progressive supraventricular arrhythmia that is frequently associated with various cardiovascular risk factors, such as hypertension, dyslipidemia, and obesity. Atrial remodeling, fibrosis, and epicardial adipose tissue (EAT) infiltration have been shown to contribute to the pathogenesis of AF. Cardiac magnetic resonance imaging (CMR) is an important noninvasive modality for the comprehensive evaluation of arrhythmogenic substrates and structural changes in the atria.

Case Illustration: A 45-year-old man presented with palpitations and an irregular pulse that had occurred intermittently over the past year. AF was first detected approximately five months prior. The patient also had a history of hypertension, dyslipidemia, and being overweight. A 48-hour Holter monitoring revealed a high AF burden of 60% during the total monitoring time. Transthoracic echocardiography revealed left atrial dilation with a left atrial volume index (LAVI) of 35.53 ml/m². Left atrial strain analysis using speckle-tracking echocardiography in the 4-chamber and 2-chamber views demonstrated left atrial dysfunction, with reduced reservoir, conduit, and contractile phase strain values of 23%, -17%, and -7%, respectively. Electrophysiological study revealed inducible arrhythmias, including atypical atrial flutter (AFL) and persistent AF, with occasional episodes of typical counterclockwise AFL. CMR showed left atrial enlargement with LAVI of 57.68 ml/m², accompanied by fibrosis in the posterior interatrial septum and EAT infiltration in the anterior left atrium and posterior septum, comprising 52.3% of the total left atrial wall (Utah stage IV). Massive pericardial fat accumulation was also observed anterior to the right ventricle. These findings indicate atrial cardiomyopathy with an extensive arrhythmogenic substrate, which may reduce the efficacy of ablation therapy, increase the risk of post-ablation AF recurrence, and elevate the risk of thromboembolic complications. A comprehensive therapeutic approach, including blood pressure control, weight management, renin-angiotensin-aldosterone system inhibition, lifestyle modification, stroke prevention, and management of other risk factors is essential.

Conclusion: CMR plays a crucial role in identifying structural atrial abnormalities, such as dilation, fibrosis, and EAT infiltration, which contribute to the pathogenesis and prognosis of AF. CMR-based substrate evaluation enables more accurate risk stratification and the development of personalized treatment strategies for patients with AF.

Keywords: atrial fibrillation, atrial cardiomyopathy, atrial fibrosis, epicardial adipose tissue, CMR

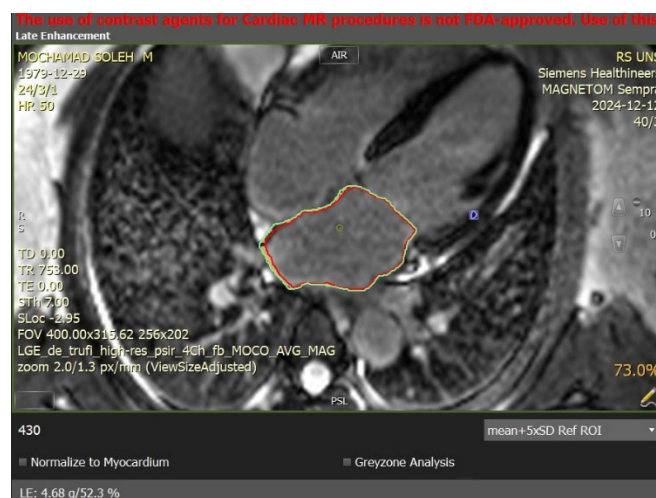


Figure 1. Assessment of left atrial fibrosis using the *Late Gadolinium Enhancement* technique in the 4-chamber view. The examination revealed that the fibrotic tissue comprised 52.3% of the total left atrial wall area. The fibrotic regions are highlighted in yellow.

[12INAHRS-CR92]

Bizarre ECG Findings Mistaken for Ventricular Tachycardia: A Case Report

N.M. Asoehan¹, A.Z.Z. Dahlan¹

¹Department of Cardiology and Vascular, North Jakarta Regional Hospital, North Jakarta, Indonesia

Background: A Fragmented QRS (f-QRS) is a conduction abnormality that indicates the presence of a myocardial scar and is associated with ventricular arrhythmias.

Case Illustration: A 40-year-old male with no history of cardiac disease was admitted in a state of shock accompanied by extreme tachycardia (140 bpm), diaphoresis, chest discomfort, and severe vomiting for 1 day before admission. Electrocardiography showed a regular, wide QRS with bizarre multiple RSR' patterns.

Discussion: F- wide QRS complexes (>120 ms) were defined as various RSR' patterns with >2 R waves or >2 notches in the R or S waves. The patient was initially diagnosed with ventricular tachycardia and was administered amiodarone. However, the patient's condition rapidly deteriorated, and he developed cardiac arrest. Administration of antiarrhythmic agents, such as amiodarone, which is standard for VT, may not be appropriate in the setting of pseudo-VT due to f-QRS and can carry hemodynamic risks.

Conclusion: This case highlights the potential for misdiagnosis of fragmented QRS as ventricular tachycardia, particularly in patients with chronic kidney disease. Accurate interpretation of ECG patterns is essential to prevent inappropriate treatment and improve clinical outcomes. Clinicians must be aware of this mimicry, especially when facing wide QRS tachycardia with atypical features.

Keywords: Bizarre ECG, Fragmented-QRS, Arrhythmia

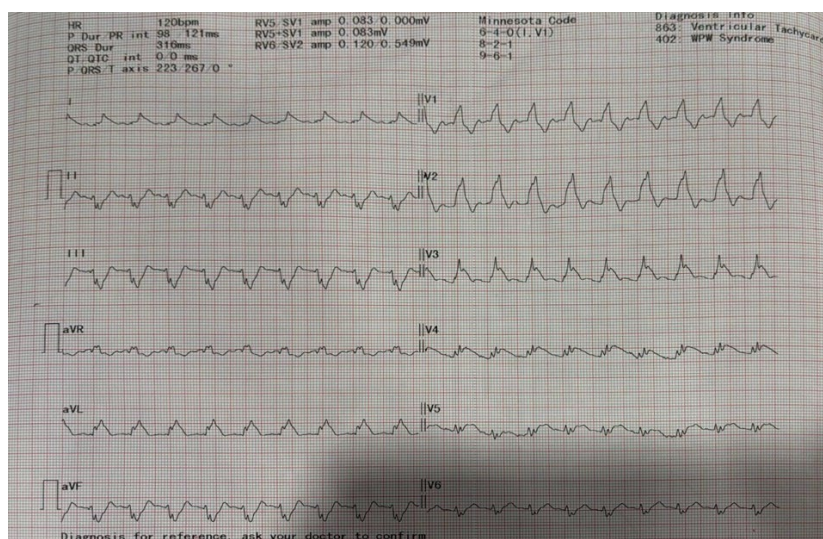


Figure 1. The Patient's Initial ECG.

[12INAHRS-CR93]
**Transient Ventricular Standstill After Pulsed-Field Cavotricuspid Isthmus Ablation:
A Case Report**

J.O. Santoso¹, D.V. Chrismara², S.B. Raharjo²

¹*Department of Cardiology and Vascular Medicine, Faculty of Medicine,
Universitas Indonesia, Jakarta, Indonesia*

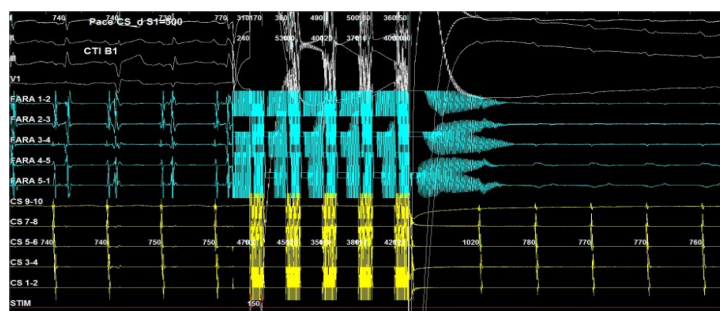
²*Division of Arrhythmia, Department of Cardiology and Vascular Medicine,
Faculty of Medicine, Universitas Indonesia, Jakarta, Indonesia*

Background: Pulsed-field ablation (PFA) is increasingly used for the cavotricuspid isthmus (CTI). The latest registries have demonstrated that PFA is efficacious and safe for atrial fibrillation (AF), including small portions of atrial flutter (AFL) patients. Coronary vasospasm has been acknowledged as a complication of PFA; however, transient conduction disturbances have rarely been reported. Here, we report a case of transient ventricular standstill after PFA on the CTI with no evidence of coronary vasospasm.

Case Illustration: A 74-year-old woman with a history of failed radiofrequency ablation (RFA) pulmonary vein (PV) isolation for AF underwent PFA for AT and persistent AF under general anesthesia. The activation map displayed re-entrant atrial tachycardia (AT) arising from the left PV carina. PFA with the FARAWAVE ablation catheter successfully terminated AT. PV potentials were present in all PVs; eight applications per PV and 12 additional applications on the posterior wall were delivered. Pacing from the coronary sinus 7-8 catheter then induced typical AFL. The activation map obtained using an HD grid catheter confirmed a CTI-dependent AFL, and the ablation catheter was positioned appropriately without any His deflection. Intravenous nitroglycerin was administered before the CTI ablation. Right before the first "basket" delivery, the FARAWAVE catheter recorded a His bundle deflection, which went unnoticed and resulted in a prolonged episode of ventricular standstill. Since the RV catheter was not inserted, CPR was performed until ROSC with sinus rhythm and 1:1 conduction. No ST-T changes were recorded on the surface electrocardiogram, and right coronary artery spasm was excluded by coronary angiography. Four applications were delivered before AFL termination.

Conclusion: Conduction abnormalities are potential complications of PFA in the CTI. PFA occupies a larger tissue area than other catheter ablation modalities do. Maintaining a precise catheter position is especially crucial because of the close proximity of the CTI and His bundle. Respiratory movement may displace the catheter position; a low positive end-expiratory pressure setting on the ventilator may reduce excessive external movement during mapping and ablation. As a precautionary measure against such a detrimental event, an RV catheter may be routinely placed during PFA for AFL for immediate ventricular pacing.

Keywords: Cavotricuspid isthmus, Atrial flutter, Pulsed field ablation, Ventricular standstill, Atrioventricular block



[12INAHRS-CR94]
Atrioventricular Reentrant Tachycardia with Wolf-Parkinson-White Syndrome
“Seeing the Unseen”

Ferel Manuputty¹, Sibro Malisi², Novan Fachrudin³, Hermawan⁴

¹General Practitioner in Moriah Clinic, Tangerang, Indonesia

²General Practitioner in Pertamina Central Hospital, Jakarta, Indonesia

³General Practitioner in Pertamina Central Hospital, Jakarta, Indonesia

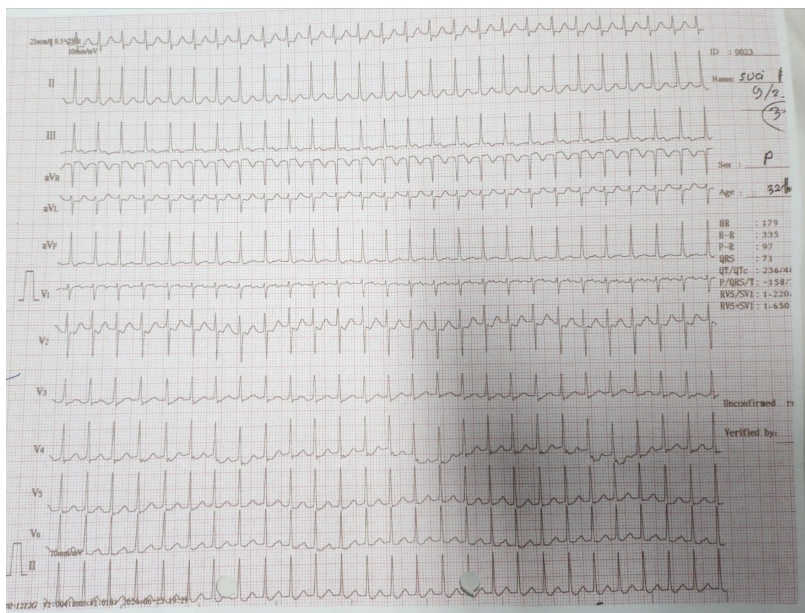
⁴Electrophysiologist consultant in Pertamina Central Hospital, Jakarta, Indonesia

Background: Wolf-Parkinson-White Syndrome (WPW) is an inherited abnormality characterized by abnormal electrical pathways connecting the atria and ventricles. This condition involves additional electrical routes that bypass the AV node. In contrast, atrioventricular re-entrant tachycardia (AVRT) occurs when an additional pathway between the atria and ventricles allows re-entry. We describe the case of a 29-year-old woman who presented to EMD with the chief complaints of sudden palpitations and fatigue. Her ECG on tachycardia showed AVRT, while in sinus rhythm, it showed a WPW pattern.

Case Illustration: A 29-year-old woman presented with sudden palpitations and fatigue. The patient was currently in the 28th week of pregnancy. The patient had a history of hyperthyroidism and was still undergoing treatment. His blood pressure was 90/57 mmHg, and his pulse rate was 180 beats/min. All other vital signs were within the normal range. The First ECG revealed regular narrow complex tachycardia with an RP interval of approximately 120ms. This was interpreted as an orthodromic AVRT. Laboratory results showed no abnormalities. Echocardiography revealed no abnormalities. Patient was treated with digoxin 0.25 mcg and metoprolol 100 mg oral route. After that, the patient admitted that she felt better. The ECG after treatment showed a sinus rhythm of 99 beats/min with a WPW pattern. The patient was scheduled to undergo EP study and catheter ablation after giving birth. WPW pattern consists of three main criteria: 1) Short PR interval, 2) QRS prolongation, and 3) delta wave. The second ECG shows that the accessory pathway is most likely on the left side because of the dominant R wave in V1. This is known as a type-A WPW pattern.

Conclusion: Orthodromic AVRT is a common finding in patients with WPW syndrome. EP study and catheter ablation should be the main treatments for patients with WPW syndrome.

Keywords: WPW syndrome, Orthodromic AVRT, Arrhythmia, Tachyarrhythmia, Accessory pathway.



6.1.

Figure 1. Patient's initial 12-lead ECG showed an orthodromic AVRT pattern.

[12INAHRS-CR95]
Brugada Syndrome in Rural Setting: A Case Series
“Spot the Sign, Change the Ending”

F.Manuputty¹

¹General Practitioner in Penajam Paser Utara Regional Public Hospital, Penajam, Indonesia

Background: Brugada syndrome (BrS) is an arrhythmia disorder characterized by abnormal electrocardiogram (ECG) findings and an increased risk of sudden cardiac death (SCD). We describe two cases of Brugada pattern that presented to our emergency department.

Case Illustration: The first patient was a 61-year-old male who presented with chest pain and palpitations. There was no previous history of any disease, but he admitted to a family history of SCD. His blood pressure was 130/90 mmHg, pulse rate was 150 beats/min, and temperature was 37.8°C. Electrocardiography (ECG) revealed sinus tachycardia with a Brugada pattern in V1 and V2. The laboratory results showed Ur/Cr 99/5,06 mg/dl and AST/ALT 426/207. The patient was treated with oxygen & ISDN 5mg SL. Unfortunately, the family refused to be referred for further evaluation. The patient died several hours after the diagnosis was established. The second patient was a 54-year-old man who presented with fever and chest pain. He admitted that his sister had a history of SCD. His temperature was 39.3 °C, and other vital signs and laboratory results revealed no abnormalities. The ECG revealed a Type I Brugada pattern in V1 and V2. The patient was treated with an antipyretic and ISDN 5 mg SL and then referred to another center for further evaluation.

Conclusion: Clinical presentation and ECG findings are the most important parameters for risk stratification and diagnosis of Brugada syndrome. Fever is a trigger that unmasked Type I BrS.

Keywords: Brugada syndrome, Sudden cardiac death, Arrhythmia

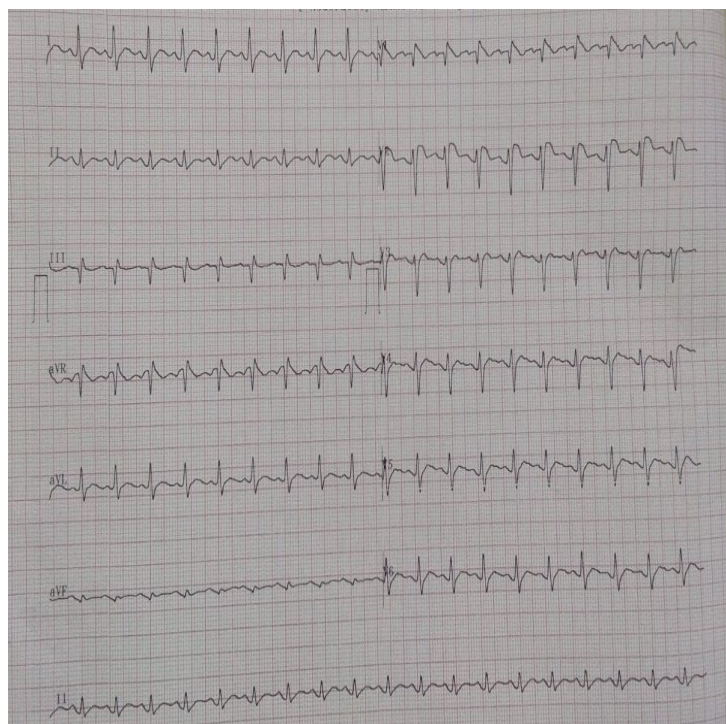


Figure 1. patient's 12-lead ECG showed a Brugada pattern.

[12INAHRS-CR96]

Short-Term and Long-Term Outcomes of Lumenless Lead Extraction in Left Bundle Branch Area Pacing: a Case Series

S. Budiharjo¹, R. N. Muslih¹, G. Karwiky¹, M. Iqbal¹, C. Achmad¹

¹*Department of Cardiology and Vascular Medicine, Faculty of Medicine, University of Padjadjaran, Bandung, Indonesia.*

Introduction: Left bundle branch area pacing (LBBAP) has emerged as a promising physiological pacing modality within the broader scope of conduction-system pacing. Despite its clinical benefits, LBBAP is associated with procedural and post-implantation complications, including lead dislodgement, procedural failure and device-related infections. Notably, lumenless leads used in LBBAP have been associated with infection rates approaching 8.5%, making lead extraction a necessary intervention in selected cases. However, data on the safety and feasibility of extracting these leads at varying dwell times, particularly in the early (<6 months) and late (>2 years) periods, remain limited.

Case Illustration: Two patients with LBBAP leads were diagnosed with cardiac implantable electronic device (CIED) infections, one with an early lead dwell time of four months, and the other with a late dwell time of three years. Both patients received appropriate antibiotic therapy and were subsequently scheduled for lead extraction and device reimplantation. The extraction procedures were performed using simple manual traction without the need for advanced extraction tools. Postprocedural evaluation revealed no evidence of septal perforation, pericardial effusion, or valvular injury. Reimplantation of the permanent pacemakers was successfully performed in both cases. Antibiotic therapy was continued postoperatively, and both patients were discharged in a stable condition.

Conclusion: As LBBAP becomes increasingly utilized in clinical practice, the need for lead management, including extraction, is expected to rise. This case series highlights the feasibility and safety of extracting lumenless LBBAP leads at both early and late dwell times using simple manual traction. No procedural complications were encountered, and the overall success rate was high, without the need for advanced extraction tools. These findings suggest that both short-term and long-term extractions of lumenless LBBAP leads are achievable with low procedural risk, supporting their continued use in appropriate clinical settings.

Keywords: LBBAP, Lead extraction, Lumenless lead, Cardiac implantable electronic device infection, Conduction system pacing

An Orthodox Challenging Bradyarrhythmia Case

[12INAHRS-CR97]
**Successful Single-Ventricular Pacemaker Implantation in an Elderly
with Chronic Left Subclavian Vein Occlusion**

M.R.Felani^{1,2}, Maria L³, Alexander E.T⁴

¹General Cardiologist, Arrhythmia Division, Cardiology and Vascular Department, Mohammad Hoesin General Hospital, Palembang, Indonesia

²General Cardiologist, Hermina Palembang General Hospital, Palembang, Indonesia

³Research Assistant (General Practitioner), Cardiology and Vascular Department, Mohammad Hoesin General Hospital, Palembang, Indonesia

⁴Electrophysiologist - Interventional Cardiologist, Arrhythmia Division, Cardiology and Vascular Department, Mohammad Hoesin General Hospital, Palembang, Indonesia

Introduction: Central venous stenosis and blockage are common issues during transvenous device implantation, especially in patients with previous heart conditions. To address these issues, procedures such as balloon venoplasty or stenting are often needed to facilitate device implantation. Balloon venoplasty is a safe and effective option for managing difficult venous anatomy and assisting lead placement.

Case Illustration: An 81-year-old woman presented with worsening fatigue, severe nausea, and a three-day loss of appetite. Her medical history included stable angina, hypertensive heart disease, and complex, multivessel coronary artery disease. On admission, she was hypotensive and bradycardic (40-45 bpm) in a junctional rhythm and was diagnosed with unstable bradyarrhythmia and severe anemia. Immediate treatment with dopamine infusion and three units of packed red blood cells was initiated; however, her hemodynamic condition did not improve. She was referred for urgent transvenous pacemaker implantation, followed by permanent pacemaker implantation the next day.

Access was attempted via the left axillary vein, but contrast venography revealed a chronic total occlusion (CTO) of the left subclavian vein. A Samurai wire was successfully advanced through the lesion after failed attempts to cross it with the usual J-wire. However, initial balloon dilation using a 2.0x20 mm balloon at 18 atm did not provide adequate access to the SVC. Even after further dilation with a 5.0x15 mm balloon at 12 atm, the pacemaker lead could not pass smoothly through the tightest lesion. Switching from the standard peel-away sheath to a long 7F Medtronic peel-away sheath finally enabled fixation of the right ventricular lead at the right ventricular apex with satisfactory results.

Considering the risk of recurrent subclavian vein stenosis with multivessel coronary disease issues and a history of severe anemia, a low-dose heparin injection (3000 IU) was administered immediately after the procedure, and we continued with single antiplatelet therapy.

Conclusion: This case emphasizes the value of PCI techniques, such as balloon venoplasty, in addressing asymptomatic subclavian vein CTO during urgent pacemaker implantation. Drawing on experience with coronary interventions, these approaches provide a safe and effective solution to overcome venous obstructions, ensuring successful PPM implantation procedures in high-risk patients.

Keywords : Permanent Pacemaker, Subclavian Vein, Chronic Total Occlusion, Balloon Venoplasty

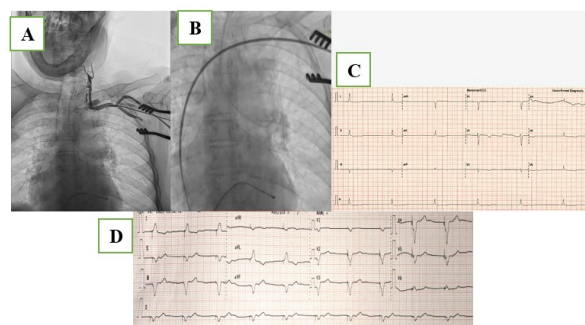


Figure 1. (A) Left Subclavian Vein CTO revealed during PPM implantation procedure; (B) Advancement of a 7F Medtronic peel-away sheath; (C) Baseline ECG showing Bradyarrhythmia with Junctional Rhythm; (D) ECG Post-Successful PPM Implantation.

[12INAHRS-CR98]

Possible Mechanism from Sinus Tachycardia to Atrial Fibrillation after Hemodialysis: A Case Report

S. Raj¹, Y. Safitri²

¹General Practitioner, Columbia Asia Aksara Hospital, Medan, Indonesia

²Cardiologist, Columbia Asia Aksara Hospital, Medan, Indonesia

Background: Atrial Fibrillation (AF) is a chaotic rhythm with a fast atrial rate (350 to 600 discharges/min), and the Ventricular Response can be rapid, normal, or slow, above 100, 60-100, or below 60 beats/min, respectively. Symptoms may vary from asymptomatic to palpitations, fatigue, dyspnea, effort intolerance, and lightheadedness. The risk factors include hypertension, structural heart disease, age, diabetes, and obesity. An electrocardiogram is required as a diagnostic tool, and other tests, such as laboratory testing, chest radiography, and echocardiography, should be considered.

In General, Mechanism of AF is complex. The three main concepts are multiple reentrant wavelets, rapidly discharging autonomic foci, and a single reentrant circuit with fibrillatory conduction. In patients with Chronic Kidney Disease (CKD), the Occurrence of AF is multifaceted. Inflammation, renin-angiotensin-aldosterone system activation, Anemia, Electrolyte abnormalities, and uremia are causative factors. AF can also occur in patients who undergo dialysis. Dialysis itself induces intradialytic AF and is regarded as a risk factor for volume overload, which causes atrial stretch, Left Ventricle Hypertrophy, and neurohumeral alteration or depletion, which causes inhibition of baroreflex, thus activating the sympathetic nervous system and releasing catecholamines. This is related to the setting of the ultrafiltration rate of Dialysis and Electrolyte shift, especially potassium, leading to hypokalemia being suggested as the mechanism.

Antiarrhythmic drugs, anticoagulants, cardioversion, and cardiac ablation should be used as indicated in the management of AF.

Case Illustration: A 39-year-old male experienced dyspnea and palpitation after finishing his hemodialysis. The patient had a history of hypertension, diabetes mellitus type 2, and uncontrolled CKD. The patient was hypertensive, dyspneic, desaturated, and tachycardic, with an irregular heart rate above 150 beats/min. A 12-lead electrocardiogram showed new-onset Atrial Fibrillation with Rapid Ventricular Response. Previously, in the Emergency Room, the patient's electrocardiogram showed Sinus Tachycardia.

The patient was administered bisoprolol orally and digoxin intravenously. Another electrocardiogram was performed after digoxin administration. It converted to sinus tachycardia, and the symptoms resolved. The next day, the patient underwent echocardiography, which revealed HFpEF, CAD, and HHD.

Conclusion: Physicians should closely monitor patients undergoing dialysis, as atrial fibrillation can occur during, after, or independently due to shared risk factors with Chronic Kidney Disease.

Keywords: Atrial fibrillation, Sinus tachycardia, Hemod.

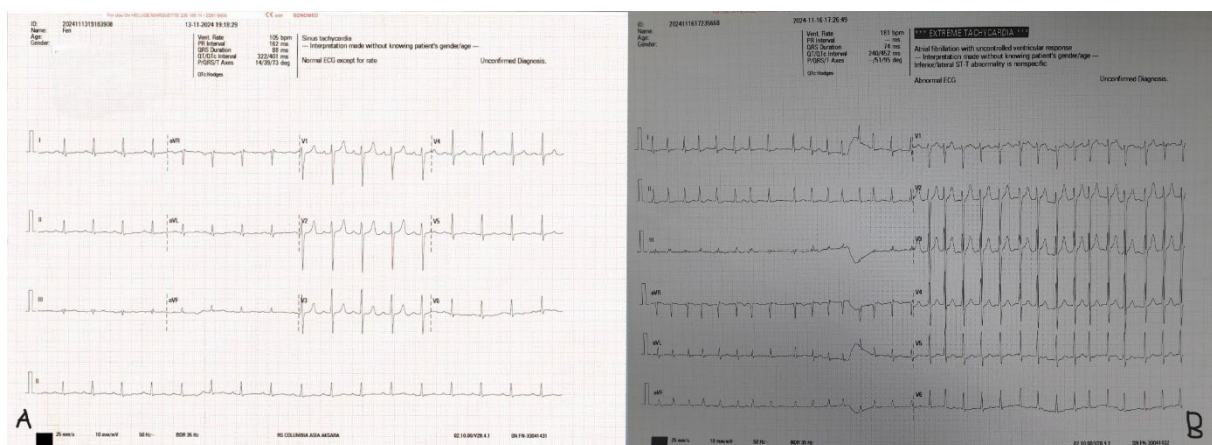


Figure 1. Electrocardiogram of the patient. **A.** Sinus Tachycardia in Emergency Room. **B.** Atrial fibrillation after dialysis.

[12INAHRS-CR99]

Breaking The Rhythm in Silence: An Unusual Case of Total Atrioventricular Block in a Hypertensive Patient Without Symptoms

S. Januarta¹, S Azalea²

¹Public Medical Health District Makasar, Jakarta, Indonesia

²Public Medical Health District Cipayung, Jakarta, Indonesia

Background: Third-degree atrioventricular (AV) block, or complete heart block, occurs when no electrical impulses from the atria reach the ventricles, resulting in AV dissociation and potentially life-threatening bradycardia. It is most commonly observed in the elderly and is often associated with degenerative changes or chronic hypertension. Although typically symptomatic, a completely asymptomatic presentation is rare and may go unnoticed, especially in primary care settings. Early diagnosis using electrocardiography (ECG) is essential to prevent serious complications, such as syncope, ventricular arrhythmias, and sudden cardiac death.

Case Illustration: A 63-year-old woman presented to a primary care clinic with a 3-day history of headaches. She had a long-standing history of grade 2 hypertension, which was managed with amlodipine, although her adherence was inconsistent. The patient denied chest pain, syncope, or shortness of breath. On examination, her blood pressure was 170/90 mmHg and heart rate was 46 bpm. ECG revealed a complete AV block with a junctional escape rhythm. Despite the absence of symptoms, she was referred to a cardiologist and later underwent successful permanent pacemaker implantation.

Conclusion: This case highlights a rare presentation of asymptomatic complete AV block in an elderly patient with uncontrolled hypertension. Although the patient had bradycardia was noted in prior visits, no ECG had been performed until now. Chronic hypertension and age-related fibrosis likely contribute to conduction abnormalities. In resource-limited settings, routine ECG is often overlooked but remains essential, especially in patients with bradycardia or cardiovascular risk factors.

Keywords: complete heart block, asymptomatic, hypertension, bradycardia, ECG, primary care

[12INAHRS-CR100]

When the Silence Breaks: Delayed Symptomatic Arrhythmia Emerging Years After Tetralogy of Fallot Repair — A Case Report

R. Mulawarman¹, D. Y. Hermanto², S. N. Siagian³

¹*Department of Cardiology and Vascular Medicine, National Cardiovascular Centre Harapan Kita, Universitas Indonesia, Indonesia*

²*Division of Arrhythmia and Electrophysiology, Department of Cardiology and Vascular Medicine, National Cardiovascular Centre Harapan Kita, Faculty of Medicine, Universitas Indonesia, 11420 Jakarta, Indonesia*

³*Division of Pediatric Cardiology and Congenital Heart Disease, Department of Cardiology and Vascular Medicine, National Cardiovascular Centre Harapan Kita, Universitas Indonesia, 11420 Jakarta, Indonesia*

Background: Tetralogy of Fallot (TOF) is the most common cyanotic congenital heart disease, and surgical repair dramatically improves survival rates. However, long-term follow-up has revealed that late-onset arrhythmias, particularly ventricular arrhythmias, remain a significant concern. These arrhythmias may present with subtle or atypical symptoms and can be mistakenly attributed to neurological conditions such as epilepsy. Early recognition and differentiation are essential to ensure timely and accurate diagnosis, especially in pediatric patients with congenital heart disease.

Case illustration: A 9-year-old boy with complete TOF repair using a transannular patch at age 2 was referred for recurrent exertional and emotional stress-induced syncope. The events included brief unresponsiveness with tonic posturing and oral frothing but no postictal confusion or tongue biting. Neurologic workup (EEG, brain MRI) was normal; he was diagnosed with epilepsy and treated with valproic acid for over a year without symptom relief.

Cardiac evaluation revealed sinus bradycardia alternating with escape-capture bigeminy. Holter monitoring showed frequent polymorphic premature ventricular contractions (PVCs, 24% burden), multiple runs of non-sustained VT (NSVT), and chronotropic incompetence. Some beats initially classified as PVCs may represent PACs with aberrancy, and a prolonged QTc was noted in junctional beats, although not consistently. Echocardiography showed preserved biventricular function and moderate pulmonary regurgitation without residual defects. No sustained VT was documented; however, arrhythmia remained the most plausible etiology of the syncope. One prolonged episode (>1 hour) likely reflected post-ictal or autonomic instability rather than sustained arrhythmia.

Verapamil (120 mg/day) was initiated, resulting in complete resolution of the symptoms. The antiepileptic drugs were withdrawn. Electrophysiology study (EPS) and follow-up Holter are scheduled to confirm arrhythmia substrate and evaluate the need for ICD or ablation.

Conclusion: This case highlights the diagnostic challenge of distinguishing convulsive syncope from epilepsy in pediatric patients who are TOF survivors. Despite the absence of sustained VT, the high PVC burden, NSVT, and bradyarrhythmia suggested a significant arrhythmic substrate, likely due to surgical scarring and RV remodeling. Careful clinical history, Holter analysis, and EPS are essential for guiding management and preventing misdiagnosis or sudden cardiac death in this vulnerable population.

Keywords: Tetralogy of Fallot, pediatric arrhythmia, convulsive syncope, ventricular tachycardia, electrophysiological study

[12INAHRS-CR101]

Distinguishing Supraventricular Tachycardia with Aberrancy and Ventricular Tachycardia: a Case Report and Diagnostic Approach in Emergency Settings

K. L. Wewang¹, A. J. N. Haris¹, A. Surya¹

¹*Pelamonia Hospital, Makassar, Indonesia*

Background: Wide QRS complex tachycardia (WCT) is most commonly associated with ventricular tachycardia (VT). However, in certain cases, WCT may also result from supraventricular tachycardia (SVT), particularly in patients with preexisting bundle branch block. Accurate differentiation between the two is critical because of differences in management strategies. Moreover, diagnosis remains a significant clinical challenge, particularly in emergency settings.

Case Illustration: A 72-year-old man presented to the emergency department with complaints of palpitations and dyspnea that were not relieved by rest. The symptoms were accompanied by nausea, diaphoresis, and coughing but without vomiting or chest pain. The patient had a medical history of heart failure, atrial fibrillation, and bundle-branch block. On examination, the patient was hemodynamically unstable. Electrocardiography (ECG) revealed a regular wide complex tachycardia. A diagnostic approach was undertaken using the Basel algorithm, and the criteria for SVT with aberrancy were met. As the patient declined to undergo synchronized cardioversion, intravenous amiodarone was administered. Post-therapy, the ECG demonstrated atrial fibrillation with a bundle branch block pattern.

Conclusion: The Basel algorithm may offer a practical advantage in differentiating WCTs in emergency settings.

Keywords: supraventricular tachycardia, ventricular tachycardia, wide QRS complex tachycardia, diagnostic algorithm

[12INAHRS-CR102]

From Plaque to Precision: The Value of Intravascular Ultrasound-Guided Intervention in ST-Segment Elevation Myocardial Infarction with Calcified Coronary Arteries

G. F. Nahan¹, I. G. A. B. K. Jayantika¹

¹*Department of Cardiology, Bali Mandara Regional General Hospital, Denpasar, Indonesia*

Background: ST-segment elevation myocardial infarction (STEMI) with calcified coronary arteries is highly challenging for percutaneous coronary intervention (PCI), which leads to common stent under-expansion, malapposition, and a high probability of adverse outcomes. Angiography alone may underestimate the lesion severity and calcium burden, potentially leading to suboptimal outcomes. Intravascular ultrasound (IVUS) provides high-resolution cross-sectional images of the arterial lumen that enable accurate lesion characterization, optimal stent sizing, and confirmation of adequate expansion (which are important factors in calcified coronary disease).

Case Illustration: A 46-year-old male patient with Anterior STEMI received fibrinolytic therapy using streptokinase and achieved successful reperfusion. Coronary angiography post-fibrinolysis revealed 70-90% diffuse stenosis in the culprit lesion, with calcification in the mid-to-proximal LAD and TIMI 3 flow. Delayed stent deployment was adopted to avoid the no-reflow phenomenon. Elective IVUS-guided PCI was performed. Pre-stent IVUS imaging showed a fibrocalcified plaque at 90-180 degrees, a lesion length of 28 mm, and a distal reference of 3.5 mm. Stenting was performed using a DES Promus 3.0 mm x 32 mm at mid to proximal LAD, a deployed stent at 12 atm for 11s. Post-dilatation was performed using NC Emerge 3.5 × 15 mm, inflated three times at 12-20 atm for 8-10s. Post-stenting, IVUS was performed, which showed no medial dissection, a well-apposed stent, and no malposition. Angiography revealed TIMI 3 flow in the LAD.

Conclusion: IVUS-guided PCI enhances STEMI management in calcified lesions by enabling precise stent optimization, reducing complications, and improving outcomes, supporting its adoption as a standard tool for complex lesions.

Keywords: IVUS-guided PCI, Calcified plaque, stent optimization, no-reflow prevention.

[12INAHRS-CR103]

Digoxin versus Beta-Blockers in Atrial Fibrillation: A Meta-Analysis of Mortality, Hospitalization, and Rate Control Outcomes

M. W. R. Ramadhan¹, A. I. S. Harnoko², A. Y. A. Binarso³, U. Bahrudin³

¹Faculty of Medicine, Universitas Pembangunan Nasional "Veteran" Jakarta, Jakarta, Indonesia

²Faculty of Medicine, Universitas Diponegoro, Semarang, Indonesia

³Department of Cardiology and Vascular Medicine, Universitas Diponegoro, Semarang, Indonesia

Background and aims: The comparative effectiveness of digoxin and beta-blockers in atrial fibrillation (AF) remains unclear. Digoxin is widely used, particularly in resource-limited settings, but is associated with increased mortality, as shown in observational studies. This meta-analysis compared the effects of these drugs on mortality, hospitalization, and rate control.

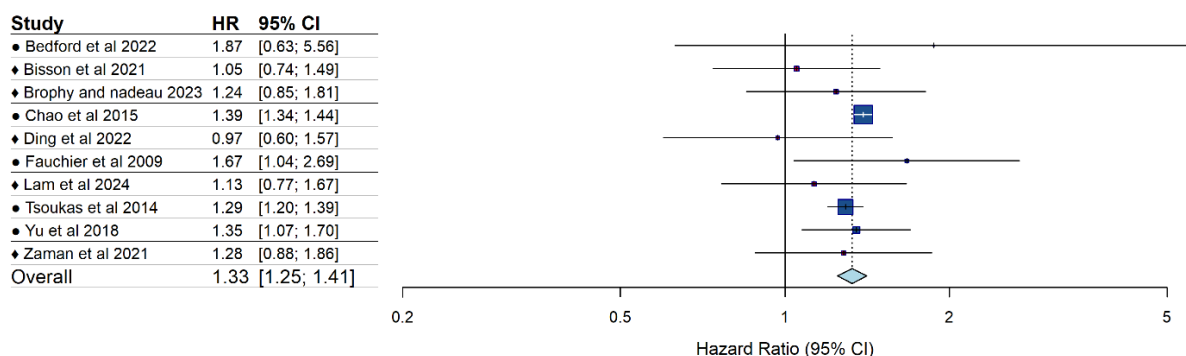
Materials and methods: We conducted a PRISMA-compliant meta-analysis (PROSPERO: CRD420251030670) of randomized and observational studies without date or language restrictions. The databases searched included MEDLINE, CENTRAL, CINAHL, Scopus, and ClinicalTrials.gov. The primary outcomes were all-cause mortality and hospitalization, and rate control was a secondary outcome. The risk of bias was assessed using the ROBINS-I and ROB 2.0 tools. Evidence certainty was rated using the GRADE.

Results: Nineteen studies (n = 1,060,400) were included in the analysis. Pooled data from 10 observational studies (n = 120,189) showed that digoxin was associated with a 33% higher mortality risk (HR 1.33; 95% CI 1.25–1.41; p < 0.001), with remarkably low heterogeneity (I² = 6.5%). Direct comparisons were not statistically significant (HR 1.14 [95% CI 0.98–1.33]; p = 0.093). The leave-one-out sensitivity analysis confirmed the robustness of the results across all studies. The risk of hospitalization was similar (HR 1.03; 95% CI 0.66–1.59). Beta-blockers consistently achieve superior rate control across trials and registries. An advanced publication bias assessment showed a minimal impact on the findings. For example, in the AFFIRM registry subset, 68% of patients on beta-blockers achieved rate targets compared with 58% on digoxin. Evidence certainty was rated low due to the study design and indirectness.

Conclusion: Digoxin is associated with a higher mortality risk than beta-blockers in patients with AF based on observational data, although direct comparisons remain inconclusive. Beta-blockers demonstrated superior rate control and aligned with the ESC 2024 recommendations as first-line agents. High-quality trials directly comparing these drugs are urgently required.

Keywords: atrial fibrillation, digoxin, beta-blockers, mortality, meta-analysis

Digoxin vs Beta-blockers for All-Cause Mortality in Atrial Fibrillation



◆ Direct comparison ● Indirect comparison

Figure 1. Forest Plot: Digoxin vs. beta-blocker mortality meta-analysis.

[12INAHRS-CR104]

**Resolving Diagnostic Uncertainty in Circulatory Shock: The Pivotal Role of Bedside Echocardiography –
A Case Report**

G. F. Nahan¹, S. A. N. Y. Sutarmini¹

¹Department of Cardiology, Bali Mandara Regional General Hospital, Denpasar, Indonesia

Background: Circulatory shock requires rapid hemodynamic characterization to guide treatment; however, overlapping phenotypes (septic or cardiogenic) commonly complicate diagnosis in 30-40% of cases. Bedside echocardiography has emerged as a critical tool for differentiating complex shock states, offering real-time, noninvasive assessment of cardiac function, volume status, and vascular resistance, aligning with ESC guidelines that recommend ultrasound as the first-line evaluation.

Case Illustration: A 57-year-old woman with sepsis was diagnosed with suspected NSTEMI and cardiogenic shock due to elevated hs-cTnI levels (7501.2 ng/L). Bedside echocardiography revealed an LVEF of 43.9% with anteroseptal akinesis (type 2 MI pattern). LVOT VTI was 18.5 cm, SV was 47 mL, SVR was 698-787 dynes/cm³, and eRAP 8-15 mmHg. These findings identified septic shock with secondary sepsis-associated myocardial injury, where hemodynamic derangement was 70% vasoplegic and 30% ischemic.

Conclusion: This case underscores the pivotal role of bedside echocardiography in diagnosing and treating shock. Revealing sepsis-masked cardiac injury and quantifying hemodynamic contributions enables precise resuscitation while reducing the reliance on invasive monitoring.

Keywords: Circulatory shock, bedside echocardiography, hemodynamic phenotyping

[12INAHRS-CR105]

Long QT Syndrome and Implantable Cardioverter-Defibrillator in a 5-Year-Old with Epilepsy Following Cardiac Arrest: A Rare Case Report

F. A. Hanarko¹, R. N. Rosyadi²

¹Faculty of Medicine, Universitas Atma Jaya, Jakarta, Indonesia

²Department of Cardiovascular Medicine Dr. Ramelan Naval Hospital, Surabaya, Indonesia

Background: Long QT syndrome (LQTS) is a rare and potentially life-threatening condition of the heart's electrical system, characterized by a prolonged QT interval on electrocardiogram (ECG) and an increased risk of arrhythmias, such as torsade pointes and sudden cardiac death. LQTS in children post-cardiac arrest is unusual, and when complicated by epilepsy, it presents a unique and challenging diagnostic and therapeutic dilemma.

Case Illustration: A 5-year-old boy developed focal epilepsy in September 2023. His first seizure occurred in the morning after he was awakened by the sound of thunder, causing stiffness on one side of his body, followed by rapid recovery. In December 2023, the patient experienced a syncopal episode. Epilepsy was confirmed in January 2024 using EEG. Initial treatment with valproic acid was followed by oxcarbazepine and levetiracetam, effectively controlling the seizures. In October 2024, the child experienced a prolonged seizure, collapsed, and became pulseless. CPR was performed. ECG revealed VT, which was terminated by DC shock. He was intubated and admitted to the ICU. The patient experienced multiple episodes of VT and VF. ECG showed a prolonged corrected QT interval of 480 ms, suggestive of LQTS.

CVC was performed. Laboratory results indicated mild anemia (hemoglobin 10.1 g/dL), leukocytosis ($19.9 \times 10^3/\mu\text{L}$), thrombocytosis ($596 \times 10^3/\mu\text{L}$), elevated procalcitonin (2.33 ng/mL), mild renal impairment (creatinine 0.64 mg/dL, eGFR 77), and severe mixed acidosis (pH 6.99). A urinary tract infection was diagnosed. Electrolyte levels and thyroid function were normal. Brain computed tomography (CT) revealed no intracranial pathology. Chest radiography revealed bronchopneumonia. Echocardiography revealed MR and TR with an EF of 74%.

An implantable cardioverter-defibrillator (ICD) was inserted. During a 10-day stay in the PICU, he was treated with mechanical ventilation, intravenous lidocaine, oral atenolol, antiepileptics, and antibiotics. No additional seizures were observed. Follow-up ECG showed sinus rhythm at 80 bpm.

Conclusion: This case highlights the importance of LQTS in pediatric patients with unexplained cardiac arrest. Seizures, particularly in patients with LQTS, may precipitate life-threatening arrhythmias, and a multidisciplinary team approach and ICD implantation are crucial. Further research is needed to optimize management strategies for pediatric populations with both LQTS and epilepsy to prevent sudden death.

Keywords: Long QT Syndrome, Epilepsy, Implantable Cardioverter Defibrillator, Cardiac Arrest, Pediatric

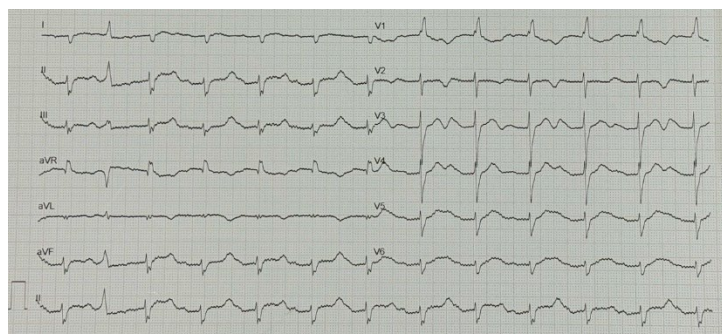


Figure 1. A 12-lead ECG showed a prolonged corrected QT interval, suggestive of LQTS.

[12INAHRS-CR106]

Diagnostic Pitfalls of Electrocardiography in a Dextrocardia Patient with Anterior Myocardial Infarction

M. Winarti¹, D.Y. Kurniawan, H. Hutabarat, P. Ardhianto¹, I. Uddin¹

¹Department of Cardiology and Vascular Medicine, Faculty of Medicine Universitas Diponegoro, Kariadi Hospital, Semarang, Indonesia

Background: Dextrocardia occurs in approximately 1 in 12,000 births. Dextrocardia poses a significant challenge in the electrocardiographic (ECG) diagnosis of myocardial infarction. Anterior myocardial infarction in a patient with dextrocardia is an extremely rare finding, with <100 cases reported worldwide.

Case Illustration: A 52-year-old man with a history of a non-revascularized myocardial infarction two months earlier presented with stable angina pectoris that occurred during physical activity, particularly on the right side and during heavy exertion. The patient was scheduled for percutaneous coronary intervention. On physical examination, the puctum maximum was on the right side of the thorax. A standard 12-lead ECG showed right axis deviation, negative P waves in lead I, positive P waves in lead aVR, QS complex in anterior extensive leads, ST-segmentt elevation (STE) in lead V1, and T-wave inversion in V1. However, isolated T-wave inversion in V1 is insufficient for diagnosing myocardial infarction due to the absence of contiguous lead involvement. The atypical findings in leads I and aVR raised suspicion of dextrocardia or cardiac dextroposition. Laboratory test results were normal. Due to the ambiguous findings, a right-sided ECG was performed, revealing normoaxis, positive P waves in leads I and II, negative P waves in lead aVR, slight STE in leads V1-V2, and prominent diffuse T wave inversion in leads V1-V6, indicating an extensive anterior myocardial infarction. Chest radiography and echocardiography confirmed the diagnosis of dextrocardia. The patient then underwent percutaneous coronary intervention on the left anterior descending artery (LAD) with a successful outcome.

Conclusion: Diagnosing myocardial infarction on ECG in patients with dextrocardia is challenging. This condition may be underestimated or misdiagnosed unless dextrocardia is promptly identified and the chest leads are repositioned accordingly. Both limb and precordial leads should be reversed to reveal all ECG changes that can show the extent of myocardial infarction in patients with dextrocardia.

Keywords: Dextrocardia, Electrocardiography, Myocardial Infarct

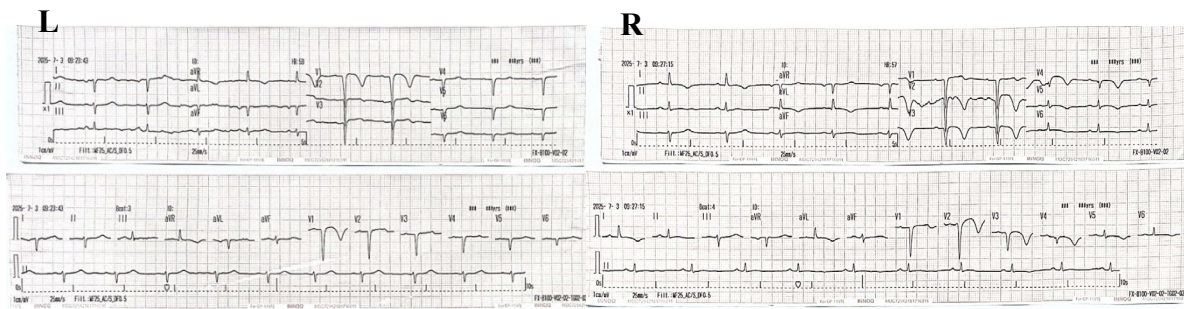


Figure 1. Comparison of left-sided and right-sided ECG in a dextrocardiac patient.

[12INAHRS-CR107]
**Pacing and Defibrillation in Limited Resources,
Physiological Pacing with A DF-1 Single Chamber ICD, a Case Report**

S. Hidayatullah¹, G. Karwiky¹, M. Iqbal¹, C. Achmad¹

¹Department of Cardiology and Vascular Medicine, Faculty of Medicine, University of Padjadjaran, Bandung, Indonesia.

Background: In patients with bradyarrhythmias and heart failure with reduced ejection fraction (HFrEF), device-based therapies, such as physiological pacing combined with defibrillator support, can improve both survival and functional capacity. In resource-limited settings, the use of a single-chamber ICD with a DF-1 connector may be a cost-effective alternative. We report a case of physiological pacing for bradycardia in a patient with HFrEF, delivered via a DF-1 single-chamber ICD system.

Case Presentation: A 60-year-old man presented with complete heart block and ischemic cardiomyopathy, with a severely reduced left ventricular ejection fraction (LVEF) of 22%. Due to significant comorbidities and limited resources, he was selected for implantation of a DF-1 single-chamber implantable cardioverter-defibrillator (ICD). Precise left bundle branch area pacing (LBBAP) mapping was performed using fluoroscopic landmarks and intracardiac electrograms to identify the optimal pacing site, accounting for the patient's complex anatomy and enlarged right atrium. The DF-1 single-chamber ICD was configured as follows: the defibrillation DF-1 pin was connected to the DF-1 port, the LBBAP lead was connected to the right ventricular (RV) port, and the IS-1 pin of the defibrillation lead was capped. Post-implantation parameters were favorable: LBBAP pacing threshold was 0.5 V at 0.4 ms, unipolar impedance was 580 Ω , and the sensed R-wave amplitude was 7 mV.

Conclusion: This case underscores the feasibility and clinical benefits of implementing physiological pacing using a DF-1 single-chamber ICD in patients with complete heart block and ischemic cardiomyopathy, particularly in resource-limited settings. The integration of precise conduction system mapping and individualized pacing strategies can substantially improve patient outcomes.

Keywords: Physiological pacing with DF1, Ischemic cardiomyopathy, severely reduced LVEF

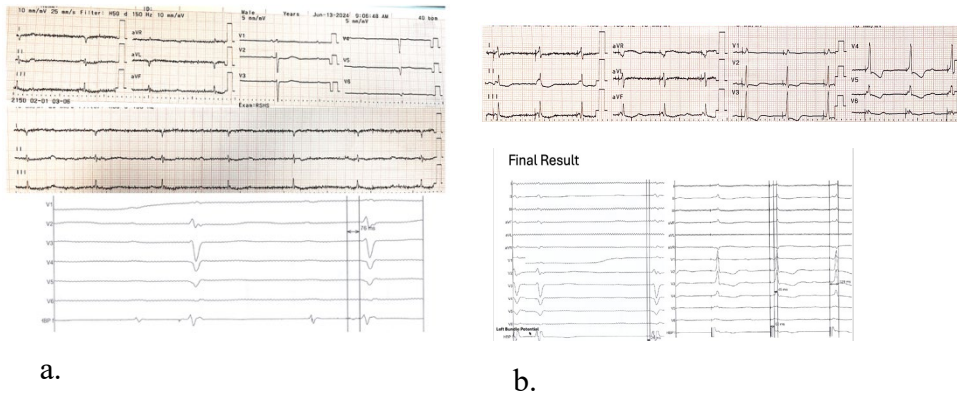


Figure 1. (a) Before ICD implantation, (b) After ICD implantation.

[12INAHRS-CR108]

Postpartum Supraventricular Tachycardia: Coincidence or Drug-Induced Unmasking?

A. M. Masyhudi¹, S.I. Sitompul¹, Y. Galenta¹, A. Ferly¹, Manalu¹

¹Department of Cardiology and Vascular Medicine, Dr. Doris Sylvanus General Hospital, Palangka Raya, Indonesia.

Background: Supraventricular tachycardia (SVT) is a common arrhythmic syndrome characterized by reentrant circuits above the heart ventricles. Atrioventricular nodal reentrant tachycardia (AVNRT) is the most prevalent subtype of SVT. Clinical manifestations may remain silent until triggered by autonomic or hormonal shifts. The postpartum period is a vulnerable time during which these factors may converge, resulting in the clinical manifestation of SVT in predisposed patients.

Case Illustration: A 25-year-old primigravida underwent an uncomplicated caesarean section under epidural anesthesia. Two hours postoperatively, the patient developed sudden, sustained palpitations with tachycardia, while blood pressure and oxygen saturation remained stable. A 12-lead ECG revealed regular narrow-complex tachycardia without visible P waves, which was consistent with SVT. AVNRT was suspected based on the ECG morphology. The arrhythmia resolved following the administration of intravenous digoxin (0.5 mg). Autonomic imbalance related to epidural anesthesia likely played a central role, possibly by increasing AV nodal excitability and facilitating reentrant circuits in predisposed individuals. Additional contributing factors may include pharmacologic exposures such as oxytocin, postoperative sympathetic activation, and hormonal shifts—all of which can enhance adrenergic tone and lower the arrhythmic threshold. Collectively, these factors may accelerate AV nodal conduction and unmask latent pathways, resulting in clinical AVNRT development. Although not a first-line therapy, intravenous digoxin successfully restored the sinus rhythm.

Conclusion: This case illustrates an episode of supraventricular tachycardia occurring shortly after caesarean delivery, likely triggered by autonomic imbalance related to epidural anesthesia, with additional contributions from pharmacologic exposures, postoperative sympathetic activation, and hormonal shifts. ECG findings were suggestive of AVNRT, and successful rhythm control was achieved with intravenous digoxin. Electrophysiological evaluation is recommended for definitive confirmation and long-term management.

Keywords: Supraventricular tachycardia, Atrioventricular nodal reentrant tachycardia

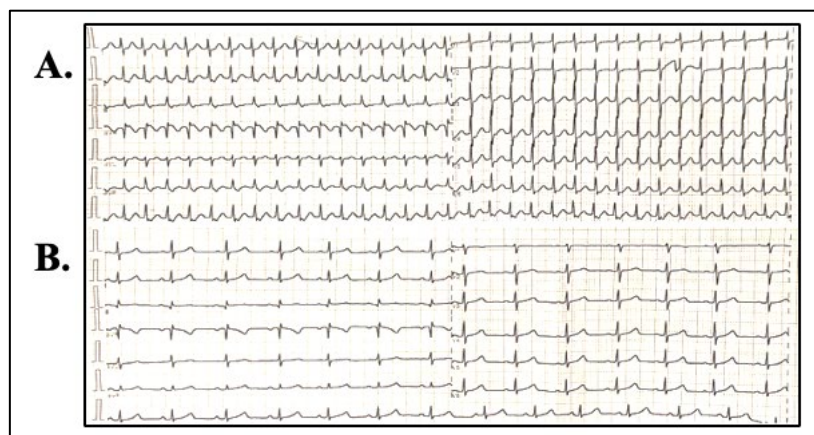


Figure 1. (A.) ECG showing supraventricular tachycardia. (B.) Follow-up ECG demonstrating normal sinus rhythm following pharmacologic resolution of supraventricular tachycardia.

[12INAHRS-CR109]
**Cardioneural Ablation as a Pacemaker-Sparing Strategy for Severe Cardioinhibitory Vasovagal
Syncope: A Case Report**

A.P.Wikananda¹, A.Hussin²

¹Saiful Anwar General Hospital Malang, Faculty of Medicine, Universitas Brawijaya, Malang

²Cardiology Department, National Heart Institute, Kuala Lumpur, Malaysia

Background: Cardioinhibitory vasovagal syncope (VVS) is a common cause of recurrent loss of consciousness due to an exaggerated autonomic reflex, leading to severe bradycardia or asystole. Although often benign, frequent episodes can be debilitating, significantly impairing the quality of life and posing a risk of injury. For patients who are refractory to conservative measures, permanent pacemaker implantation has been a traditional therapy, although it is not without limitations, particularly in younger, active individuals. Cardioneural ablation (CNA), a novel technique that modulates the autonomic nervous system by targeting ganglionated plexi, has emerged as a promising alternative.

Case Illustration: We present the case of a 42-year-old man with a multi-year history of recurrent, unpredictable syncope. The episodes occurred without prodrome, leading to multiple major injuries and significant lifestyle limitations, including an inability to drive or work confidently. A comprehensive investigation, including a positive head-up tilt table test, confirmed the diagnosis of severe cardioinhibitory vasovagal syncope with prolonged periods of asystole. Owing to the frequency and severity of his symptoms and his desire to avoid a permanent pacemaker, the patient was offered cardioneural ablation.

Management and Outcome: The patient underwent a successful and uncomplicated cardioneural ablation. Key ganglionated plexi in the right and left atria were targeted using an anatomical and electrogram-guided approach, resulting in a significant reduction in the vagal response upon testing. At the 6-month follow-up, the patient reported a complete cessation of syncopal and pre-syncopal episodes. He was able to resume all previous activities, including driving, and reported a profound improvement in his overall quality of life. Postprocedural monitoring confirmed the absence of significant bradyarrhythmias, and the need for a pacemaker was successfully averted.

Conclusion: This case demonstrates that cardioneural ablation can be a safe and highly effective therapeutic option for selected patients with severe refractory cardioinhibitory vasovagal syncope. For this 42-year-old patient, the procedure eliminated debilitating symptoms, restored his quality of life, and obviated the need for a lifelong cardiac, implantable electronic device. Further research and long-term follow-up are warranted; however, CNA represents a significant advancement in the management of cardioinhibitory VVS.

Keywords: Cardioneural Ablation, Cardioinhibitory Vasovagal Syncope

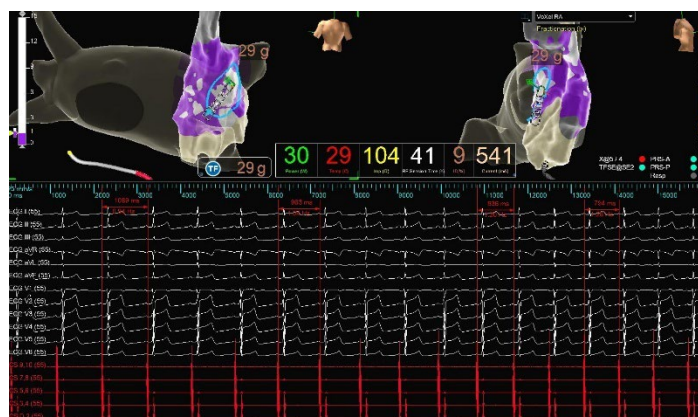


Figure 1. Radiofrequency ablation (RFA) of the right superior ganglionated plexus (RSGP) in a patient with cardioinhibitory vasovagal syncope led to an immediate increase in heart rate, as evidenced by mapping data.

[12INAHRS-CR110]

Sinus Arrest with Ventricular Escape Rhythm and Cardiogenic Shock due to Mild Hyperkalemia in Chronic Kidney Disease: A Case Report

P. P. Siahaan¹, A. H. Fahmy¹, S. R Arjuna¹, R. A. Nugraha^{1,2}

¹*Adi Husada Kapasari Hospital, Surabaya, Indonesia*

²*Department of Cardiology and Vascular Medicine, Faculty of Medicine, Universitas Airlangga, Surabaya, Indonesia*

Background: Bradyarrhythmia is often encountered in the emergency room for diverse reasons, particularly metabolic causes that may present with various clinical manifestations. One of these is life-threatening cardiogenic shock, which is characterized by impaired cardiac output and end-organ hypoperfusion. We highlight the importance of prompt hyperkalemia correction and arrhythmia therapy in the emergency room for managing such conditions.

Case Illustration: A 56-year-old woman presented to our emergency department with a chief complaint of vomiting.

She experienced profuse vomiting throughout the day and vomited four times in the emergency room. She also complained of a swollen leg since last month. Her comorbidities included diabetes mellitus and hypertension, and she was currently consuming 20 mg of furosemide and 5 mg of amlodipine throughout the day.

The patient's general condition was *compos mentis* and appeared weak. The vital signs were as follows: blood pressure, 57/47 mmHg; heart rate, 49 beats per minute (bpm); and oxygen saturation, 88%. Electrocardiography (ECG) showed sinus arrest with a ventricular escape rhythm. Patients were given oxygen supplementation at a flow of six liters per minute (lpm) and were placed in the shock position and therapy with dopamine of five mcg/kg/minute and eight mg of ondansetron injection. The complete blood count and electrolyte values obtained showed hyperglycemia (254 mg/dL), thrombocytopenia, anemia, hyperkalemia, and a high level of blood urea nitrogen. The patients were then administered a single ampoule bolus injection of calcium gluconate within 5 min. The patients were done, and then re-examined. The patient continued to complain of vomiting. However, the vital signs indicated changes, with a blood pressure of 142/60 mmHg and a heart rate of 62 bpm on dopamine of five mcg/kg/minute. The ECG indicated 1st degree AV block and anterolateral ischemia.

Conclusion: Initial hyperkalemia management may alter the electrocardiogram in patients with hyperkalemia and chronic kidney disease. Changes in the electrocardiogram may contribute to cardiovascular outcomes.

Keywords: Bradyarrhythmia, shock, cardiogenic, hyperkalemia

[12INAHRS-CR111]

Exercise-Induced Reversal of Right Bundle Branch Block: A Dynamic and Unique Observation

A. A. Lukito¹, A. Lawijaya²

¹Cardiologist, Siloam Hospital Lippo Village, Banten, Indonesia

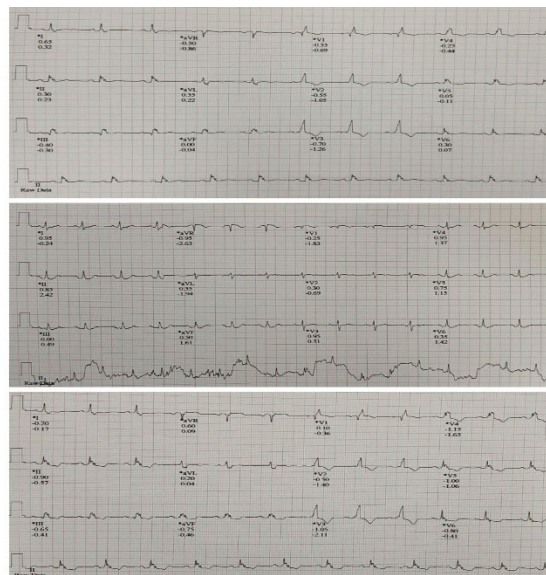
²General practitioner, Siloam Hospital Lippo Village, Banten, Indonesia

Background: Right bundle branch block (RBBB) is a common electrocardiographic finding that is often associated with structural heart disease. In patients with known coronary artery disease (CAD), persistent RBBB raises concerns regarding conduction system abnormalities. While exercise-induced RBBB is well recognized, exercise-induced resolution of RBBB is rare and has been studied the least.

Case Illustration: A 75-year-old man with a history of CAD and baseline RBBB on resting electrocardiogram (ECG) underwent a treadmill exercise stress test using the standard Bruce protocol. Echocardiography revealed no significant abnormalities. During peak exercise (stage 2), the RBBB resolved, and the ECG showed a narrow QRS complex with sinus rhythm. RBBB reappeared after peak exercise and persisted during recovery. No symptoms appeared during or after the test, and no arrhythmias or significant ST segment changes were noted. The transient disappearance of RBBB during exercise suggests a dynamic alteration in the conduction system of the heart. Proposed mechanisms include a bradycardia-dependent block, increased sympathetic tone improving conduction, or changes in left bundle branch conduction masking RBBB. The patient's asymptomatic status suggests that this was a benign phenomenon.

Conclusion: This case suggests that transient resolution of RBBB during exercise may be benign in certain patients. However, further studies are required to determine the direct cause of this phenomenon.

Keywords: RBBB, Exercise-induced, Dynamic changes.



Top : Resting phase of exercise stress test : RBBB pattern of QRS complex.
HR 63 bpm.

Middle : Peak of exercise stress test : Narrow QRS complex. No RBBB
pattern. HR 85 bpm

Bottom : Recovery state of exercise stress test : RBBB pattern reappears
and persists. HR 72 bpm.

[12INAHRS-CR112]

Pediatric Myocarditis Presenting with Mobitz II AV Block: Recovery Without Cardiac Pacing

N. N. Hidajat¹, D. Listiana¹, D. Rostiati¹

¹Cardiology Département Bandung City Regional General Hospital, Bandung, Indonesia

Background: Atrioventricular(AV) block is a rare conduction disorder in children. One common cause is myocarditis, often due to viral infection. Pediatric myocarditis can lead to fatal complications, such as myocardial failure and arrhythmias. Mobitz type II AV block, marked by sudden dropped beats without progressive PR interval prolongation, is considered more severe. Temporary pacemaker (TPM) placement is often considered in such cases; however, not all patients are willing to undergo this procedure. While supportive care remains the cornerstone of treatment, immunotherapy, such as intravenous immunoglobulin (IVIG) and corticosteroid therapy, may be used. Although evidence supporting corticosteroid use is limited, it is more accessible in low-resource settings than other immunosuppressants. In this case, a child with myocarditis and Mobitz type II AV block showed clinical and conduction enhancement following immunotherapy and supportive treatment.

Case Illustration: A 10-year-old boy presented to the emergency room with two weeks of high-grade intermittent fever, vomiting, and signs of poor perfusion. Upon examination, the patient exhibited decreased consciousness and hypotension. The initial ECG showed a first-degree AV block. Echocardiography revealed no structural cardiac abnormalities and a normal LVEF(55%). He was treated with intravenous fluids, ceftriaxone, dexamethasone, and electrolyte correction. He developed bradycardia(HR 40-50 bpm) on day two, and ECG revealed Mobitz type II AV block with PVC. Temporary pacing was suggested, but the patient's family refused. Dopamine and epinephrine were used for conservative management. Over the next several days, the clinical status improved, and the vasopressors were tapered. On the seventh day, the patient's ECG showed sinus rhythm, and the patient was discharged in a stable condition. This case illustrates that a child's suspected myocarditis led to a reversible Mobitz II AV Block that was effectively treated without cardiac pacing.

Conclusion: Mobitz type II AV block in pediatric myocarditis is rare but potentially life threatening. With timely supportive care and close monitoring, it may be reversible without the need for pacing. Early recognition is crucial for guiding appropriate treatment.

Keywords: AV Block, pediatric myocarditis, conservative management

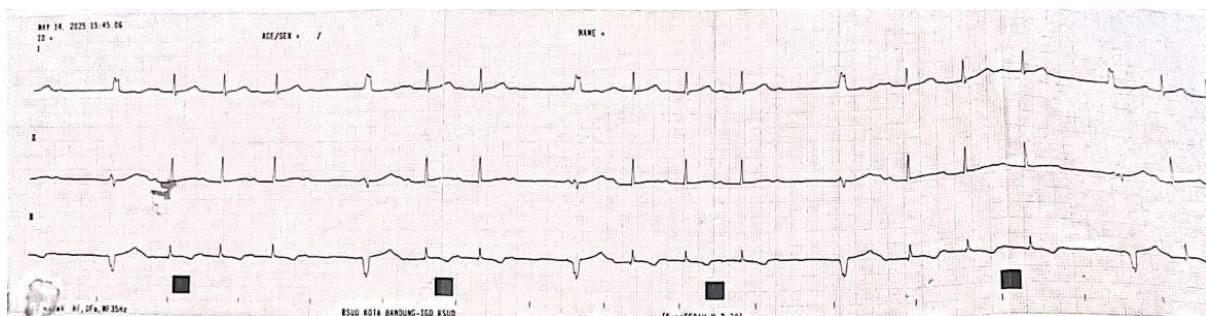


Figure 1. ECG day 2.

[12INAHRS-CR113]

Fever-Induced Brugada Phenocopy in a Young Man— a Case Report

AA Modjo¹, R Herdyanto², S Atmojo³

¹General Practitioner, Dr. R. Sosodoro Djatikoesoemo General Hospital, Bojonegoro, East Java, Indonesia

²Department of Cardiology and Vascular Medicine, Dr. R. Sosodoro Djatikoesoemo General Hospital, Bojonegoro, East Java, Indonesia

³Department of Cardiology and Vascular Medicine, Aisyiyah Bojonegoro Hospital, Bojonegoro, East Java, Indonesia

Background: Brugada Syndrome (BrS) is a rare genetic disease with a specific abnormal pattern on electrocardiography (ECG) that has a high tendency to develop life-threatening arrhythmias that can precipitate sudden cardiac death (SCD). Brugada phenocopy (BrP) presents transient, reversible mimicking of Brugada ECG patterns due to various reversible causes, including fever, and is expected to resolve completely after the correction of the underlying condition.

Case Description: A 39-year-old man presented to the Emergency Room (ER) with complaints of fever, cough, cold, sweating, and worsening dull-aching chest pain for 3 days prior. He had no relevant history of cardiac disease or other comorbidities. Vital signs at the ER were as follows: Glasgow Coma Scale (GCS) 4/5/6, Blood Pressure (BP) 114/76, Heart Rate (HR) 110 bpm, temperature (T) 39.8 °C, Respiratory Rate (RR) 20x/min, 99% saturation with normal heart sound. Initial ECG (Figure 1) revealed a type 2 Brugada pattern with saddleback ST-segment elevation ≥ 2 mm in V2-V3. Laboratory examination revealed leukocytosis (14.000/mm³). No abnormalities were found on chest radiography. Echocardiography showed good right (RV) and left (LV) ventricular function. The patient was diagnosed with Brugada phenocopy and admitted to the high-care unit (HCU) for continuous monitoring. The patient was started on broad-spectrum antibiotics, antipyretics, and an oral phosphodiesterase inhibitor to prevent further malignant arrhythmia. On the third day, a repeat ECG showed that the Brugada pattern had resolved.

Conclusion: Clinicians should be aware of the circumstances that can induce BrP, a reversible and benign condition with favorable outcomes in most cases. However, a misleading diagnosis of BrS may lead to unnecessary diagnostic procedures and false management plans, adversely affecting patient outcomes.

Keywords: Brugada Syndrome, Brugada Phenocopy, Fever, Electrocardiography, Malignant Arrhythmia.

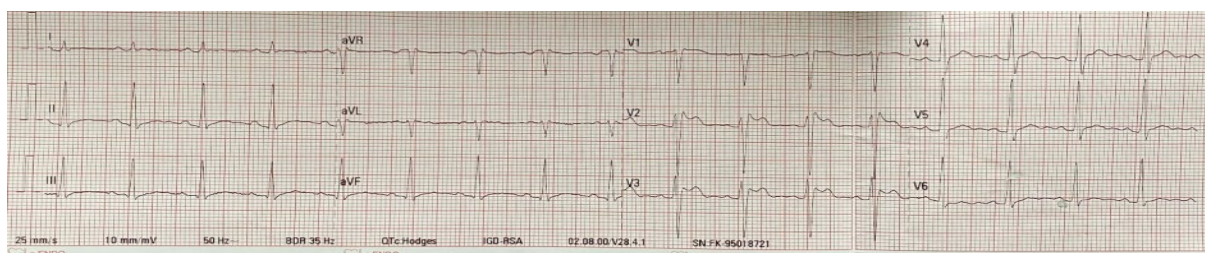


Figure 1. ECG Brugada pattern.

[12INAHRS-CR114]

Anticipated Ventricular Pacing Burden as Guidance for Pacing Modalities in a Young Patient with Ventricular Standstill: A Case Report

E. T. Saragih¹, A.C. Lubis², C. A. Andra³

¹Cardiology Resident, Cardiac Center H. Adam Malik Hospital, Faculty of Medicine Universitas Sumatera Utara, Medan, Indonesia ^{2,3}Cardiologist at Cardiac Center H. Adam Malik Hospital, Faculty of Medicine Universitas Sumatera Utara, Medan, Indonesia

Background: Ventricular standstill is a rare but potentially lethal bradyarrhythmia that can present with syncope, seizure-like activity, or sudden cardiac arrest. An accurate diagnosis and timely management are essential. The choice of pacing modality must consider the anticipated burden and long-term effects on ventricular function.

Case Illustration: A 16-year-old girl with a history of RHD had been receiving monthly intramuscular benzathine penicillin for 1.5 years. Over the past month, the patient had experienced multiple episodes of presyncope and seizure-like activity. Neurological workup, including EEG, was normal. Given the recurrent unexplained symptoms, she was referred to the arrhythmia unit. Physical exam noted a holosystolic murmur in the lower left sternal border; ECG showed sinus rhythm with complete RBBB. Echocardiography revealed left heart dilation and severe mitral regurgitation secondary to RHD. Laboratory findings were normal. Holter monitoring identified multiple episodes of P waves without a corresponding ventricular response, the longest lasting 6.9 seconds, consistent with ventricular standstill. There were 73 episodes of bradycardia with a <1% burden. Pacemaker implantation was indicated due to symptomatic pauses lasting more than 3 seconds. Given the preserved LVEF and anticipated low ventricular pacing burden, RV pacing was justified. However, post-implant off-pacing ECG revealed TAVB, and device interrogation in the VVIR 60 bpm mode showed 99% VP. After reducing the pacing rate to 50 beats per minute (bpm), the VP decreased to 45%.

Conclusions: This case highlights the importance of considering cardiac causes, such as ventricular standstill, in patients with unexplained seizure-like episodes. Holter monitoring was crucial for diagnosis. Guideline-based pacemaker implantation is essential in such cases. The choice of pacing modality should be guided by the anticipated long-term ventricular pacing burden to preserve cardiac function, particularly in young patients with structurally abnormal but preserved-function hearts.

Keywords: Ventricular standstill, Seizure, Syncope, Pacemaker, Rheumatic heart disease

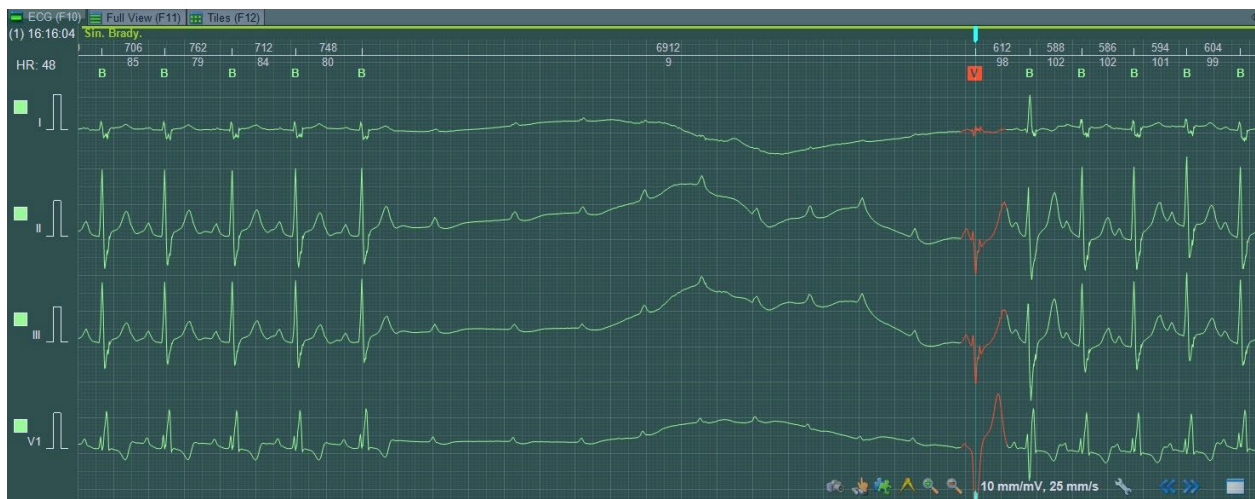


Figure 1. Ventricular standstill recorded on a Holter monitor, showing P waves without QRS complexes for 6,9 seconds.

[12INAHRS-CR115]

Expanding the Role of ICDs: Reducing Outflow Tract Obstruction in HCM Patients through RV Pacing and AV Delay Optimization

H. F. Hanim¹, S. Praptama¹, G. Karwiky¹, A. Saboe¹, M. Hasan¹, A. Astuti¹, M. Iqbal¹,
C. Achmad¹, H. S. Prameswari¹

¹*Department of Cardiology and Vascular Medicine, Hasan Sadikin General Hospital, Universitas Padjadjaran, Bandung, Indonesia*

Background: Hypertrophic cardiomyopathy (HCM) is a genetic cardiac disorder characterized by asymmetric myocardial hypertrophy, often involving the interventricular septum. It predisposes patients to malignant arrhythmias and sudden cardiac death (SCD). Implantable cardioverter-defibrillators (ICDs) have proven effective in the secondary and primary prevention of SCD in high-risk HCM patients.

Case Description: A 21-year-old male with a diagnosed HCM presented with persistent dyspnea on effort for the last four years. His family history was significant for SCD in his sibling. Echocardiography revealed septal hypertrophy (28 mm). Risk stratification identified him as being at high risk for SCD, and an ICD was implanted. During follow-up, the patient remained stable and had a significantly improved quality of life. Moreover, the device successfully detected and terminated ventricular tachyarrhythmias, thereby preventing SCD. Following ICD implantation, there was a significant reduction in the left ventricular outflow tract (LVOT) gradient from a baseline of 108.5 mmHg to 42.94 mmHg within 5 years.

Discussion: Implantable cardioverter-defibrillators (ICDs) play a pivotal role in reducing mortality by preventing sudden cardiac death (SCD) in patients with high-risk hypertrophic cardiomyopathy (HCM), particularly those with risk factors such as prior syncope, a family history of SCD, severe hypertrophy, or documented arrhythmias. Beyond their life-saving function, ICDs—especially when programmed with right ventricular apical pacing and optimized atrioventricular delay—can also improve hemodynamic status by altering ventricular activation patterns, reducing septal contractility, and relieving dynamic left ventricular outflow tract (LVOT) obstruction. This case underscores the dual benefit of ICD therapy, emphasizing the value of individualized risk assessment and device optimization in the comprehensive management of HCM.

Conclusion: ICD implantation is a critical intervention for patients with HCM at high risk of SCD. Early identification and implantation can markedly improve the survival rate and quality of life. Ongoing risk stratification is essential for optimal management.

Keywords: Hypertrophic Cardiomyopathy, Sudden Cardiac Death, Implantable Cardioverter-Defibrillator, Risk Stratification, Arrhythmia Prevention

[12INAHRS-CR116]

Cardiac Resynchronization Therapy via Conduction System Pacing in Right Bundle Branch Block and Heart Failure with Reduced Ejection Fraction: A Serial Case Experience

I.S. Pradisa¹, M. Ramdhani¹, G. Karwiky¹, M. Iqbal¹, C. Achmad¹

¹Department of Cardiology and Vascular Medicine, Universitas Padjadjaran, Bandung, Indonesia

Background: Cardiac resynchronization therapy (CRT) is a well-established treatment for patients with heart failure (HF) and electrical dyssynchrony. Clinical trials have consistently shown that CRT provides significant benefits in patients with left bundle branch block (LBBB). In contrast, observational studies have reported that patients with right bundle branch block (RBBB) tend to have higher mortality rates following CRT, with limited evidence supporting its benefits in this group. As an alternative approach to achieve electrical synchronization, conduction system pacing (CSP) has emerged as a promising therapy for heart failure. This study aimed to investigate the clinical outcomes of CSP as a resynchronization therapy in patients with heart failure with reduced ejection fraction (HFrEF).

Case Illustration: We present four patients with heart failure with reduced ejection fraction (HFrEF) and non-LBBB on baseline ECG who underwent CSP implantation. The first three HFrEF patients with RBBB underwent LBBAP (Left Bundle Branch Area Pacing), and the fourth with complete RBBB underwent HBP (His Bundle Pacing), with shorter QRS duration following CSP implantation. At follow-up, all patients demonstrated improvements in HF-related symptoms, NYHA functional class, and LVEF (28% to 30%, 42% to 45%, 29% to 31%, and 28% to 33%, respectively).

Conclusion: Resynchronization therapy via CSP in patients with RBBB is an alternative to achieve effective electrical synchrony, reverse remodelling, and improved cardiac function in patients with HFrEF. CSP restores native conduction and resynchronizes the ventricles by re-engaging the His-Purkinje system, potentially offering physiological pacing in cases where CRT fails.

Keywords: Cardiac Resynchronization Therapy, Conduction System Pacing, Right Bundle Branch Block, Heart Failure with Reduced Ejection Fraction.

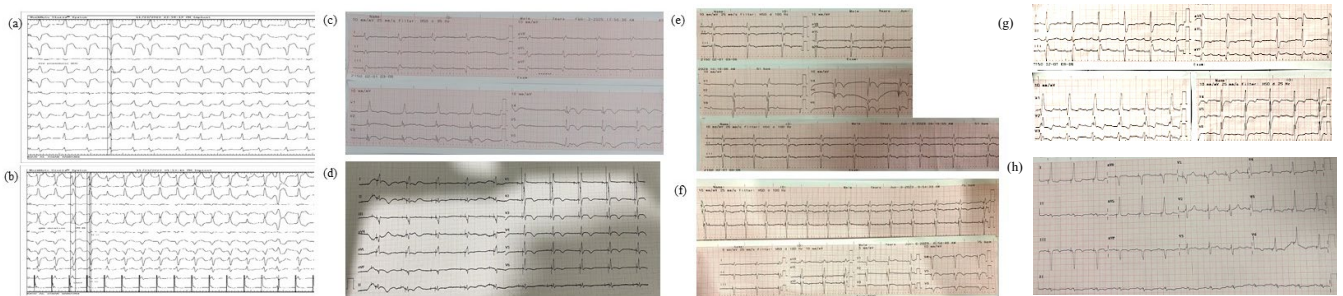


Figure 1. (a) Pre-CSP ECG of the first patient. (b) Post-CSP ECG of the first patient (QRS duration 186 to 152 ms). (c) Pre-CSP ECG of the second patient. (d) Post-CSP of the second patient (QRS duration 160 to 120 ms). (e) Pre-CSP ECG of the third patient. (f) Post-CSP ECG of third patient (QRS duration 160 to 120 ms) (g) Pre-CSP ECG of fourth patient. (h) Post-CSP ECG of the fourth patient (QRS duration, 160 to 128 ms).

[12INAHRS-CR117]

**Zero-Fluoroscopy Implantation of Dual-Chamber Permanent Pacemaker in a Pregnant Woman with Complete Atrioventricular Block Guided by Electroanatomical Mapping:
A Case Report**

M. A. Muharrom¹, A. R. Yolanda¹, A. Rizal¹

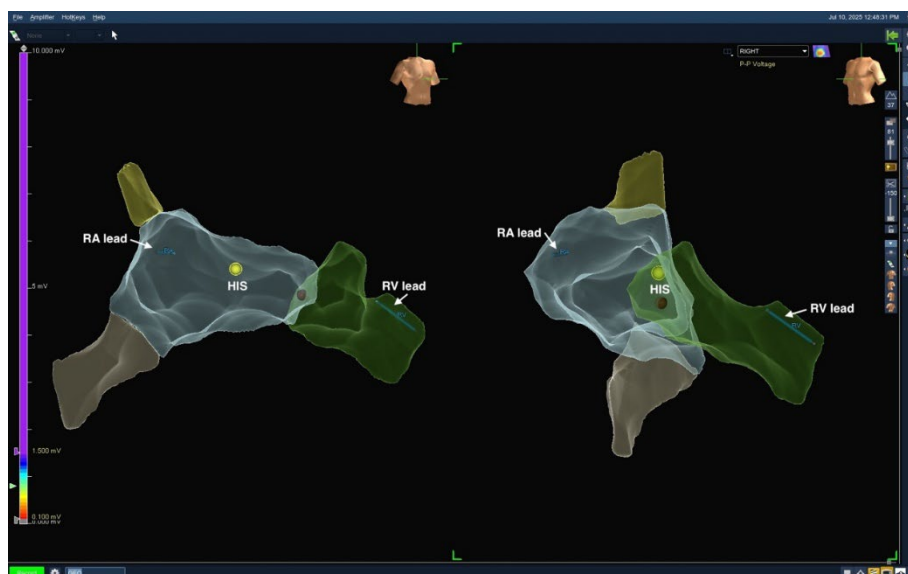¹*Department of Cardiology and Vascular Medicine, Faculty of Medicine, Universitas Brawijaya / Saiful Anwar General Hospital, Malang*

Background: Fluoroscopy is the primary imaging modality for guiding various cardiac catheterization procedures, including permanent pacemaker implantation. However, its use in pregnant women should be limited because of the fetal risks associated with X-ray radiation exposure. Electroanatomical mapping offers the potential to guide lead placement during permanent pacemaker implantation without fluoroscopy.

Case Illustration: A 28-year-old woman in the second trimester of pregnancy was referred to our center due to symptomatic total atrioventricular (AV) block. We decided to proceed with dual-chamber pacemaker implantation using the EnSite™ electroanatomical mapping (EAM) system to reduce fluoroscopy exposure. Through the left subclavian access, the pacemaker lead was inserted and used as a mapping catheter to create an electroanatomical map of the cardiac chambers. The pacemaker leads were successfully positioned in the mid-septal region of the right ventricle and right atrial appendage with the guidance of 3D mapping. No complications were observed during the procedure. Echocardiography showed that the leads were appropriately positioned.

Conclusion: This case demonstrated that 3D electroanatomical mapping is a safe and effective alternative to fluoroscopy for guiding permanent pacemaker implantation, including in pregnant women.

Keywords: total AV block, pregnancy, electroanatomical mapping, permanent pacemaker



[12INAHRS-CR118]
Acute Limb Ischemia in Atrial Fibrillation: Unusual Presentation

B.Kusumanti.¹ S. Yudha.²

¹General Practitioner, RSU An Nimah, Indonesia

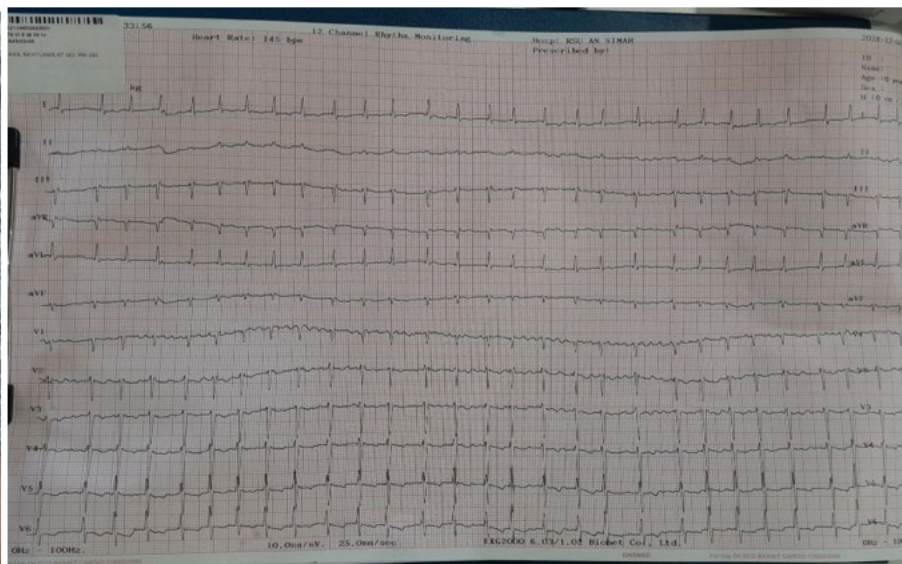
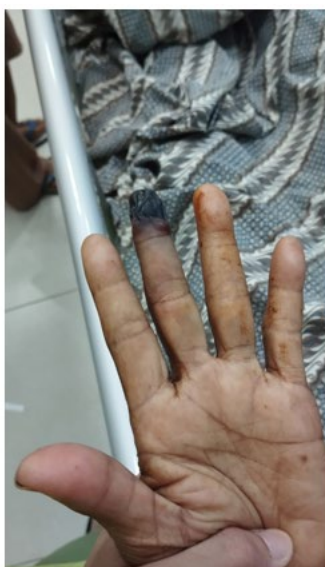²Department of Cardiology, RSU An Nimah, Indonesia

Background: Acute limb ischemia (ALI) presents as sudden ischemia of the lower limbs. Thrombosis and embolism are common causes of acute arterial occlusion. Thrombosis mostly arises from underlying cardiac diseases, such as arrhythmia, coronary artery disease, and valvular heart disease.

Case Illustration: A 79-year-old woman presented to the ER with complaints of toes and fingers suddenly becoming necrotic and painful for 2 weeks before admission, no history of trauma, and feeling dizzy. There was no chest pain, breathlessness, or palpitations. She had no history of diabetes, hypertension, peripheral vascular disease, arrhythmia, valvular heart disease, or smoking status. The clinical examination showed BP 112/83 mmHg, pulse rate 140 / min, irregular RR 20 / min, SpO2 96 % room air. Her toes and fingers were necrotic with SpO2 40% and anesthetic. Her heart sounds were normal, and there was no murmur. The ECG showed Atrial Fibrillation, and chest radiography revealed cardiomegaly. The laboratory results were normal. The patient was treated with unfractionated heparin 12 μ / kg/ hour, digoxin 1x1 tablet, atorvastatin 1x 20 mg, and warfarin 1x 2 mg. Because the acute limb ischemia was already stage 3 and irreversible, we referred the patient for further examination and management. An uncommon cause of ALI is acute arterial thromboembolism, and atrial fibrillation (AF) is the most important risk factor for systemic thromboembolism. AF predisposes patients to thrombus formation, especially in the left atrial appendage, with a risk of subsequent thromboembolism ranging from ischemic stroke to acute limb ischemia. Thus, atrial fibrillation can be one of the most important causes of lower limb ischemia in patients with PAD.

Conclusion: Patients with lower limb ischemia and atrial fibrillation require special attention to reduce complications and improve outcomes. Early detection and immediate medical and surgical care can prevent permanent disability. It is important to correctly identify the source of ALI for secondary prevention, as it depends on the underlying cause

Keywords: Acute Limb Ischemia, Atrial Fibrillation, Thromboembolism



[12INAHRS-CR119]

Management of Patient Congestive Heart Failure Reduced Ejection Fraction in an Obese Patient And Obstructive Sleep Apnea: A Case Report

K. Tarigan¹, M. C. D. Hasudungan², S. J. Prasetyo³, M. Bastanta⁴

¹General Practitioner of Bina Kasih Hospital General Hospital Medan, Indonesia

²Cardiologist of Santa Elisabeth General Hospital Medan, Indonesia

³Pulmonologist of Santa Elisabeth General Hospital Medan, Indonesia

⁴Internist-endocrinologist of Santa Elisabeth General Hospital Medan, Indonesia

Background: Obesity is a growing concern in Indonesia, with the prevalence among men rising to 22%, positioning the country at 168 out of 200 countries globally. Unmanaged obesity can lead to serious health issues, such as congestive heart failure (HF) and obstructive sleep apnea (OSA).

Case Illustration: A 37-year-old man presented to the emergency room with shortness of breath that worsened over three days, particularly during activities and sleep. He reported snoring that contributed to daytime drowsiness and fatigue. His vital signs indicated an elevated blood pressure and respiratory rate. Physical examination revealed significant obesity and signs of heart failure. Diagnostic tests showed issues with heart failure caused by dilated cardiomyopathy, and the left ventricular systolic function was reduced. Ejection Fraction (EF): 24.4%. The diastolic function of the left ventricle was impaired (Grade III). E/A ratio: 2, E/e': 16.6. Valves: mild mitral regurgitation (MR) and mild tricuspid regurgitation (TR). Cardiac chamber dimensions: eccentric left ventricular hypertrophy (LVH), left atrial (LA) dilation, good right ventricular (RV) contraction, TAPSE: 19 mm; The patient was prescribed several medications, including Ramipril, Bisoprolol, Salbutamol, Dapagliflozin, and Atorvastatin, to manage his condition. The patient's condition improved, and they were discharged after 7 days.

Based on physical examination, thoracic photographs, echocardiography, and in accordance with the European Society of Cardiology (ESC), CHF with reduced ejection fraction was confirmed, possibly due to dilated cardiomyopathy. From the physical examination, anamnesis, and calculation of STOP-BANG, the score was 8, indicating a high risk of OSA. Body Mass Index (BMI): 48.44 kg/m², so the patient was classified as grade II obese. Heart failure management focuses on lifestyle changes and OSA. Lifestyle changes and exercise, 150 minutes a week, with the achievement of 5-10% weight loss for patients with HF with BMI > 35 kg/m² can improve heart quality and function. Diet, exercise 300 min/week, dapagliflozin, semaglutide. Weight loss, changing sleeping position, and using a nasal spray.

Conclusion: Pharmacological and non-pharmacological treatment approaches are important for preventing and reducing the risk of heart attacks.

Keywords: Congestive Heart Failure, Obstructive Sleep Apnea

STOP		
Do you often SNORE loudly (louder than talking)	Yes	No
Do you often feel TIRED, fatigued or sleepy during day	Yes	No
Has anyone OBSERVED you stop breathing during sleep	Yes	No
Do you have high blood PRESSURE	Yes	No
BANG		
BMI more than 35Kg/m ²	Yes	No
AGE over 50 years	Yes	No
NECK circumference > 40cm	Yes	No
GENDER Male	Yes	No
Score 1 point for each positive response		
Scoring Interpretation: 0-2 Low Risk; 3-4 Intermediate Risk; 5 or more High Risk		

Figure 1. Stop Bang Score.

[12INAHRS-CR120]

**Left Ventricular Thrombus Leading to Cardioembolic Stroke in a Young Adult with Dilated
Cardiomyopathy: A Case Report**

C. Artha¹, T. Wijaya^{1,2}, F. Nurina², M. P. Airlangga³, I. Kartikasari³, M. N. Hamdani³.

^{1,3}*Siti Khodijah Sepanjang Hospital, Sidoarjo, Indonesia*

²*PKU Muhammadiyah Mojoagung Hospital, Jombang, Indonesia*

Background: Left Ventricular Thrombus (LVT) is a rare complication, commonly associated with myocardial infarction and dilated cardiomyopathy (DCM). LVT can lead to thromboembolic events, such as ischemic stroke, especially in patients with reduced ejection fraction (EF).

Case Illustration: A 30-year-old man with hypertension, type II diabetes mellitus, and active smoking presented to the emergency department with worsening shortness of breath over two hours, without chest pain. He had a history of chest pain two months prior, which resolved spontaneously. Vital signs were stable, and the physical examination was unremarkable.

Electrocardiography revealed sinus rhythm with left axis deviation and poor R-wave progression. Chest radiography revealed cardiomegaly with an early sign of pulmonary edema. Laboratory tests showed elevated glucose and LDL levels. Echocardiography revealed dilated cardiomyopathy and an LV Thrombus with EF of 26%. On day 3, the patient developed decreased consciousness with a GCS score of 8 (E2V2M4). Coagulation testing showed a subtherapeutic INR. Cranial CT Scan revealed an embolic infarction in the left parietal lobe associated with cerebral edema. Anticoagulants and antiplatelet agents were stopped, mannitol was administered, and decompressive craniectomy was planned.

Conclusion: Left ventricular thrombus (LVT) is a serious complication in patients with reduced ejection fraction, particularly those with dilated cardiomyopathy. This case involved a 30-year-old man with cardiovascular risk factors, including type II diabetes mellitus, hypertension, dyslipidemia, active smoking, and a family history of cardiovascular disease. Despite his young age, his estimated 10-year cardiovascular risk, using the Jakarta Cardiovascular Score (JCS), was classified as moderate to high. Subtherapeutic anticoagulant use, as indicated by a low INR, likely contributed to the subsequent cardioembolic stroke. This case highlights the importance of early LVT detection, appropriate anticoagulation with therapeutic INR monitoring, and aggressive modification of cardiovascular risk factors, even in young adults, to prevent devastating thromboembolic complications.

Keywords: Left Ventricular Thrombus, Dilated Cardiomyopathy, Cardioembolic Stroke

[12INAHRS-CR121]

Electrocardiographic Findings Indicative of Critical LAD Stenosis: A Case of Wellens' Syndrome

T. Wijaya¹, C. Artha¹, M. P. Airlangga¹, R. M. Budiarto¹, I. Kartikasari¹

¹Siti Khodijah Sepanjang Hospital, Sidoarjo, Indonesia

Background: Wellens' syndrome is an electrocardiographic pattern indicative of critical stenosis of the left anterior descending (LAD) artery, often presenting with chest pain that resolves before the ECG changes are evident. Early recognition is crucial for preventing extensive myocardial infarction.

Case Illustration: A 54-year-old woman with a history of uncontrolled hypertension presented to the emergency department with a two-week history of worsening chest pain, described as a pressing sensation radiating to the neck and left arm, accompanied by shortness of breath and vomiting. Her vital signs on admission were stable, with a blood pressure of 130/90 mmHg, heart rate of 98 bpm, and oxygen saturation of 98% on room air. Electrocardiography revealed sinus rhythm with Wellens' sign type A in lead V2 and Wellens' sign type B in leads V3-V6, along with high lateral ischemia indicated by ST segment depression in leads I and aVL. Chest radiography revealed cardiomegaly, and laboratory tests revealed elevated troponin and triglyceride levels. Cardiac catheterization confirmed 90% stenosis in the proximal to mid-segment of the LAD.

Conclusion: This case highlights the importance of recognizing Wellens' syndrome on ECG as a crucial indicator of critical LAD stenosis, even in the absence of ongoing chest pain or significant ST-segment elevation. Prompt diagnosis and intervention, such as cardiac catheterization, are essential to prevent adverse events in these patients.

Keywords: Wellens' Syndrome, LAD Stenosis

[12INAHRS-CR122]

Time is Muscle: Early Invasive Management of Inferoposterior ST-Elevation Myocardial Infarction (STEMI) Within One Hour of Onset

Y. Hanalena^{1,2}, N. Andini^{1,2}

¹General Practitioner, Haji General Hospital, Medan, Indonesia

²General Practitioner, Faculty of Medicine, Universitas Sumatera Utara, Medan, Indonesia

Background: ST-elevation myocardial infarction (STEMI) is a critical sign of acute coronary syndrome (ACS) and is frequently caused by the rupture of coronary plaques and subsequent thrombosis. Inferoposterior STEMI is infrequently identified owing to the inadequate use of posterior electrocardiography (ECG) leads; however, it entails considerable morbidity if not treated promptly. Timely recognition and aggressive intervention are essential for improving patient outcomes.

Case Illustration: We report the case of a 48-year-old woman with no previous angina but several unmitigated cardiovascular risk factors, including inadequately managed hypertension, exposure to passive smoking, and a significant family history of early coronary artery disease. She arrived at the emergency hospital with chest discomfort indicative of infarction radiating to the back, accompanied by diaphoresis and nausea. The ECG showed ST elevation in the inferior leads and ST depression in the anterior leads, prompting a posterior ECG, which confirmed ST elevation in V7–V9. Troponin I was significantly high at 5.52 ng/mL, indicating acute myocardial infarction. The patient received immediate dual antiplatelet treatment and was subsequently transferred for an initial percutaneous coronary intervention (PCI).

Conclusion: This case underscores the critical importance of early recognition and rapid intervention in inferior STEMI, a diagnosis often missed without posterior ECG leads, especially in high-risk patients. This underscores the need to integrate patient history, such as hypertension, passive smoking, and family history, into the initial risk evaluation. Supporting evidence demonstrates that these characteristics individually elevate the risk of acute coronary syndrome, particularly in women. Prompt acquisition of a posterior ECG, timely dual antiplatelet therapy, and urgent referral for PCI within the first hour of symptom onset exemplify the principle that "time is muscle." Early invasive management not only limits myocardial damage but also significantly improves clinical outcomes in high-risk patients, including those without a prior cardiac history.

Keywords: acute coronary syndrome, emergency, ST-elevation myocardial infarction, percutaneous coronary intervention.

[12INAHRS-CR123]

Comparative Evaluation of SMART WPW and Easy WPW for Accessory Pathway Localization in Wolff–Parkinson–White Syndrome: A Case Series

D. N. Sary¹, A. C. Lubis², M. P. Hutahusut², A. Handayani², M. Hutapea², C. A. Andra²

¹*Cardiology Resident, Department of Cardiology and Vascular, Faculty of Medicine, Universitas Sumatera Utara, Medan, Indonesia*

²*Cardiologist, Department of Cardiology and Vascular, Faculty of Medicine, Universitas Sumatera Utara, Medan, Indonesia*

Background: Wolff–Parkinson–White (WPW) syndrome is a congenital arrhythmia caused by an accessory pathway (AP) that bypasses the normal atrioventricular conduction system, leading to tachyarrhythmia and palpitations. Accurate localization of APs is essential for successful catheter ablation; however, traditional ECG algorithms, such as Easy WPW, often have limited accuracy in detecting atypical or oblique pathway orientations. The SMART WPW (Systematic Mapping and Assessment of Right and Left Tract) algorithm is a novel noninvasive tool designed to enhance AP localization in both adolescent and adult patients. This case series compares SMART WPW with Easy WPW, demonstrating its superior clinical utility and predictive precision

Case Illustration: Case 1: A 15-year-old girl with recurrent palpitations had an ECG showing negative delta waves in V1 and positive delta waves in leads II and III. Easy WPW suggested an anteroseptal tricuspid annulus pathway, while SMART WPW predicted a midseptal tricuspid annular AP (~3 o'clock). A 3D electrophysiology (EP) study confirmed an oblique pathway between 02:00 and 04:00, which was successfully ablated.

Case 2: A 51-year-old woman with palpitations showed a positive delta wave in V1 and a positive inferior axis. Easy WPW indicated a posterolateral mitral annular pathway, while SMART WPW predicted a lateral mitral annular AP (1–3 o'clock). A 2D EP study confirmed an anterolateral mitral AP at 01:00, successfully ablated.

Case 3: A 48-year-old man with palpitations had an ECG showing a positive delta wave in V1, a positive axis in lead II, and a negative axis in leads III and aVF. Both Easy WPW and SMART WPW predicted the posterolateral mitral annulus AP (~5 o'clock). A 2D EP study confirmed an AP between 04:00 and 05:00, successfully ablated

Discussion: In all cases, SMART WPW demonstrated high concordance with invasive EP mapping, whereas Easy WPW showed limitations in predicting AP locations, particularly in complex cases. SMART WPW provides superior accuracy in localizing APs across different anatomical regions and age groups, improving mapping efficiency and reducing procedural complexity.

Conclusion: The SMART WPW algorithm provides a reliable, noninvasive method for AP localization in patients with WPW syndrome. Its consistent accuracy, particularly in complex cases involving adolescents and adults, highlights its advantages over Easy WPW. SMART WPW has demonstrated superior predictive precision in both adolescent and adult populations, making it a valuable tool for AP localization in both populations. Larger prospective studies are needed to further assess its clinical utility and confirm its superiority in various clinical settings

Keywords: SMART-WPW, Accessory Pathway, Electrophysiology study

Table 1. Wolff–Parkinson–White's Comparison.

No.	Patient	Age	ECG					SMART WPW	EASY WPW	EP STUDY
			V1	V3	II	III	aVF			
1	Female	15	-	+	+	-	+	TV-MS 3 o'clock	TV-AS	Mitral annulus oblique orientation 2-4 o'clock
2	Female	51	+	+	+	+	+	MV-L 1-3 o'clock	MV-PL	Anterolateral mitral annulus 01.00 o'clock
3	Male	48	+	+	+	-	+	MV-LPL 5 o'clock	MV-PL	Posterolateral Mitral Annulus 4-5 o'clock

[12INAHRS-CR124]
**Failed Ablation of Incessant Left Atrial Tachycardia
In a Child With Arrhythmia-Induced Cardiomyopathy: What is Next?**

I. Posangi¹, S. B. Raharjo^{1,2}, D. Y. Hermanto^{1,2}, D. A. Hanafy^{1,2}, R. R. Waliyuddin^{1,2},
K. Rizky¹, Y. Yuniadi^{1,2}

¹National Cardiovascular Center Harapan Kita, Jakarta, Indonesia

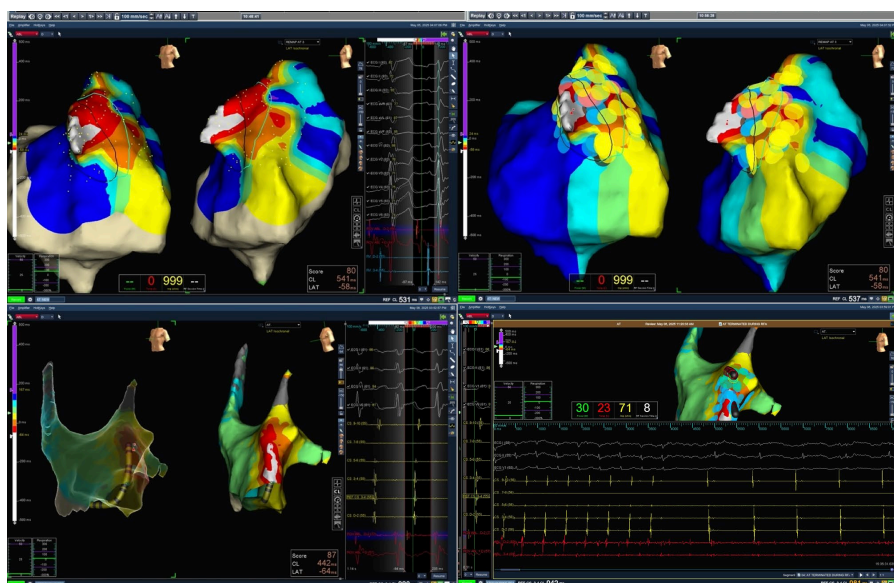
²Faculty of Medicine, Universitas Indonesia, Jakarta, Indonesia

Background: Left Atrial Appendage (LAA) atrial tachycardia is rare in children and often manifests as an incessant rhythm that may progress to arrhythmia-induced cardiomyopathy if not promptly treated. Radiofrequency ablation (RFA) is the initial treatment of choice; however, the outcomes may be limited because of the complex anatomy of the appendage and the risks associated with repeated ablations at the same site.

Case Illustration: An 8-year-old girl was referred to the National Cardiovascular Center Harapan Kita with a persistent atrioventricular (AV) block resistant to multiple antiarrhythmic medications and electrical cardioversion. The patient had a reduced LV ejection fraction of 42%. Electrocardiography showed a narrow-complex tachycardia at 152 bpm, a long RP interval, bifid P waves in lead V1, and negative P waves in lead II, suggesting LAA/LPV origin. Electrophysiological studies revealed the earliest A activation in the distal coronary sinus (CS 1-2). Using a high-density grid catheter and Ensite 3D mapping system, the earliest local activation time (-58 ms) was identified at the left atrial appendage (LAA) tip. Multiple RFAs, including focal ablation and circumferential LAA isolation, briefly terminated tachycardia. A second procedure, performed 2 days later, also failed to sustain AT termination. The patient was discharged with ongoing AT at 180 bpm on oral amiodarone, bisoprolol, and diltiazem, with plans for elective LAA resection or AV ablation and pacing. At the outpatient follow-up, her heart rate remained at approximately 180-200 bpm. We decided to initiate Ivabradine at 1 mg twice daily. Within a month, the patient was asymptomatic, and the ECG showed AT with significantly decreased heart rate.

Conclusion: LAA-origin AT in pediatric patients is often resistant to RFA, especially arising from distal regions. When ablation fails, alternative strategies such as LAA surgical resection, AV node ablation and pacing, epicardial ablation or novel antiarrhythmia agents should be considered to prevent progression of arrhythmia-induced cardiomyopathy.

Keywords: Left Atrial Tachycardia Ablation, Arrhythmia-Induced Cardiomyopathy



[12INAHRS-CR125]

A Rare Case of a Young Patient with Atrial Fibrillation, Epicardial Atrial Tachycardia, and Atrioventricular Nodal Re-entrant Tachycardia

**P. Lestari^{1,2}, S.B. Raharjo^{1,2}, D.A. Hanafy^{1,2}, D.Y. Hermanto^{1,2}, R.R. Waliyuddin^{1,2}, K. Rizky²,
Hasanuddin², Y. Yuniadi¹**

¹Faculty of Medicine, Universitas Indonesia, Jakarta, Indonesia

²National Cardiovascular Center Harapan Kita, Jakarta, Indonesia

Background: The presence of multiple supraventricular arrhythmia mechanisms in a single patient is uncommon, particularly in young individuals, and poses significant diagnostic and therapeutic challenges. Advances in three-dimensional (3D) electroanatomic mapping have enhanced the precision of arrhythmia localization and ablation, enabling individualized and stepwise treatment strategies.

Case Illustration: We report the case of a 31-year-old woman with recurrent palpitations who was referred for catheter ablation. The baseline ECG showed a sinus rhythm. An electrophysiological (EP) study revealed sustained narrow QRS tachycardia induced by right ventricular burst pacing. Diagnostic maneuvers confirmed typical slow-fast atrioventricular nodal reentrant tachycardia (AVNRT). Slow pathway ablation was performed using a SmartTouch Thermocool EZ Steer™ irrigated catheter (30 W, 45°C, 30 s, 17 ml/min) during sinus rhythm. A single transeptal puncture was performed via the SL0 sheath, followed by Inoue wire exchange into an Agilis steerable sheath. 3D electroanatomic mapping of the left atrium using the Carto system and Pentaray catheter-guided circumferential point-by-point radiofrequency ablation of all four pulmonary veins (LSPV, LIPV, RSPV, RIPV) with high-power RF (40–50 W, 45°C, 10 s, 22 cc/min), followed by additional ablation at the carina and anterior RSPV. Voltage mapping confirmed durable pulmonary vein isolation with entrance and exit blocks. Post-PVI testing revealed inducible focal atrial tachycardia. The first atrial tachycardia (AT1) demonstrated the earliest activation at the lateral mitral annulus and was successfully treated with ablation. The second AT (AT2) showed the earliest activation in the proximal coronary sinus (CS 9–10), consistent with an epicardial origin, and was successfully ablated. No further ATs were inducible after 30 minutes of observation.

Conclusion: This case highlights the rare coexistence of atrial fibrillation, epicardial atrial tachycardia, and AVNRT in a young patient. The successful management using sequential mapping and ablation underscores the importance of a comprehensive and individualized electrophysiological approach to complex arrhythmia substrates.

Keywords: Atrial Fibrillation, Epicardial Atrial Tachycardia, Atrioventricular Nodal Re-entrant Tachycardia, Catheter Ablation

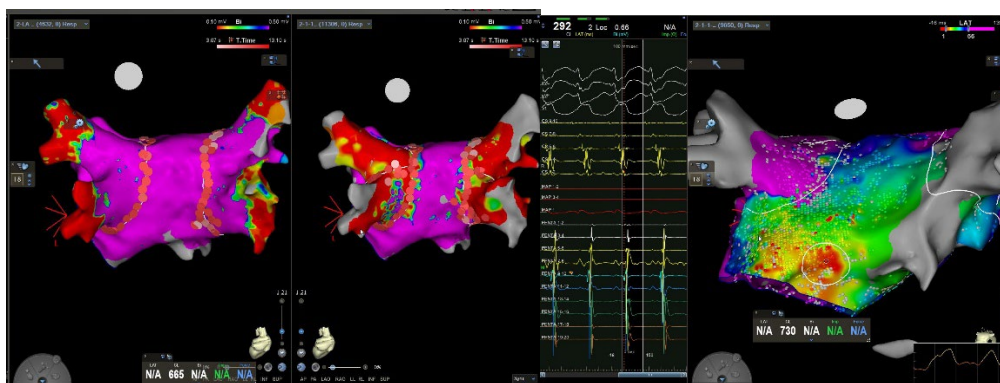


Figure 1. (A) Voltage mapping of PVI Post Ablation (B) LAT mapping showed the earliest A at CS 1-2

[12INAHRS-CR126]

Dopamine and Norepinephrine as Temporary Hemodynamic Support in Total Atrioventricular Block: A Rural Area Case Report

N. N. Annisa¹, C. Y. Sari¹, M. Jamilah²

¹General Practitioner, Medina Hospital, Garut, Indonesia

²Cardiologist, Medina Hospital, Garut, Indonesia

Background: Total atrioventricular (AV) block is a life-threatening condition characterized by a complete loss of coordination between atrial and ventricular activity, often requiring pacemaker implantation. In rural areas with limited healthcare resources, where pacemaker implantation is unavailable, alternative strategies must be considered to stabilize the patient prior to referral to a tertiary healthcare facility. This case highlights the use of dopamine and norepinephrine as temporary therapies in settings where immediate pacing is not feasible.

Case Illustration: We report a case of a 61-year-old man presenting with epigastric and left-sided chest pain radiating to the back for five days. He had a history of cardiac disease eight years prior but was uncertain of the specific diagnosis. In the initial assessment, electrocardiography (ECG) revealed complete dissociation of the P waves and QRS complexes, ST-segment depression in V3 and slight ST elevation in lead II, and a prolonged QT interval, findings consistent with Total AV Block and possible myocardial ischemia. The blood pressure and heart rate were 90/60 mmHg and 33 bpm, respectively. Cardiac Troponin I levels were within normal limits. Electrolyte results for sodium, chloride, and potassium were within normal limits; in contrast, calcium levels were slightly below normal at 2.16 mmol/L. Inotropic support was initiated with intravenous dopamine and norepinephrine to achieve a hemodynamic response. The patient was admitted to the High Care Unit (HCU) for two days for close monitoring of his condition. Follow-up ECG revealed a return to normal sinus rhythm. However, the patient refused to be referred for further evaluation and permanent pacemaker implantation. He was subsequently discharged in a stable condition after a five-day hospitalization. Echocardiography was performed during a follow-up visit to the cardiology outpatient clinic one week after hospital discharge, and the results were within normal limits.

Conclusion: In resource-limited settings, dopamine and norepinephrine can be considered as temporary hemodynamic support in patients with total AV block, although they cannot replace the definitive therapy of pacemaker implantation. Early recognition and appropriate supportive therapy are essential for optimizing patient outcomes.

Keywords: Dopamine, Norepinephrine, Total AV Block

[12INAHRS-CR127]

**Ventricular Tachycardia in a Patient with Untreated Wolff-Parkinson-White Syndrome:
A Case Report**

B. Khoirunnisa¹, L.A.G. Andriyani¹, L.P.P.D Putri¹

¹*Grha Bhakti Medika Hospital, Klungkung, Bali, Indonesia*

Background: Wolff-Parkinson-White (WPW) syndrome is a congenital cardiac condition featuring an accessory pathway (AP) that allows electrical impulses to bypass the atrioventricular (AV) node. While a significant proportion of patients with WPW syndrome remain asymptomatic, abrupt-onset, life-threatening tachyarrhythmias may present as the initial symptom of an undiagnosed or untreated condition.

Case Illustration: A 56-year-old male patient presented to the ER with chief complaints of palpitations and chest pain with an onset of 16 hours prior to admission. The patient had previously been diagnosed with an unknown cardiac condition that provoked previous syncopal episodes but had been lost to follow-up since 2020. The patient had no known risk factors for coronary artery disease. The patient presented with diaphoresis and severe agitation with a weak radial pulse. The patient was placed on a monitor, which revealed broad complex tachycardia. The findings of the physical examination were unremarkable. The 12-lead ECG revealed regular, wide-complex tachycardia with a rate of 250-300 beats/minute, no visible P waves, and positively concordant QRS complexes of approximately 200ms. Synchronized cardioversion of 100 J was administered, which converted the patient back to sinus rhythm. Postcardioversion ECG revealed delta waves in the precordial leads with a dominant R wave in V1, suggesting a left-sided AP. In addition, pseudo-infarction patterns of Q waves can be observed in the inferior leads. The patient was stabilized and observed in the ICU and then referred to an electrophysiologist for electrophysiology studies and radiofrequency ablation.

Conclusion: Rapid diagnosis and management, along with long-term patient follow-up, are key to preventing sudden cardiac death in patients with WPW syndrome.

Keywords: Case report, Ventricular Tachycardia, Wolff-Parkinson-White syndrome (WPW), Pre-excitation, Accessory Pathway

[12INAHRS-CR128]

Successful Radiofrequency Ablation of Focal Atrial Tachycardia Originating from the Posterior Superior Vena Cava

F. Tedjasukmana¹, B. Hartono^{1,2}, EJ Gunawan¹, DL Munawar¹, DA Munawar¹, M Munawar¹

¹Binawaluya Cardiac Center, Jakarta, Indonesia

²Premier Bintaro Hospitals, Jakarta, Indonesia

Background: Focal atrial tachycardia (AT) originating from the superior vena cava (SVC) is a rare but increasingly recognized arrhythmogenic focus, particularly in patients with structurally normal hearts. These arrhythmias can be sustained and are symptomatic. Catheter ablation has become a definitive treatment strategy, especially for patients refractory to medical therapy or with a high arrhythmic burden.

Case Illustration: A 41-year-old woman presented with recurrent palpitations lasting 1–2 minutes initially, which gradually increased in duration, with the last episode lasting up to 30 minutes. Her heart rate reached 200 bpm during these episodes. Twenty-four-hour Holter monitoring demonstrated multiple sustained AT episodes with a peak heart rate of 205 bpm and a premature atrial contraction (PAC) burden of 12.27%. Transthoracic echocardiography revealed normal cardiac structure and function of the heart. Given the increasing symptoms, the patient was scheduled for ablation. Narrow complex tachycardia was induced using S1–S2 pacing from the coronary sinus catheter. Entrainment from the right ventricle showed a V–A–A–V response, consistent with the diagnosis of focal AT. High-density 3D electroanatomical mapping using an HD Grid catheter (Abbott) localized the earliest activation site to the posterior wall of the SVC, which was located superoposteriorly to the sinoatrial node region, near the SVC-RA junction. Radiofrequency ablation was performed at 30 watts for 12–15 seconds per lesion. There was an impedance drop of approximately 10–15 ohms. The AT terminated during ablation and remained non-inducible after the procedure. The patient was discharged the next day and remained arrhythmia-free at follow-up.

Conclusion: This case highlights the importance of considering the SVC as a potential source of focal AT. Electroanatomical mapping using high-resolution catheters can facilitate the accurate localization and successful ablation of arrhythmogenic foci, resulting in excellent outcomes.

Keywords: Atrial tachycardia, superior vena cava, radiofrequency ablation, electroanatomical mapping, high-density mapping

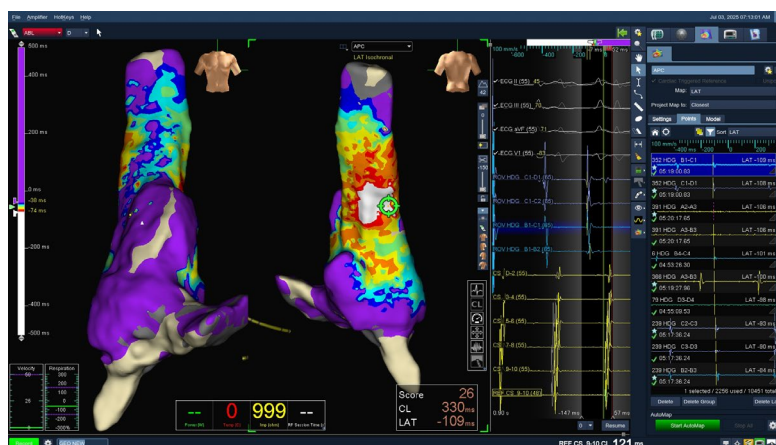


Figure 1. Three-dimensional activation mapping of the SVC revealed earliest activation area from posterior wall of the SVC (near SVC-RA junction).

[12INAHRS-CR129]
Clinical Course and Complications Following Transvenous Temporary Pacemaker

P. Risani¹, T. Daindes²

¹Cardiology Resident of Faculty of Medicine, Universitas Andalas/ Dr. M. Djamil Hospital, Padang, Indonesia
²Consultant of the Department of Cardiology and Vascular Medicine, Faculty of Medicine, Universitas Andalas/
Dr. M. Djamil Hospital, Padang, Indonesia

Background: Transvenous temporary pacemaker (TPM) use is common in patients with life-threatening bradyarrhythmias. Although TPM implantation is generally safe, several fatal complications may arise, including those related to venous access, catheterization, and lead dysfunction.

Case illustration: A 59-year-old woman presented with complaints of dizziness and syncope 3 days before admission. Electrocardiography revealed complete heart block (CHB) with junctional escape beats. The laboratory results were normal. The patient then underwent transvenous TPM implantation. Before the procedure, we performed bedside echocardiography, which revealed a normal cardiac anatomy and function. During TPM insertion, complications arose due to lead positioning and intermittent loss of capture. After successful repositioning and reprogramming of the TPM, the patient developed clinical signs of pericardial tamponade and pericardial effusion on echocardiography. Pericardiocentesis was performed, but further complications ensued, including misplacement of the pigtail catheter and post-procedural bleeding. Further echocardiographic evaluation revealed cardiac perforation at the apex of the right ventricle (RV), minimal circumferential pericardial effusion, and massive left-sided pleural effusion.

The patient then underwent implantation of a permanent pacemaker (PPM), and the following day, sternotomy was performed. During the procedure, a hemothorax was found in the left pleural cavity, with minimal pericardial effusion, and a 2 mm right ventricular (RV)-pericardial fistula was found in the apical-inferior-septal region of the right ventricle, and repair was performed. The TPM was successfully removed from its insertion site in the femoral area, and the position and function of the PPM were confirmed to be proper. The patient's clinical course was complicated by respiratory failure, sepsis, and eventual cardiac arrest, which led to her death after 18 days of intensive care unit admission.

Conclusion: Although TPM is commonly used in the emergency treatment of patients with severe bradyarrhythmia, it carries the risk of serious complications, such as pericardial tamponade, myocardial perforation, and pleural effusion, as seen in this case. Timely recognition and intervention are crucial for managing these complications, highlighting the need for further research to improve outcomes and minimize risks associated with TPM procedures.

Keywords: temporary pacemaker, atrioventricular block, complication

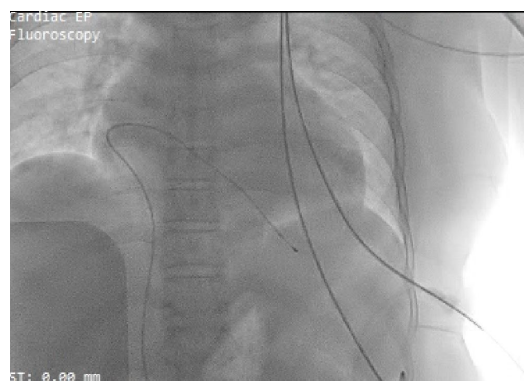


Figure 1. Pigtail position from fluoroscopy after pericardiocentesis in the AP position.

[12INAHRS-CR130]

Reversible Ventricular Tachycardia in Cardiorenal Syndrome Triggered by Sepsis: A Case Report

K.A. Fitra¹, R.H. Syafar²

¹Medical Doctor, Royal Prima Hospital, Kota Jambi, Jambi, Indonesia

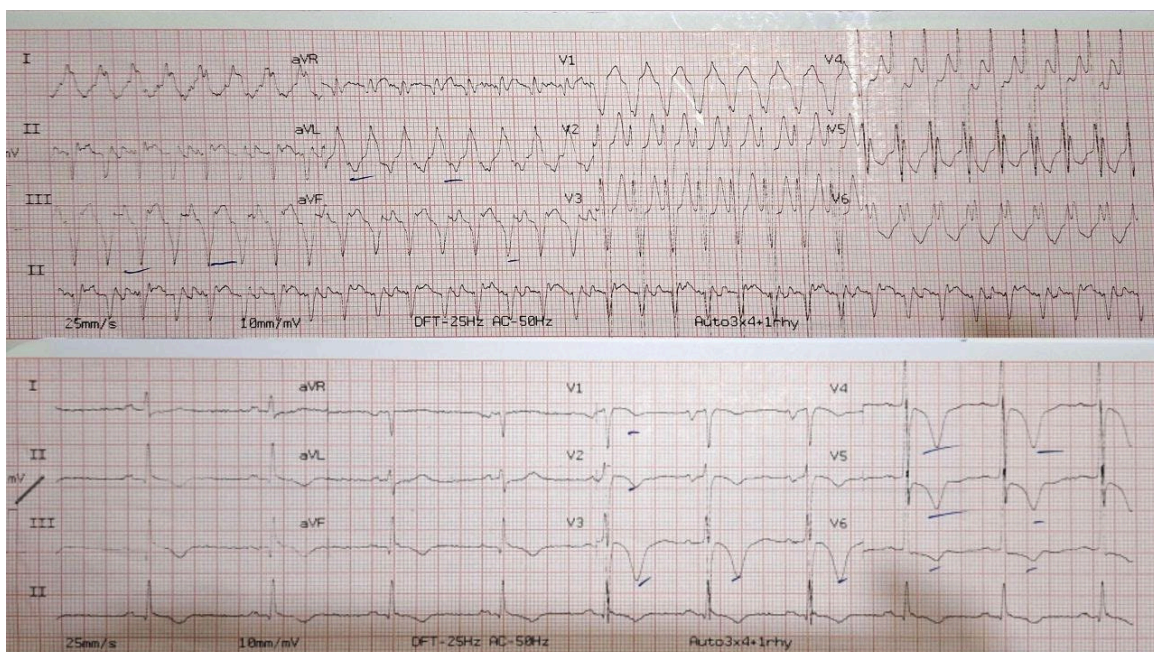
²Department of Cardiology and Vascular Medicine, Royal Prima Hospital, Jambi, Indonesia

Background: Ventricular Tachycardia (VT) is a life-threatening arrhythmia usually found in patients with structural heart disease. The risk of arrhythmia increases in chronic heart and kidney diseases. Infections and metabolic disorders can worsen the condition. A good understanding of the relationship between these conditions is essential for optimal patient management.

Case illustration: A 49-year-old man presented with palpitations and generalized weakness. The medical history showed that the patients had CHF (HFrEF, Ischemic DCM) and AKI. Vital signs showed hypotension (blood pressure, 84/53 mmHg) and a heart rate of 196bpm. The ECG shows VT in LBBB Patterns. Laboratory results showed leukocytosis (WBC $16.2 \times 10^3/\mu\text{L}$), increased urea (199 mg/dL) and creatinine (5.7 mg/dL) levels, and mild hyponatremia, which was assumed to be a possible trigger of VT in cardiorenal syndrome. Initial management included intravenous amiodarone, sodium bicarbonate, beta-blockers, and antibiotics. Cardioversion (100 joules) is an option because the patient is in an unstable VT condition. Subsequently, the patient returned to a stable sinus rhythm. Comprehensive and continuous treatment is provided during outpatient care. The ECG showed sinus rhythm, and kidney function remained within normal limits after 3 months of treatment.

Conclusion: VT in patients with CHF and AKI is often triggered by several factors, including cardiac hypoperfusion and infection. In these cases, sepsis plays a role as a trigger for VT, which worsens the condition. Cardioversion is an option for changing an abnormal rhythm to a normal rhythm in patients with unstable VT. Comprehensive treatment of triggering factors, such as sepsis, can improve patient prognosis. VT in ischemic DCM often recurs even after electrical cardioversion. Therefore, ICD, CRT-D, or ablation catheter is considered for preventing recurrent VT. Long-term monitoring and good management of heart and kidney conditions are essential to prevent future recurrence of arrhythmias.

Keywords: Ventricular tachycardia, cardiorenal syndrome, electrical cardioversion



[12INAHRS-CR131]
Feasibility of Transvenous and Conduction System Pacing in Pediatric Patients with Normal and Congenital Heart Disease: A Case Series Analysis

M. Rafi¹, G. Karwiky¹

¹Department of Cardiology and Vascular Medicine, Faculty of Medicine, University of Padjadjaran, Bandung, Indonesia.

Background: Permanent pacing in pediatric patients poses unique technical and clinical challenges, particularly in terms of body size, venous access, and long-term pacing-related complications. Traditional right ventricular apical pacing is associated with pacing-induced cardiomyopathy and dyssynchrony. Conduction system pacing (CSP), including His bundle pacing (HBP) and left bundle branch area pacing (LBBAP), offers a more physiological alternative that preserves the native electrical conduction pathway. Although CSP is increasingly used in adults, its feasibility and safety in children, particularly those with or without congenital heart disease (CHD), are less well established. This case series illustrates the application of transvenous CSP in two pediatric patients with complete atrioventricular block (TAVB) and different cardiac anatomies.

Case Illustration:

Case 1: An 8-year-old boy presented with recurrent syncope episodes, predominantly during physical exertion. Electrocardiography demonstrated TAVB with varying escape rhythms of different axes and morphologies (LBBB and RBBB patterns), suggesting a multifocal origin. Transthoracic echocardiography confirmed a structurally normal heart anatomy. The patient successfully underwent transvenous implantation of a single-chamber pacemaker using CSP.

Case 2: An 8-year-old girl with a history of surgically corrected ventricular septal defect (VSD) and patent ductus arteriosus (PDA) closure presented with recurrent seizures. ECG revealed TAVB with a junctional escape rhythm. Electroencephalography (EEG) was within normal limits, ruling out primary neurological causes. Transthoracic echocardiography revealed no residual VSD or PDA, with mild aortic regurgitation. A single-lead transvenous CSP was implanted successfully. The ECGs from both cases showed a pacing rhythm with regular narrow QRS complexes, consistent with effective His-Purkinje conduction capture. Postoperative recovery was uneventful, and the patients demonstrated improved exercise tolerance with stable pacing threshold values.

Conclusion: These cases demonstrate that CSP via a transvenous approach is a feasible and effective option for pediatric patients with TAVB, even after prior CHD repair. CSP offers the advantage of physiological pacing with minimal ventricular dyssynchrony, potentially reducing the risk of long-term complications. While technical expertise and anatomical considerations are essential, CSP represents a promising strategy for selected pediatric populations.

Keywords: Conduction system pacing, pediatric pacing, atrioventricular block, congenital heart disease.

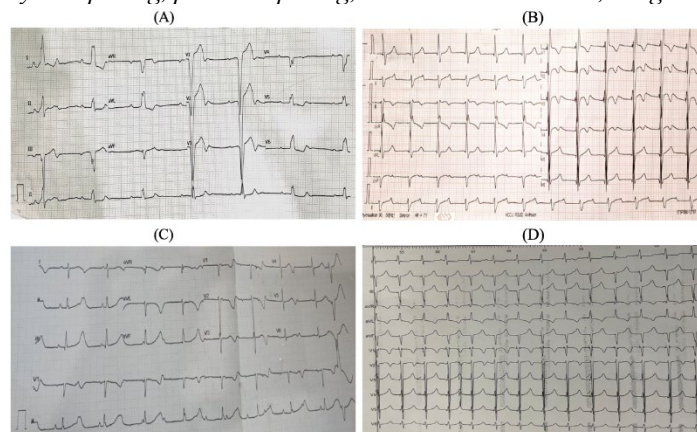


Figure 1. Electrocardiography from Case 1 (A and B) and case 2 (C and D). (A) showed complete AV block with unifocal infrequent ventricular extra systole and LBBB pattern, (C) showed complete AV block with junctional escape rhythm. (B) and (D) were ECG post CSP intervention showed pacing rhythm with regular narrow QRS complex, consistent with effective His-Purkinje conduction capture.

[12INAHRS-CR132]
**Klein Manoeuvre on Right Bundle Branch Block Morphology
After Right Ventricular Endocardial Pacing**

R. Wahyuni¹, Alfredo¹, F. Tandri¹, M. Helthayana¹, A.Y.A.B Mochtar¹, P. Ardianto¹

¹ Department of Cardiology and Vascular Medicine, Faculty of Medicine,
Universitas Diponegoro – Kariadi Hospital Semarang, Indonesia

Background: Right ventricular (RV) endocardial pacing typically produces left bundle branch block (LBBB) morphology on surface electrocardiography (ECG). However, in a small subset of patients (estimated at 8.3 %), a paradoxical right bundle branch block (RBBB) morphology may appear following RV pacing. This rare and atypical ECG presentation presents a unique challenge, necessitating careful interpretation to distinguish true RBBB from pacing-related artifacts. Attention to paced QRS morphology is critical for confirming accurate RV lead positioning and preventing complications, such as septal or free wall perforation.

Case Illustration: A 70-year-old man presented with syncope and was diagnosed with total atrioventricular block (TAVB) on ECG, alongside evidence of a hemorrhagic stroke on cranial CT. A temporary pacemaker was urgently inserted into the RV apex. Due to continued pacing dependency after two weeks, the patient underwent implantation of a permanent single-chamber pacemaker, also positioned at the RV apex. Post-procedural ECG unexpectedly revealed RBBB morphology, raising concerns about lead malposition or potential myocardial perforation. However, chest radiography and transthoracic echocardiography confirmed correct lead placement at the RV apex. The Klein maneuver, a simple yet crucial clinical tool, was performed, and the RBBB morphology resolved, supporting the diagnosis of a benign pseudo-RBBB, a known variant that can mimic true RBBB in patients with RV apical pacing.

Conclusion: RBBB morphology on ECG following RV endocardial pacing may reflect either a benign variant or a complication, such as lead malposition or perforation. It is crucial to be alert and cautious, as the Klein maneuver is a simple clinical tool that helps confirm uncomplicated RV apical pacing.

Keywords: Right Bundle Branch Block morphology, Klein manoeuvre, Right Ventricular Endocardial Pacing

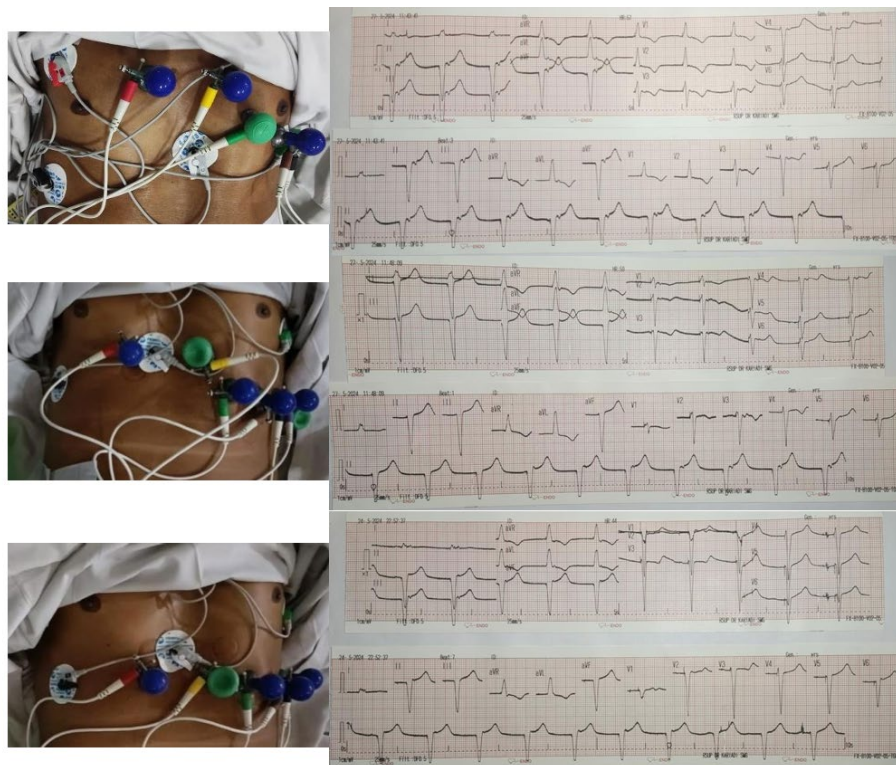


Figure 1. The Klein manoeuvre showed the disappearance of RBBB morphology in V1 and V2.

[12INAHRS-CR133]

Conduction Crisis Averted: Trifascicular Block Progressing Ventricular Asystole Managed by Left Bundle Branch Area Pacing

I. A. Balqis¹, S. B. Raharjo^{1,2}, D. Y. Hermanto^{1,2}, D. A. Hanafy^{1,2}, Y. Yuniadi^{1,2}, A. M. Zharfan¹, D. V. Chrismara¹

¹National Cardiovascular Center Harapan Kita, Jakarta, Indonesia; ²Faculty of Medicine, Universitas Indonesia, Jakarta, Indonesia

Background: Trifascicular block, defined as conduction delay or block in all three major fascicles of the His-Purkinje system, is a potentially life-threatening condition, especially when accompanied by symptoms such as syncope or documented asystole. Left Bundle Branch Area Pacing (LBBAP) has emerged as a promising alternative to right ventricular or biventricular pacing, as it preserves physiological ventricular activation. We present a case of a patient with trifascicular block that progressed to ventricular asystole, which was successfully managed with dual-chamber LBBAP.

Case illustration: A 67-year-old man was referred to our clinic after an episode of syncope. Baseline electrocardiography (ECG) revealed sinus rhythm, right bundle branch block (RBBB), left atrial enlargement, and a prolonged PR interval, indicating trifascicular block. Echocardiography revealed normal cardiac chamber dimensions, preserved left ventricular ejection fraction (LVEF 68%), and a sclerotic but functionally normal aortic valve. Laboratory investigations were within the normal range.

A 24-hour Holter monitor, performed before admission, revealed episodes of ventricular asystole that correlated with the patient's syncopal episodes. Given the high risk of recurrent syncope and potential sudden cardiac death, permanent pacing was performed. A dual-chamber pacemaker was implanted using the Left Bundle Branch Area Pacing (LBBAP) approach. The pacemaker was set in the DDD-R mode at a rate of 60–130 bpm. LBBAP capture was confirmed intraoperatively at a ventricular pacing output of 3.5 V@ 0.4 ms. Post-procedural ECG confirmed an atrial-sensed ventricular-paced rhythm and preserved sinus rhythm, indicating successful implantation. The patient had no recurrence of symptoms at follow-up and remained clinically stable.

Conclusion: Trifascicular block with ventricular asystole poses a high risk of syncope and sudden cardiac events. Left Bundle Branch Area Pacing is an effective physiological pacing option in such cases, providing stable pacing parameters and favorable clinical outcomes.

Keywords: trifascicular block, ventricular asystole, left bundle branch area pacing

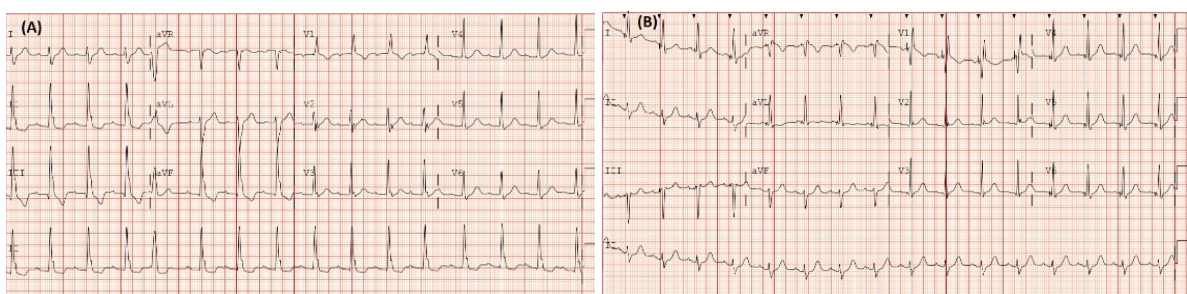


Figure 1. (A) Baseline ECG showing right bundle branch block, left atrial enlargement, and prolonged PR interval (224 ms), showing a trifascicular block with a heart rate of 92 bpm. (B) The postoperative ECG shows a ventricular-paced rhythm.

[12INAHRS-CR134]

Unveiling Late-Diagnosed Rheumatic Mitral Stenosis Through Arrhythmia in a Young Woman with a History of Stroke

A.R. Solehah¹, K. Humaira², A. Prawasti³

¹Internship at Citra Husada Hospital, Jember, East Java, Indonesia

²Internship at RSUD Dr. RM Pratomo, Rokan Hilir, Riau, Indonesia

³Cardiology Department, Citra Husada Hospital, Jember, East Java, Indonesia

Background: Rheumatic mitral stenosis (RMS) is a public health issue in Indonesia, predominantly affecting women around the age of 44 years. The most common comorbidities include atrial fibrillation (AF) and a history of ischemic stroke. Notably, most patients with RMS are unaware of any preceding acute rheumatic fever (ARF) episodes. The incidence of stroke in patients with mitral stenosis is reported to be as high as 9.4%, which is thought to be associated with the high prevalence of intracardiac thrombi (15.1%) and atrial fibrillation (70.4%) in this population.

Case Illustration: A 40-year-old woman with a history of ischemic stroke presented with progressive dyspnea and palpitations. These symptoms were accompanied by epigastric discomfort and bilateral swelling of the hands and the feet. She denied any history of hypertension, diabetes, asthma, or thyroid disease. There was no known history of rheumatic heart disease or acute rheumatic fever. Electrocardiography revealed atrial fibrillation with a rapid ventricular response (AF-RVR), and initial treatment included digoxin, bisoprolol, spironolactone, and furosemide. After heart rate control was achieved, a grade II–III diastolic rumbling murmur was detected. Transthoracic echocardiography confirmed moderate-to-severe mitral stenosis and multivalvular regurgitation secondary to rheumatic heart disease. Oral anticoagulation with warfarin was initiated. The patient showed significant clinical improvement; however, during follow-up seven days after hospital discharge, she experienced a recurrence of palpitations. Repeat electrocardiography demonstrated persistent atrial fibrillation with a rapid ventricular response.

Conclusion: Atrial fibrillation may be an early clinical clue of latent rheumatic mitral stenosis, particularly in younger patients with a prior stroke. Early detection by auscultation with echocardiographic confirmation is essential. Integrated early management, including ventricular rate control and risk-based anticoagulation, is crucial for reducing subsequent morbidity and mortality.

Keywords: Atrial Fibrillation, Rheumatic Mitral Stenosis, History of Cerebrovascular Accident, Thromboembolism Risk, Anticoagulation Management

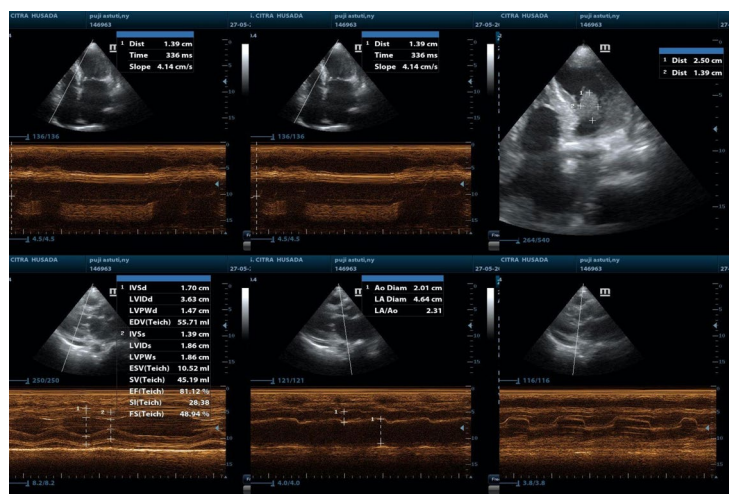


Figure 1. Echocardiography.

[12INAHRS-CR135]

Identifying the Rare Etiology: Myocarditis in a Younger Patient with Unexplained Total Atrioventricular Block

G. J. Batubara¹, A. C. Lubis¹, M. P. Hutasuhut¹, A. Handayani¹, M. Hutapea¹

¹Faculty of Medicine, Universitas Sumatera Utara, Indonesia, Medan

Background: Total atrioventricular block (AVB) in relatively young patients without clear underlying causes presents a diagnostic challenge. Although ischemic and degenerative causes are more prevalent, myocarditis, an underrecognized cause of AVB, remains a diagnostic blind spot. This case highlights the importance of endomyocardial biopsy (EMB) in uncovering unexpected etiologies of unexplained conduction disorders.

Case Illustration: A 55-year-old woman presented with recurrent episodes of syncope and generalized tonic-clonic seizures. Her initial evaluation revealed symptomatic bradycardia, which was confirmed by an electrocardiogram (ECG) showing complete AVB. A temporary pacemaker (TPM) was inserted to manage symptomatic bradycardia. Further ECG analysis raised suspicion of long QT syndrome, indicated by a Schwartz score of 5.5 and a history of non-sustained polymorphic ventricular tachycardia (VT), suggesting an underlying arrhythmogenic condition. Her medical history included hypertension, but no prior cardiac disease, diabetes, or smoking. Laboratory findings were unremarkable, with normal troponin I (0.02 ng/mL) and glucose (98 mg/dL) levels, excluding myocardial infarction and hypoglycemia. Electrolytes (Na: 151 mEq/L, K: 3.4 mEq/L), renal function (Ur: 55 mg/dL, Cr: 0.84 mg/dL), and acid-base balance (pH: 7.43, pCO₂:39.7, pO₂:96.5) were within normal ranges, excluding metabolic causes of the conduction disturbance. Echocardiography revealed mildly reduced left ventricular ejection fraction (LVEF: 40%), concentric left ventricular hypertrophy (LVEDD: 40 mm; LVEDV: 86 ml), and regional wall motion abnormalities, but no valvular or structural heart disease was evident. Coronary angiography revealed normal coronary arteries, excluding ischemic heart disease as the cause of the conduction block. The patient subsequently underwent permanent pacemaker implantation; however, the underlying cause remained unclear. Because typical underlying causes were identified, the patient underwent EMB. Histopathological analysis revealed myocardial fiber destruction, stromal edema, and eosinophilic amorphous material consistent with myocarditis. The diagnosis of myocarditis was thus confirmed.

Conclusion: This case highlights the importance of EMB in diagnosing high-degree AVB when the underlying cause is unclear, particularly in patients without apparent common etiologies and risk factors. Although myocarditis is rare, it should be considered a reversible and treatable cause of conduction disturbances, particularly in younger patients with atypical features.

Keywords: Myocarditis, Atrioventricular Block, Endomyocardial Biopsy

[12INAHRS-CR136]

Symptomatic Bradycardia with Seizure-like Episode Due to Sinus Node Dysfunction: A Case Requiring Urgent Temporary Cardiac Pacing

G. Christalitha¹, A. Rizal²

¹Clinical Student in the Faculty of Medicine, Brawijaya University, Malang

²Arrhythmia Division, Department of Cardiology, Faculty of Medicine, Brawijaya University, Saiful Anwar General Hospital, Malang

Background: Symptomatic bradycardia is a critical manifestation of sinus node dysfunction (SND) and often presents with syncope, dizziness, or fatigue. In rare cases, transient cerebral hypoperfusion can induce seizure-like activity, complicating the diagnostic process. Prompt recognition and timely pacing are essential to prevent morbidity and guide long-term management.

Case Presentation: A 64-year-old man with type 2 diabetes mellitus and a long history of active smoking presented with recurrent dizziness and a sudden episode of seizure-like activity. Pre-referral electrocardiogram (ECG) revealed sinus bradycardia at 30 beats per minute, unresponsive to atropine alone, and requiring dopamine infusion. Upon admission to our center, the patient remained symptomatic with documented sinus pauses of up to 2.8 seconds. Serial ECG and Holter monitoring confirmed significant sinus node dysfunction. Echocardiography revealed concentric left ventricular hypertrophy with preserved systolic function. Given the persistence of bradycardia and high risk of recurrent cerebral hypoperfusion, a temporary pacemaker (TPM) was inserted. Following stabilization, the patient was scheduled for permanent pacemaker (PPM) implantation.

Discussion: This case underscores the electrophysiological challenge of diagnosing symptomatic bradycardia when seizure-like episodes obscure the initial presentation. In elderly patients with metabolic comorbidities, such as diabetes mellitus, progressive SND may lead to high-grade sinus pauses with hemodynamic compromise. The decision to proceed with TPM was guided by clinical instability and electrocardiographic evidence of pause-dependent symptoms, which aligns with current recommendations for pacing in unstable bradyarrhythmias.

Conclusion: This case underscores the electrophysiological challenge of diagnosing symptomatic bradycardia when seizure-like episodes obscure the initial presentation. In elderly patients with metabolic comorbidities such as diabetes mellitus, progressive SND may lead to high-grade sinus pauses with hemodynamic compromise. The decision to proceed with TPM was guided by clinical instability and electrocardiographic evidence of pause-dependent symptoms, aligning with current recommendations for pacing in unstable bradyarrhythmias.

Keywords: Symptomatic Bradycardia, Sinus Node Dysfunction, Temporary Pacemaker

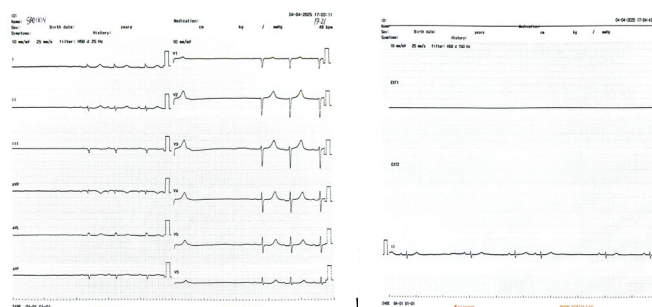


Figure 1. Electrocardiographic findings showed (Left) sinus bradycardia at 48 bpm with occasional premature atrial contractions (PACs); no ischemic changes are noted. (Right) A subsequent rhythm strip reveals a prolonged sinus pause exceeding 3 seconds, consistent with significant sinus node dysfunction and correlating clinically with transient loss of consciousness. These findings supported the indication for temporary pacing.

[12INAHRS-CR137]

**Unmasking Parahisian Accessory Pathway in Short PR interval without Delta Wave:
A Case Report**

C. U. Ayunindya¹, H. Lim^{1,2}, S. Salim³, R. Sukardi³, A. A. Lukito^{1,2}

¹Siloam Hospital Lippo Village, Tangerang, Indonesia

²Department of Cardiology and Vascular Medicine, Faculty of Medicine, Universitas Pelita Harapan,
Tangerang, Indonesia

³Dr Cipto Mangunkusumo General Hospital, Jakarta, Indonesia

Background: A short PR interval on electrocardiogram (ECG) suggests accelerated atrioventricular (AV) conduction and may indicate the presence of an accessory pathway. The most recognized cause is Wolff-Parkinson-White (WPW) syndrome, characterized by a short PR interval, delta wave, and widened QRS complex due to early ventricular activation. Other causes include enhanced AV nodal conduction, junctional rhythms, and atypical accessory pathways (nodofascicular, nodoventricular, or fasciculoventricular tracts). In rare cases, a concealed or parahisian accessory pathway may conduct rapidly without producing delta waves, mimicking WPW but with a normal QRS complex.

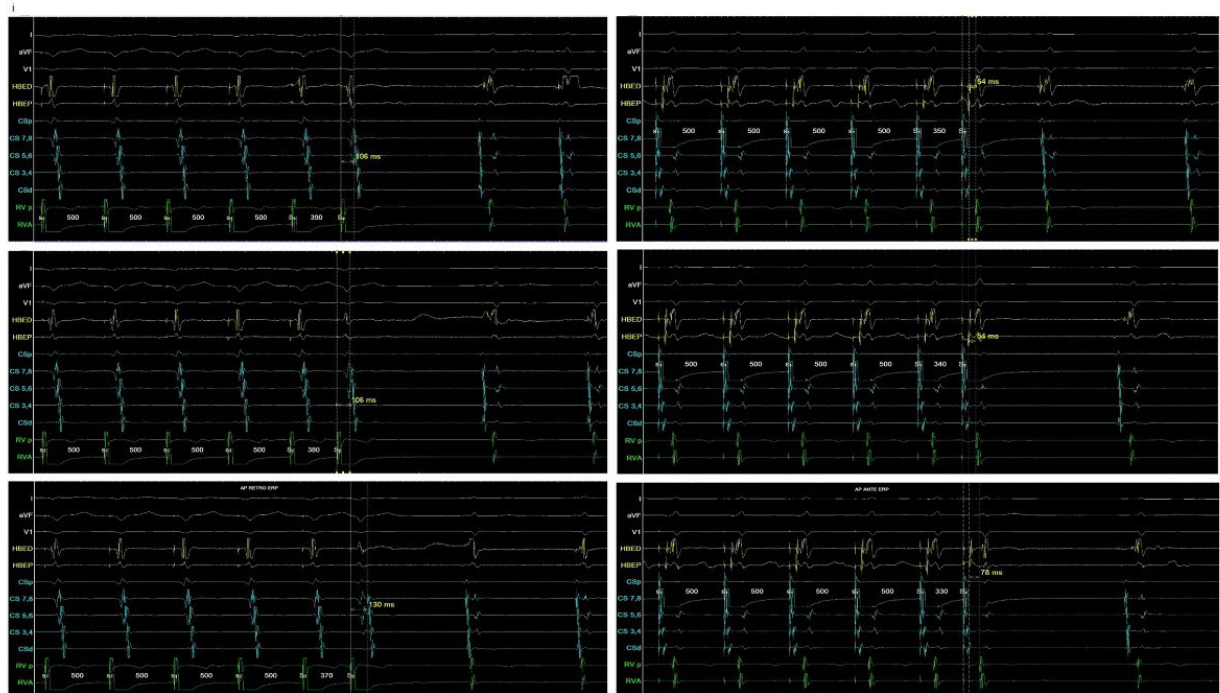
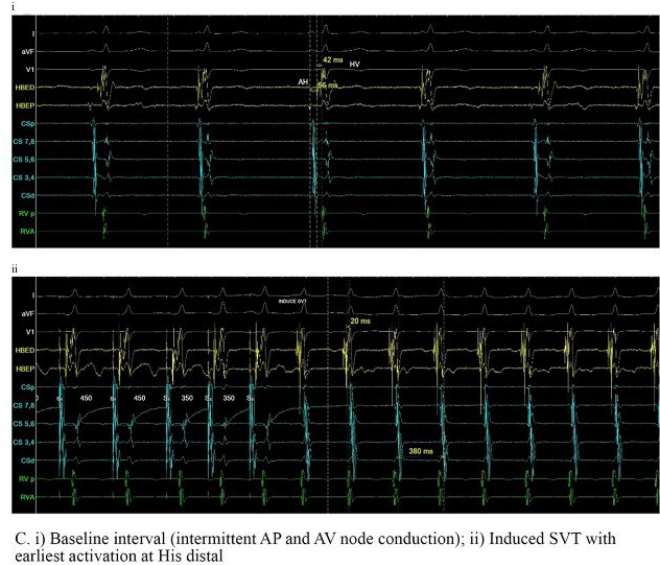
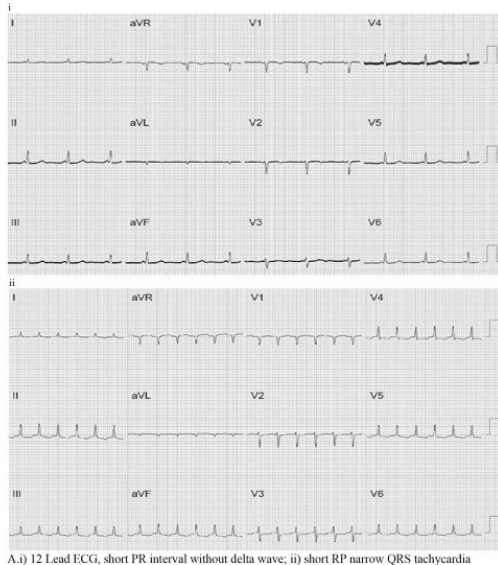
Case Illustration:

A 39-year-old woman presented with recurrent palpitations. ECG revealed a sinus rhythm and a short PR interval without a delta wave. Electrophysiology study (EPS) induced short RP supraventricular tachycardia (SVT) during catheter insertion (Fig. 1A). Extrastimuli pacing confirmed retrograde and antegrade conduction via a non-decremental accessory pathway (AP) (Fig. 1B). Atrial extrastimuli pacing induced non-sustained SVT with concentric activation earliest at His distal with a short VA (20ms) (Fig. Ci). Following intravenous atropine, atrioventricular nodal (AVN) conduction was enhanced and alternated with AP conduction, but no tachycardia could be induced. Considering the parahisian AP and non-sustained tachycardia, ablation was deferred.

Catheter ablation of parahisian AP poses a challenge because of their proximity to the AVN and His bundle, increasing the likelihood of iatrogenic complete AV block². In this case, retrograde atrial activation in the distal His region indicated a right-sided parahisian AP. Despite the standard target being the right septal (RS) area, this critical location significantly increases the risk of permanent AV block. The alternating AVN and AP conduction after atropine further suggested a close spatial overlap. If intervention becomes necessary, safer strategies, such as cryoablation or the noncoronary cusp (NCC) approach, may be considered. The NCC approach has been shown to reduce complication rates compared to RS ablation and can produce transmural atrial lesions without affecting the conduction system, thus making it a safer option in cases where RS ablation carries unacceptable risk³

Conclusion: A short PR interval without a delta wave should prompt an evaluation beyond the diagnosis of classic WPW syndrome. Although rare, parahisian accessory pathways can mimic pre-excitation and require EPS for accurate diagnosis. Given the high risk of AV block with catheter ablation in the parahisian region, an individualized risk-benefit assessment is essential before proceeding with invasive intervention.

Keywords: Parahisian accessory pathway, Wolff-Parkinson-White syndrome, Catheter ablation, Short PR interval



B. i) Retrograde AP conduction (non-decremental). ii) Antegrade AP Conduction (non-decremental)

[12INAHRS-CR138]

Sinus Node Dysfunction Presenting with Tachy-Brady Syndrome in a Patient with Inferior-Posterior ST-Elevation Myocardial Infarction: A Case Report

A. Hakim¹, R. W. Ananto¹, B. A. Pramono²

¹General Practitioner at Rumah Sakit Universitas Islam Indonesia, Yogyakarta, Indonesia

²Cardiologist at Rumah Sakit Universitas Islam Indonesia, Yogyakarta, Indonesia

Background: Sinus node dysfunction (SND), including tachy-brady syndrome, is a rare but clinically significant arrhythmic complication of acute myocardial infarction (AMI), particularly inferior-posterior ST-elevation myocardial infarction (STEMI). Tachy-brady syndrome is characterized by bradycardia alternating with paroxysmal supraventricular arrhythmia, most frequently atrial fibrillation (Afib). Ischemia of the right coronary artery may impair sinoatrial node perfusion, leading to transient or permanent conduction abnormalities. Bradyarrhythmia in AMI may worsen clinical outcomes and complicate therapeutic strategies.

Case Illustration: A 71-year-old man presented to the emergency department with retrosternal chest pain that had started 3 days prior to admission. The pain was severe, radiating to the back, and was accompanied by diaphoresis. patients' medical history was unknown due to infrequent medical visits, but they were suspected to have diabetes mellitus and dyslipidemia. The vital signs and hemodynamics were stable. Physical examination revealed mild rales and leg edema. The initial 12-lead ECG revealed paroxysmal Afib with a normal ventricular response, ST-segment elevation in leads II, III, and aVF, and reciprocal ST-segment depression in I and aVL. Horizontal ST-segment depression with upright T wave in anterior leads was also observed, suggesting reciprocal changes of posterior infarction. Troponin I levels were also elevated. The patient was diagnosed with inferior-posterior STEMI with Killip class II. The patient was admitted to the HCU and initiated on anticoagulants, dual antiplatelet therapy, a beta-blocker, an ACE inhibitor, and a statin. During hospitalization, continuous ECG monitoring on lead II showed sinus bradycardia with episodes of sinus pause lasting 2–3 seconds, followed by paroxysmal Afib with rapid ventricular response. Sinus node dysfunction with tachy-bradycardia syndrome was suspected. The patient was referred to a tertiary hospital for percutaneous coronary intervention and underwent VVI-R pacemaker implantation.

Conclusion: This case highlights the rare occurrence of sinus node dysfunction presenting with tachy-brady syndrome in the setting of inferior-posterior STEMI. Early identification and appropriate intervention, which frequently require permanent pacemaker implantation, are essential to reduce the risk of complications and improve the patient outcomes.

Keywords: Tachy-brady syndrome, sinus node dysfunction, inferior-posterior STEMI, bradyarrhythmia, myocardial infarction

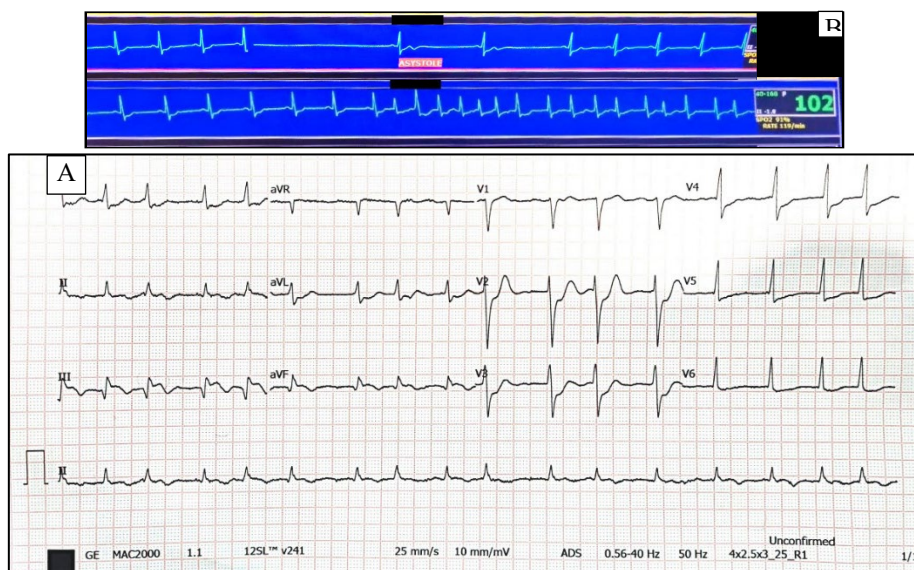


Figure 1. (A) Initial 12-lead ECG, (B) Continuous ECG monitoring on lead II showing sinus bradycardia with sinus pause followed by supraventricular tachyarrhythmia (Afib).

[12INAHRS-CR139]

An Unanticipated Episode of Paroxysmal Supraventricular Tachycardia in an Elderly Woman with No Cardiac History: A Case Report from a Rural Emergency Department

A.Aisy^{1,4}, Y. Hanalena^{2,4}, N.Andini^{2,4}, C. R. Masharto^{3,4}

¹ Bima District Hospital, Bima, Indonesia

² Sering Healthcare Center, Medan, Indonesia

³ Montong Healthcare Center, Tuban, Indonesia

⁴ Faculty of Medicine, Universitas Sumatera Utara, Medan, Indonesia

Background: Paroxysmal supraventricular tachycardia (SVT) is a common arrhythmia that is typically observed in younger individuals. In elderly patients without prior cardiac disease, SVT is less frequently suspected, particularly when the symptoms are nonspecific. Early recognition and appropriate management are essential to prevent such complications. However, in rural emergency departments, limited access to standard antiarrhythmic medications can pose a challenge in managing such cases.

Case Illustration: A 58-year-old female patient was admitted to the Emergency Department with complaints of palpitations, shortness of breath, and extreme fatigue of a day's duration. The patient denied any symptoms of chest pain or syncope. The patient had no history of hypertension or cardiovascular disease. Physical examination revealed a rapid apical heart rate, making it difficult to count, and a regular radial pulse. His blood pressure was 150/100 mmHg, and oxygen saturation on room air was 95%. Electrocardiography (ECG) revealed a narrow QRS complex with tachycardia at 209 bpm, consistent with paroxysmal supraventricular tachycardia (SVT). Echocardiography was not performed, and laboratory investigations were unremarkable. Carotid sinus massage and the Valsalva maneuver were attempted without success. Adenosine was administered, but it was unavailable at the hospital. As an alternative, we administered a calcium channel blocker (diltiazem) and a beta blocker (bisoprolol) as acute treatments to reduce the heart rate and digoxin to help prevent further SVT episodes. Continuous monitoring of the patient's heart rhythm and blood pressure was performed to anticipate potential excessive heart slowing from the combination therapy. The patient's heart rate dropped to 75 bpm, indicating a positive response to the treatment.

Conclusion: This case highlights the need to consider SVT in elderly patients presenting with nonspecific symptoms, such as fatigue, even in the absence of a cardiac history. This also underscores the diagnostic and therapeutic challenges encountered in rural settings. In resource-constrained environments, when standard treatments are unavailable, a combination of antiarrhythmic drugs can be considered under strict medical supervision and careful monitoring.

Keywords: *Supraventricular tachycardia, elderly, diltiazem, bisoprolol, rural setting*

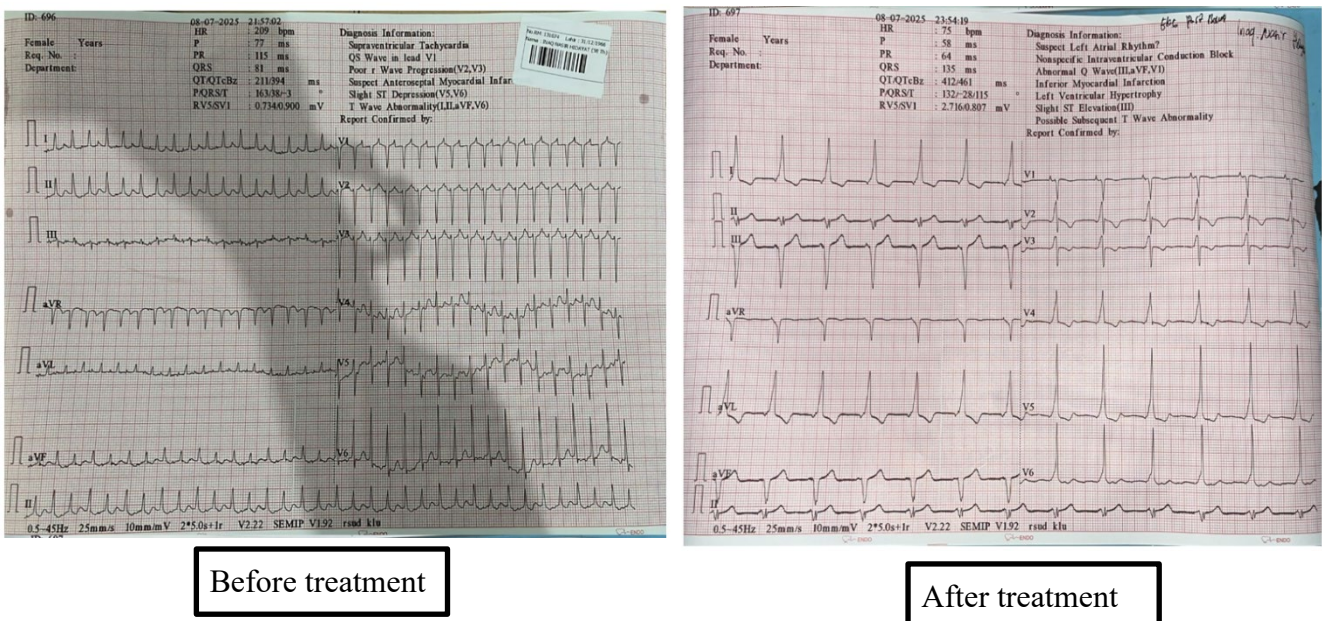


Figure 1. ECG findings of supraventricular tachycardia (SVT) in the patient

[12INAHRS-CR140]

The Complexity of Incessant Idiopathic Left Ventricular Tachycardia Management

K. Alifah¹, Irnizarifka^{1,2}, A. Pramudya³, H.A. Aditya^{1,2}, Azmanuddin^{1,2}

¹Universitas Sebelas Maret Hospital, Sukoharjo, Indonesia

²Division of Arrhythmia, Cardiac Pacing, and Heart Failure, Department of Cardiology and Vascular Medicine, Universitas Sebelas Maret Hospital, Sukoharjo, Indonesia

³Hasna Medika Cirebon Hospital, Cirebon, Indonesia

Background: Purkinje system-originating ventricular tachycardia (VT) is the most common type of idiopathic left ventricular tachycardia (ILVT) and is characterized by RBBB morphology and LAD. It occurs predominantly in young males (15-40 years old), with left posterior fascicular VT being the most common form (90% of cases). Despite the challenges associated with ablation, ILVT is typically terminated by verapamil administration. This case report demonstrates the complexity of incessant ILVT management.

Case Illustration: A 16-year-old boy was admitted to the ED due to recurrent palpitations. Vital signs showed a BP of 96/76 mmHg, HR of 119 bpm, and SpO₂ of 95%, without signs of hemodynamic deterioration. Posterior fascicular ILVT was observed on the surface ECG. Emergency 2D ablation was performed due to unsuccessful verapamil administration, anti-tachycardia pacing, and cardioversion. Electrophysiological studies showed fused P1-P2 at DD 56 (posterior fascicle exit). Despite multiple RFAs, accelerated VT was evinced with termination of VT, and aggressive pacing from the RVA re-induced the ILVT. 3D ablation was considered because incessant ILVT still occurred. 3D ablation was conducted with 3D mapping (Ensite Precision system) during ILVT, showing the posteroseptal fascicle as the focus area with fused P1-P2. Multiple RFAs were successfully performed distal to the mid-posteroseptal fascicle, and ILVT was terminated. Aggressive pacing from HRA, RVA, and LV did not reinduce the ILVT. After 3 months, no recurrent palpitations were observed.

Conclusion: Although in most cases, ILVT can be terminated with verapamil, we faced a case that was refractory to medication, anti-tachycardia pacing, cardioversion, and 2D ablation. 3D Ablation in ILVT plays an essential role in creating precision mapping as the target of ablation.

Keywords: idiopathic left ventricular tachycardia, incessant ILVT, 3D ablation

[12INAHRS-CR141]

When the Brain Slows the Heart: A Case of Neurogenic Paroxysmal AV Block in Subdural Hemorrhage

M.R.S. Devinta¹, M.S. Dharmasuari¹, I.G.N.A.D.A. Putra¹, I.G.A.B.K. Jayantika¹

¹Department of Cardiology and Vascular Medicine, Bali Mandara Regional General Hospital, Denpasar, Indonesia

Background: Atrioventricular (AV) block is typically associated with intrinsic cardiac abnormalities. However, neurogenic causes are increasingly recognized, particularly in the context of acute brain injuries, such as subdural hemorrhage (SDH). This case highlights the interplay between intracranial pathologies and cardiac conduction disturbances.

Case Presentation: A 76-year-old woman was admitted to our hospital unconscious after a fall. Initial assessment revealed a parieto-occipital subdural hemorrhage (SDH) on cranial computed tomography (CT) imaging and sinus rhythm with premature ventricular complexes (PVCs) on electrocardiogram (ECG). Within 24 hours of ICU admission, the patient developed third-degree atrioventricular (AV) block in the absence of cardiac ischemia. Intravenous dopamine (2–10 mcg/kg/min) was administered as a bridging treatment and successfully restored 1:1 conduction within 48 hours, with a subsequent ECG showing sinus rhythm, supporting a neurogenic etiology. Despite cardiovascular stabilization, the patient progressed to brain death, rendering surgical intervention unviable.

Conclusion: This case underscores the critical role of the neurocardiac axis in SDH-associated AV block, where dopamine-responsive autonomic dysfunction reverses conduction abnormalities without structural cardiac pathology. Early identification and appropriate pharmacological support may reverse arrhythmia and prevent unnecessary invasive procedures.

Keywords: Neurogenic AV block, subdural hemorrhage, neurocardiac axis

[12INAHRS-CR142]

Weighing the Risks of Chemotherapy-Induced Cardiomyopathy: When to Prioritize Cancer Treatment Over Cardiac Health

A. Liong,¹ S.A.N.Y. Sutarmini²

¹*Intern of Cardiology and Vascular Medicine, Bali Mandara Regional Public Hospital, Indonesia*

²*Department of Cardiology and Vascular Medicine, Bali Mandara Regional Public Hospital, Indonesia*

Background: Chemotherapy remains a key cancer treatment; however, its potential for cardiotoxicity, particularly chemotherapy-induced cardiomyopathy, limits its use. This condition may begin asymptotically but can progress to heart failure (HF). Diagnosis is challenging because of the overlapping symptoms of chemotherapy side effects. Noninvasive tools, such as echocardiography, MUGA scans, CT, MRI, and biomarkers, help monitor cardiac function. CICM has a poor prognosis and can disrupt or limit cancer treatment, thereby impacting survival rates. Early detection and cardioprotective therapy are critical for preventing these complications.

Case Illustration: A 67-year-old female patient visited the cardiology clinic for a planned pre-chemotherapy echocardiography screening. The patient had no complaints, and the echocardiographic results were normal, with an ejection fraction (EF) of 70.5%. The patient had no prior history of heart disease and was not on regular medication. Her vital signs were normal.

During subsequent routine examinations, the results remained good. However, at the third examination, the patient complained of fatigue, shortness of breath, and swelling in both legs. Echocardiography showed a significant decrease in left heart function, with an EF of 28.8%. The symptoms had been present for the past 1–2 months but worsened over the last two weeks. The patient was administered diuretic therapy to relieve shortness of breath and leg edema.

Conclusion: Chemotherapy-induced cardiomyopathy (CICM) is a serious complication that limits the effectiveness of cancer treatment. It may initially be asymptomatic but can progress to heart failure, with symptoms often overlapping with the side effects of chemotherapy. A 67-year-old woman with normal baseline cardiac function (EF: 70.5%) developed fatigue, dyspnea, and edema after several chemotherapy cycles and was later found to have reduced EF (28.8%). She had received anthracycline-based therapy, which is known for dose-dependent cardiotoxicity. The risk factors included advanced age, female sex, and cumulative dose. Echocardiography was the key to diagnosis. CICM management requires early detection, dose monitoring, and cardioprotective agents if indicated. Without close follow-up, CICM can lead to treatment interruption and increased mortality

Keywords: Chemotherapy-induced cardiomyopathy, Cardiotoxicity, Chemotherapy

[12INAHRS-CR143]

A Rare Case Study: A Multiple Myxomas Involving Both Right and Left Ventricles in a Neonate

A. Liong¹, S.A.N.Y. Sutarmini²

¹*Intern of Cardiology and Vascular Medicine, Bali Mandara Regional Public Hospital, Indonesia*

²*Department of Cardiology and Vascular Medicine, Bali Mandara Regional Public Hospital, Indonesia*

Background: Cardiac myxomas are rare, with multiple myxomas being even rarer (0.001%–0.03% incidence). They primarily arise in the left atrium (75 %) and can be found at the mitral annulus or the fossa ovalis border of the interatrial septum, with 20% in the right atrium and the remaining 5% originating from the atria and ventricle stem. With less than 5% of the incidence rate originating from one of the ventricles, and some studies concluding that it might be less than 2.5%, multiple myxomas originating from the left and right ventricles without any atrium involvement are exceedingly rare. Myxomas are mostly benign, and advances in imaging have made them manageable. This report discusses a case of a neonate with multiple myxomas in both ventricles but without Carney complex.

Case Illustration: A 29-week preterm neonate, post-Cesarean section, was admitted to the NICU with signs of pneumonia. Routine echocardiography revealed multiple masses in both ventricles. Multiple mass was visible in the right ventricle: I: 1.49 x 1.04 cm, II: 0.3 x 0.32 cm, III: 0.5 x 0.3 cm, IV: 0.3x0.49 cm, V: 0.4 x 0.47 cm, in the left ventricle: I: 0.7 x 0.4 cm, II: 0.2 x 0.2 cm, III: 0.5 x 0.4 cm. Despite these findings, the neonate showed no significant symptoms except mild tachypnea and chest retraction, which improved with CPAP. There was no family history of myxomas or congenital heart disease.

Conclusion: Cardiac myxomas are rare tumors with an incidence of 0.001% to 0.03%, typically affecting the left atrium, whereas multiple myxomas involving both ventricles are exceedingly uncommon. This case describes a premature neonate (29 weeks) diagnosed with multiple myxomas in both the left and right ventricles through echocardiography, exhibiting mild respiratory distress that improved with CPAP. Despite the presence of tumors, there were no significant symptoms, and the patient had no family history of myxomas or congenital heart disease. Surgical resection is the standard treatment, with a low mortality rate (<5%) and favorable recovery. Early detection through imaging and surgical intervention is crucial for optimal outcomes.

Keywords: Cardiac tumor, myxoma, multiple myxomas, left ventricular myxoma, right ventricular myxoma, echocardiography

[12INAHRS-CR144]

Conquering Typical Atrioventricular Nodal Re-Entrant Tachycardia: The Left Inferior Extension Slow Pathway Ablation Breakthrough

K. Alifah¹, Irnizarifka^{1,2}, H.A. Aditya^{1,2}, Azmanuddin^{1,2}

¹Universitas Sebelas Maret Hospital, Sukoharjo, Indonesia

²Division of Arrhythmia, Cardiac Pacing, and Heart Failure, Department of Cardiology and Vascular Medicine, Universitas Sebelas Maret Hospital, Sukoharjo, Indonesia

Background: Atrioventricular nodal re-entrant tachycardia (AVNRT) refers to re-entry in the area of the atrioventricular (AV) node, and it is the most common tachyarrhythmia. Typically, AVNRT involves a slow pathway for antegrade conduction and a fast pathway for retrograde conduction. Catheter ablation has high success and low complication rates; therefore, it is the treatment of choice for AVNRT. In most cases, slow pathway ablation targeted the inferior aspect of the triangle of Koch. However, the left-sided inferior nodal extension may be a critical slow pathway in some cases. This case report presents the success of left inferior extension slow pathway ablation for typical AVNRT.

Case Illustration: A 54-year-old woman was referred to our hospital from another hospital due to palpitations and near syncope. The Holter monitor from the previous hospital showed sinus rhythm with an episode of pre-excitation syndrome with infrequent unifocal PVCs (burden <1%) and infrequent PACs (burden <1%). Echocardiography showed an EF of 56% with global normokinetic. An electrophysiological study was performed with aggressive atrial stimulation, demonstrating an AH jump and inducible sustained short RP NCT (PPI 512 ms, TCL 352 ms, VA 12 ms). Normal SA and AV node function, with inducible typical slow-fast AVNRT, were observed on EPS. After re-induction of SVT, there was evidence of the earliest retrograde A at CS56 (left inferior extension/LIE pathway). RFA using a non-irrigating catheter was delivered on the roof of the CS OS during sinus rhythm and atrial pacing, junctional rhythm was evinced, and there was unfortunate AV Block 2-2 and sinus arrest. Atropine sulfate and dexamethasone were administered, and the patient was converted to sinus rhythm. Aggressive atrial stimulation did not induce AH jump or echo beat, and AVNRT was not inducible. Successful LIE slow pathway ablation was performed, and there was no recurrent tachyarrhythmia.

Conclusion: Precision mapping is crucial for achieving ablation targets, particularly in AVNRT. In this case, LIE slow pathway ablation may be an important target for AVNRT termination.

Keywords: typical atrioventricular nodal re-entrant tachycardia, left inferior extension slow pathway, ablation

[12INAHRS-CR145]

Misplaced ECG Leads Causing False Diagnosis of Ventricular Arrhythmia in a Young Air Force Pilot: A Diagnostic Pitfall

R. Maulana¹, H. Puspitaningrum¹, F. Erick¹, D. Siagian¹, D. D. Deria¹, R. R. E. Kristineke¹, N. A. Tafriend², Haikal³, A. Harsoyo³

¹General Practitioner, Arrhythmia Unit, Department of Cardiology and Vascular Medicine, Gatot Soebroto Army Central Hospital, Jakarta, Indonesia

²Cardiologist, Department of Cardiology and Vascular Medicine, Gatot Soebroto Army Central Hospital, Jakarta, Indonesia

³Arrhythmia Subspecialist, Department of Cardiology and Vascular Medicine, Gatot Soebroto Army Central Hospital, Jakarta, Indonesia

Background: Inaccurate electrocardiogram (ECG) lead placement and anatomical variations can lead to misinterpretation. Morphological changes may occur when precordial leads are displaced by more than 2 cm. Understanding these variations is essential to prevent misdiagnosis.

Case Illustration: A 24-year-old Air Force pilot was referred with a diagnosis of premature ventricular contraction, reported occasional palpitations, sometimes unnoticed, and had a history of fainting. There is no historical classic of coronary disease. Physical examination: irregular heart sound. Laboratorium is still within the normal limit. Electrocardiogram (1) showed: Sinus rhythm, normoaxis, HR: 60 bpm, Premature ventricular contraction from TV Septum dd Parahisian with 2 cycle length full compensatory pause. Electrocardiogram (2) showed: Sinus rhythm, normoaxis, HR: 72, PVCs from the TV free wall. Treadmill test: Sinus rhythm with PVCs (only resting stage). Holter monitoring: First-degree AV block, frequent PVCs (Bigeminy burden 8%) from the TV-free wall. Echocardiography: normal, systolic function EF: 64%, global normokinetic, thrombus (-).

Discussion: ECG lead misplacement can result in apparent abnormalities, such as ectopic rhythms, conduction defects, or signs suggestive of myocardial ischemia, potentially leading to misdiagnosis and inappropriate interventions. In aviation medicine, such errors may have serious occupational consequences, particularly for Air Force pilots. In this case, Intracardiac Echocardiography (ICE) identified the PVC focus approximately 4 mm close to the HIS bundle (PARAHISIAN). Because of the high risk of complete AV block, catheter ablation was contraindicated. However, the patient declined the procedure after risk counseling. Differentiating NF-His from far-field His activations enabled high ablation success without atrioventricular block in para-Hisian accessory pathway patients. According to Xue et al. (2017), parahisian ablation can be performed safely using an irrigated catheter at a mean depth of 5.7 ± 1.2 mm, with 25 W of power, a 17 mL/min flow rate, and a 60-second duration, achieving good outcomes without AV block. However, each case requires an individualized risk assessment. The patient will be clinically monitored and undergo Holter monitoring at 1 and 6 months.

Conclusion: Improper placement of ECG leads can have serious consequences, leading to misdiagnosis and inappropriate treatment.

Keywords: ECG lead misplacement, Premature Ventricular Complex, Ventricular Arrhythmia, Electrophysiology Study, Catheter 3D ablation

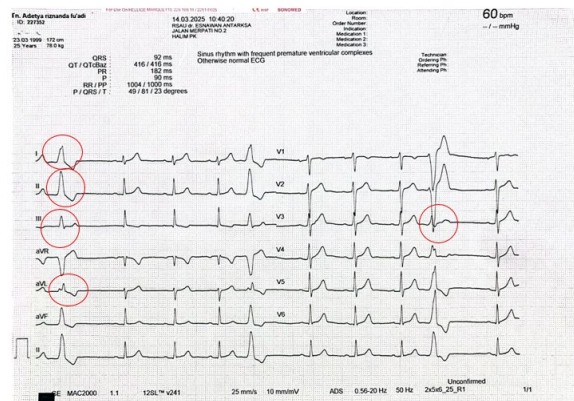


Figure 1. ECG from hospital (1): SR, NORMOAXIS, HR: 60, PVCs from TV Septum dd Parahisian.

[12INAHRS-CR146]

From Defect Occlusion to Electrophysiologic Complication : A Case of Double Edged 'Blocking'

M.J.N. Nasution¹, A. N. Nasution¹, A.C.Lubis¹, C. A. Andra¹

¹Departement of Cardiology and Vascular Medicine, Faculty of Medicine, University of North Sumatera, Medan, Indonesia

Background: A perimembranous ventricular septal defect (VSD) is a common congenital heart anomaly that may require intervention when associated with significant left-to-right shunting or left ventricular volume overload. Transcatheter closure using the Amplatzer VSD Occluder (AMVO) offers a less invasive alternative to surgical repair but carries potential complications, notably cardiac arrhythmia.

Case Illustration: A 40-year-old man presented with dyspnea and fatigue. Echocardiography revealed an 8 mm perimembranous VSD with left atrial and left ventricular dilation. The patient also had comorbid hypertension and chronic kidney disease. Transcatheter VSD closure was performed under transesophageal echocardiography (TEE) guidance using MFO device no. 14-12. During the procedure, the patient developed supraventricular tachycardia, which reverted to sinus rhythm after intravenous administration of amiodarone. On the first postoperative day, the patient developed a high-degree atrioventricular (AV) block with AV dissociation, likely due to device-induced septal inflammation. Intravenous methylprednisolone was then administered. The patient was stabilized but continued to exhibit an accelerated junctional rhythm. He was discharged in stable condition with plans for close outpatient follow-up for rhythm monitoring and further evaluations.

Conclusion: Transcatheter closure of perimembranous VSD using AMVO is technically feasible and less invasive, especially in adults with a high surgical risk. However, conduction disturbances, such as AV block, remain significant complications, possibly due to the proximity of the conduction system to the device. Careful patient selection, optimal implantation devices and techniques, and diligent post-procedure monitoring are critical for minimizing adverse events and ensuring favorable outcomes.

Keywords: Ventricular Septal Defect, Amplatzer VSD Occluder, Arrhythmia, Transcatheter Closure, AV Block

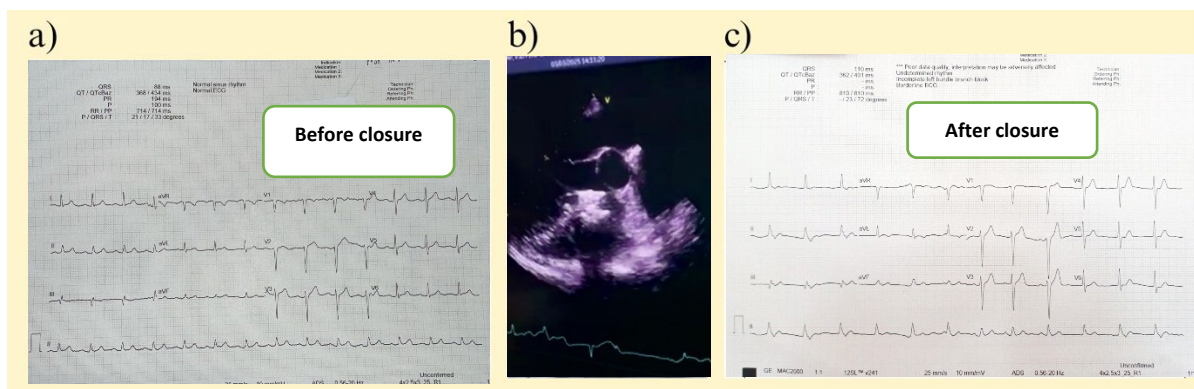


Figure 1. a) ECG before device closure, showing normal sinus rhythm. b) Transesophageal echocardiography showing a well-seated VSD device. c) ECG after the procedure showing an accelerated junctional rhythm with a rate of 74 ventricular beats per minute.

[12INAHRS-CR147]

BRASH Syndrome: A Spectrum of Severity and Management Approaches in Two Elderly Patients

H. Sania¹, L. Murtiningsih¹.

¹*Premier Surabaya Hospital, Surabaya, Indonesia*

Background: BRASH syndrome is an overlooked clinical condition involving the interplay between bradycardia, renal failure, AV-nodal blockade, shock or hypotension, and hyperkalemia. This is a result of the synergistic effect of AV nodal blockers and renal dysfunction. This syndrome presents with asymptomatic bradycardia and cardiogenic shock.

Case Illustration:

We report two patients with BRASH syndrome with distinct therapeutic outcomes.

Case 1: A 72-year-old man with a history of hypertension and end-stage renal disease on regular hemodialysis presented with generalized weakness. He had taken nebivolol, amlodipine, valsartan, and nifedipine the previous evening. He was bradycardic at 28 beats per minute. ECG showed sinus arrest with a junctional escape rhythm. Laboratory tests revealed hyperkalemia (7.8 mmol/L), hyponatremia (129 mmol/L), and elevated serum creatinine levels (5.74 mg/dL). After the administration of intravenous atropine and urgent hemodialysis, the rhythm normalized to sinus tachycardia (121 bpm) with correction of electrolyte abnormalities. The patient was discharged in a stable condition.

Case 2: A 67-year-old woman with a history of diabetes, hypertension, and stage 4–5 chronic kidney disease presented with acute onset of lower limb weakness after inadvertently taking a double dose of bisoprolol and amlodipine. She was hemodynamically unstable (heart rate of 33–38 bpm and blood pressure of 98/54 mmHg). ECG revealed sinus arrest with a junctional rhythm. Laboratory results confirmed severe hyperkalemia (8.0 mmol/L) and elevated serum creatinine levels (3.8 mg/dL). She was treated with intravenous atropine and dopamine, and aggressive management of hyperkalemia. Despite aggressive hyperkalemia management, persistent bradycardia, fluctuating mental status, and signs of cerebral hypoperfusion necessitated the use of a temporary transvenous pacemaker. Pacing and hyperkalemia management led to rapid clinical improvement, with subsequent normalization of renal function and potassium levels. This case underscores the critical role of cardiac pacing in managing BRASH syndrome, particularly when medical therapy is insufficient and cerebral perfusion is compromised.

Conclusion: The BRASH syndrome manifests with varying degrees of severity. While some cases are manageable with conservative treatment, others may require pacing. Recognition of this reversible syndrome is essential for guiding appropriate treatment.

Keywords: BRASH syndrome; AV-nodal blocker; hyperkalemia; chronic kidney disease; sinus arrest; temporary pacemaker

[12INAHRS-CR148]

A Child Successfully Recovered from Ventricular Tachycardia: A Rare Case Report in the Emergency Room

N. A. Byant¹, P. Yeantesa²

¹Awal Bros Panam Hospital, Pekanbaru, Indonesia

²Department of Cardiology and Vascular Medicine, Awal Bros Panam Hospital, Pekanbaru, Indonesia

Background: Arrhythmia is a rare condition in children, but it can be potentially life-threatening, particularly ventricular tachycardia (VT). The incidence is 1/100.000 in the pediatric population. This rhythm in children is defined as a group of three or more wide QRS complexes that has a beat 20-25% faster than the basal sinus rate. Reentry of impulses, triggered activity, and ectopic beats are common causes of VT. These mechanisms are caused by many factors, one of which is genetic. Cardioversion or an anti-arrhythmic agent is required to abolish this dangerous rhythm.

Case illustration: An 8-year-old girl presented to the ER with worsening palpitations for 6 h before admission. The patient was alert and did not have angina, but she had a cough with wheezing and mild fever for 1 d prior. The patient had a history of asthma. Her father had a history of VT and was being treated by a cardiologist. Physical examination showed normal vital signs except for tachycardia at 189 beats per minute, a regular rhythm, no cardiac murmur, wheezing in both lung fields, and no rales. Laboratory results showed a negative troponin I test result. Electrocardiography showed monomorphic VT, chest radiography showed no cardiomegaly, and echocardiography showed normocardiac findings.

The patient was diagnosed with stable monomorphic VT. Treatment began with oxygen administration, monitoring, and ensuring that the patient was not in an unstable condition. The patient was referred to a cardiologist. Stable VT was corrected with antiarrhythmic infusion, amiodarone intravenous; an initial dose of 150 mg was given in 10 minutes, then followed by a maintenance dose of 360 mg run out in 6 hours. Within 1 hour, palpitation was improved, rhythm became sinus, and rate decreased to around 90-100x/min.

In young individuals, inherited cardiac channelopathies are a more common cause of VT, such as catecholaminergic polymorphic VT and Brugada syndrome. Some events also trigger VT; for example, asthma and hypoxemia can disturb the electrical stability of myocardial cells. Therefore, patients must control their comorbidities.

Conclusion: Ventricular tachycardia is less common in children, but it has dangerous effects. Therefore, patients with VT require a close and rapid approach to treatment and improved risk factors to ease morbidity and mortality.

Keywords: Ventricular tachycardia, genetic factor, stable condition, antiarrhythmic infusion

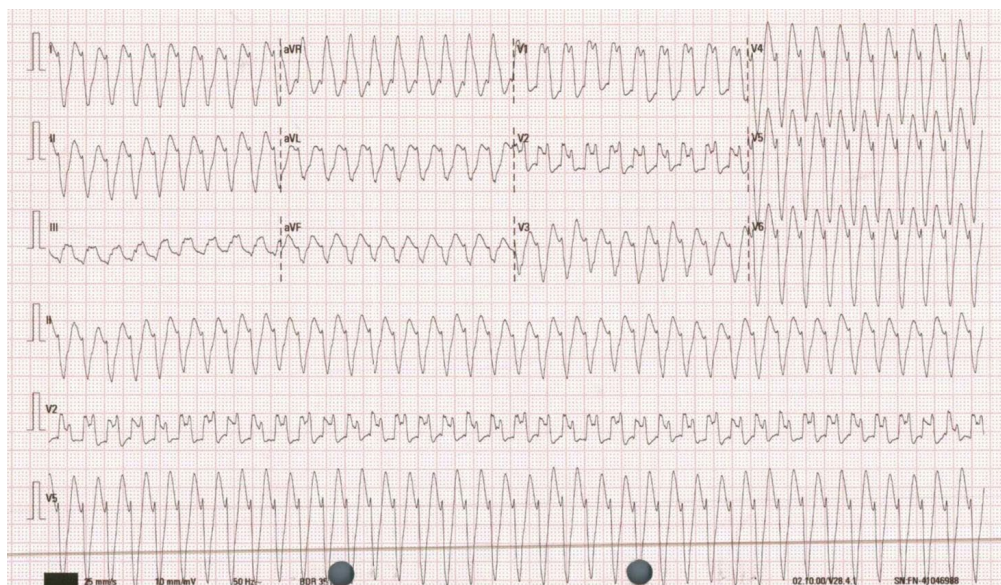


Figure 1. Monomorphic Ventricular Tachycardia.

[12INAHRS-CR149]

Multifocal Atrial Tachycardia masquerading as Paroxysmal Atrial Fibrillation: Diagnosis Pitfall Revealed During Catheter Ablation

I. Noersyid¹, H Balweel², A Harsoyo², S. B. Raharjo^{1,3}, D. Y. Hermanto^{1,3}, D. A. Hanafy^{1,3}, Y. Yuniadi^{1,3}

¹National Cardiovascular Center Harapan Kita, Jakarta, Indonesia

²Army Hospital Gatot Soebroto

³Faculty of Medicine, Universitas Indonesia, Jakarta, Indonesia

Background: Multifocal Atrial tachycardia (MAT) is an uncommon form of supraventricular tachycardia that closely resembles atrial fibrillation (AF) on surface electrocardiogram. Distinguishing between these two entities is essential because they differ significantly in their underlying mechanisms and ablation strategies. Misdiagnosis may lead to inappropriate treatment and suboptimal outcomes

Case Illustration: We report the case of a 40-year-old woman referred for PVI isolation ablation due to symptomatic paroxysmal atrial fibrillation and refractory rhythm control drugs. Holter 12-lead ECG demonstrated an irregular narrow-complex rhythm with varying P-wave morphologies and a tachycardia cycle length, which was initially interpreted as atrial fibrillation. Transthoracic echocardiography revealed normal left ventricular function and LA dimensions. During 3D mapping of the PV and LA geometry, intracardiac recordings and 3D mapping (Ensite) revealed discrete, repetitive atrial activations originating from the tricuspid annulus area and left paraseptal area, with preserved atrioventricular conduction and no evidence of fibrillatory conduction. No organized Atrial fibrillation was observed during the entire procedure

Conclusion: Radiofrequency ablation was performed at the identified focal origin, resulting in immediate termination of tachycardia and restoration of sinus rhythm. The patients remained free of arrhythmia during 10 day follow-up with no need for antiarrhythmic drugs or further intervention

Keywords: Multifocal Atrial tachycardia, Atrial fibrillation

[12INAHRS-CR150]

Pulsed-Field Ablation for Mitral Isthmus-Dependent Atrial Flutter Following Recurrent Atrial Fibrillation: A Case Report

K. Rizky¹, S. B. Raharjo^{1,2,3}, D. Y. Hermanto^{1,2}, D. A. Hanafy^{1,2,3}, Y. Yuniadi^{1,2}

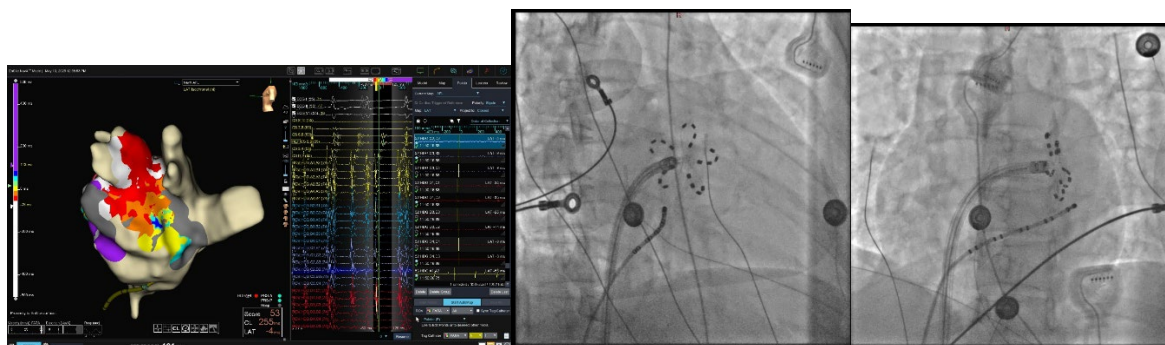¹National Cardiovascular Centre Harapan Kita, Jakarta, Indonesia; ²Faculty of Medicine, Universitas Indonesia, Jakarta, Indonesia; ³Heartology Cardiovascular Hospital, Jakarta, Indonesia

Background: Pulsed-field ablation (PFA) is an emerging technique for treating atrial fibrillation (AF). Utilizing nonthermal electroporation, PFA selectively targets myocardial tissue while preserving adjacent structures, such as the esophagus, phrenic nerve, and coronary arteries. Despite its favorable safety profile, PFA has been associated with coronary artery spasm (CAS), particularly when applied near the coronary vasculature, such as the mitral isthmus (MI) or cavotricuspid isthmus (CTI).

Case Presentation: A 46-year-old woman with paroxysmal AF presented with recurrence following two prior pulmonary vein isolation (PVI) procedures. She was scheduled for repeat ablation using PFA. Voltage mapping revealed reconnection of the right and left superior pulmonary veins (RSPV and LSPV). Repeat PVI along with posterior wall isolation (posterior box) was performed using a 35 mm Farapulse catheter (Boston Scientific). An atypical atrial flutter was induced after ablation. High-density activation mapping (LAT and propagation) demonstrated a mitral-isthmus-dependent circuit. Ablation of the mitral isthmus was performed using the “flower” configuration of the Farawave catheter, with prophylactic intracoronary nitrate administration to mitigate the risk of CAS. Flutter was successfully terminated during ablation, and no complications were observed. Although the Farawave catheter was originally designed for PVI, this case demonstrates its potential utility for the ablation of non-PV substrates, including the mitral isthmus. The quality and transmuralty of PFA lesions may support broader applications in complex arrhythmia substrates, provided that procedural precautions, such as nitrate administration, are taken to reduce coronary vasoreactivity.

Conclusions: PFA using the Farawave catheter can be safely and effectively extended to mitral isthmus ablation in selected cases. Awareness and preparation for potential CAS are essential, particularly when ablating near the coronary arteries.

Keywords: Pulsed-field ablation (PFA). Atrial fibrillation. Mitral isthmus ablation. Coronary artery spasms (CAS). Atypical atrial flutter.



[12INAHRS-CR151]

Breaking the Barrier: Conduction System Pacing as a Game-Changer for Heart Failure with LBBB in Resource-Limited Settings

D. N. Sary¹, A. C. Lubis², M. P. Hutahusut², A. Handayani², M. Hutapea², C. A. Andra²

¹*Cardiology Resident, Department of Cardiology and Vascular, Faculty of Medicine, Universitas Sumatera Utara, Medan, Indonesia*

²*Cardiologist, Department of Cardiology and Vascular, Faculty of Medicine, Universitas Sumatera Utara, Medan, Indonesia*

Background: Heart failure with reduced ejection fraction (HFrEF) and left bundle branch block (LBBB) are common clinical challenges that lead to interventricular and intraventricular dyssynchrony. This exacerbates left ventricular dysfunction and increases the risk of sudden cardiac death (SCD). Cardiac resynchronization therapy (CRT) has traditionally been the treatment of choice for improving hemodynamics and survival. However, CRT is expensive and requires specialized devices that may not be available in resource-limited settings. Conduction system pacing (CSP) offers a promising alternative that directly stimulates the conduction system to restore physiological ventricular activation. CSP has shown potential benefits similar to those of CRT, improving synchronization and reducing the risk of SCD.

Case Illustration: A 59-year-old woman with a four-year history of recurrent dyspnea, worsening over the past four days, was admitted. Previous electrocardiograms (EKGs) showed atrial fibrillation (AF) with aberrancy, which reverted after antiarrhythmic treatment. On admission, her EKG revealed LBBB with a QRS duration of 160 ms. Echocardiography revealed a reduced left ventricular ejection fraction (LVEF) of 31%, concentric left ventricular hypertrophy (LVH), right ventricular dysfunction, and left atrial dilation. The patient was started on diuretic therapy due to fluid congestion.

Given the persistent symptoms, CSP with LBBAP was considered. The procedure was successful, and her post-implantation EKG showed a left ventricular activation time (LVAT) of 76 ms, QRS morphology with an r' pattern in V1, and a QRS duration of 118 ms. The pacing rate was set at 70 bpm, and the patient reported significant improvement in symptoms, particularly a reduction in dyspnea. Follow-up echocardiography performed days after the procedure showed a slight improvement in LVEF.

Discussion: LBBB in HFrEF causes delayed ventricular activation, contributing to mechanical dyssynchrony, decreased stroke volume, and an increased risk of heart failure exacerbations and SCD. CSP, particularly LBBAP, bypasses the need for coronary sinus leads and restores synchronized conduction, thereby improving heart function. In this case, LBBAP reduced QRS duration, improved symptoms, and led to a modest recovery in LVEF, showcasing CSP as an effective and practical alternative to CRT.

Conclusion: CSP is a promising alternative to CRT in patients with heart failure and LBBB, particularly in resource-limited settings. This case highlights the potential of CSP to improve symptoms and echocardiographic parameters, including LVEF, without the need for expensive CRT.

Keywords: Heart Failure Reduced Ejection Fraction, Left Bundle Branch Block, Conduction System Pacing, Left Bundle Branch Area Pacing

[12INAHRS-CR152]
**Between Two Heartbeats: A Young Pregnant Woman with Silent Bradycardia,
Recurrent Losses, and a Hidden Rhythm Crisis**

S.R.N.A. Haloho¹, Zulfahmi²

¹General Practitioner, RSUD Sejiran Setason, West Bangka, Indonesia

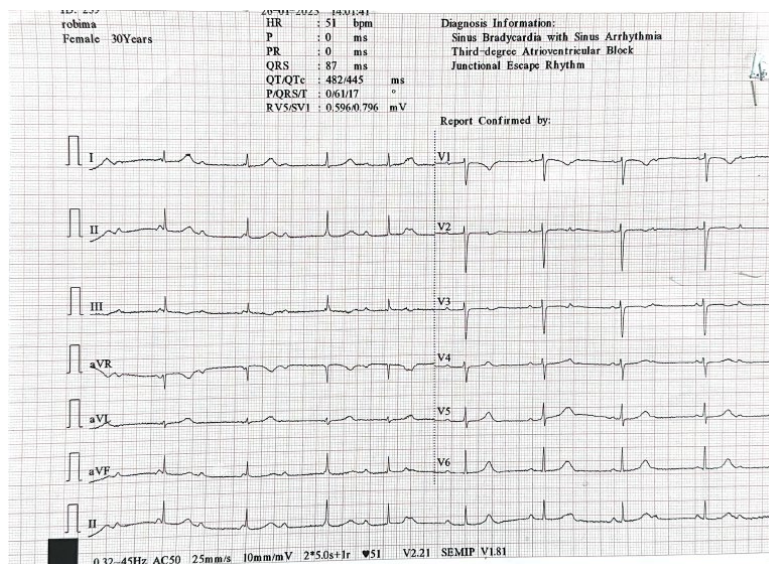
²Cardiologist, RSUD Sejiran Setason, West Bangka, Indonesia

Background: Cardiac conduction disorders are rare in young women, particularly during pregnancy. Complete atrioventricular (AV) block and sinus node dysfunction pose significant risks to both maternal and fetal outcomes. When combined with a history of recurrent pregnancy loss, such cases require timely diagnosis and a coordinated, multidisciplinary approach.

Case Illustration: A 30-year-old pregnant woman was admitted to the emergency unit with fever due to dengue infection. Profound asymptomatic bradycardia (heart rate: 48 bpm) was observed. Surface electrocardiography demonstrated a third-degree AV block with a junctional escape rhythm. The patient denied experiencing syncope, dizziness, or exertional intolerance. There was no prior cardiac evaluation or history of cardiac disease. Her obstetric history was notable for three first-trimester miscarriages and one prior delivery at 24 weeks during her first pregnancy; the neonate died at 7 days of life due to complications of prematurity. At presentation, she was 15 weeks pregnant with her fifth pregnancy. Initial cardiac evaluation and monitoring were performed at our institution. Given the bradycardia and hemodynamic stability, she was managed conservatively with oral salbutamol (2 mg three times daily). Initially hesitant, the patient consented to be referred to tertiary care for an electrophysiology consultation on the sixth day of hospitalization. Holter monitoring revealed sinus node dysfunction (SND). A permanent dual-chamber pacemaker was implanted, without complications. Subsequent maternal-fetal assessment identified cervical funneling (Y-configuration), cervical shortening, and subchorionic and subamniotic hemorrhages. Prophylactic cervical cerclage was performed to mitigate the risk of preterm labor.

Conclusion: Early recognition of conduction abnormalities is critical. Multidisciplinary interventions can optimize outcomes. This case emphasizes the need for heightened awareness of the cardiac causes of obstetric complications.

Keywords: complete heart block, sinus node dysfunction, pregnancy loss



[12INAHRS-CR153]

Beyond the Guidelines: A Case Report on Real World Management of Total Atrioventricular Block in Acute Myocardial Infarction with Limited Resources

M. Irawan¹

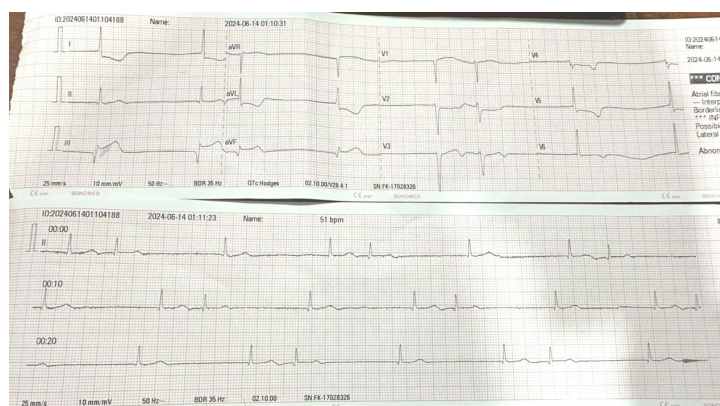
¹*Prikasih Hospital, Jakarta, Indonesia*

Background: Third-degree atrioventricular (AV) block represents a complete disruption of electrical conduction between the atria and ventricles. In the absence of adequate AV nodal conduction, the sinoatrial (SA) node is unable to regulate the ventricular rhythm, leading to reduced cardiac output due to the loss of atrioventricular synchrony. This condition frequently arises as a mechanical complication of acute myocardial infarction (MI).

Case Illustration: A 68-year-old man presented to the emergency department of a type C hospital with decreased consciousness that occurred 30 min before. Clinical findings included a Glasgow Coma Scale score of E3M6V4, hypotension, bradycardia, dyspnea, and oxygen saturation of 88% on room air. Electrocardiography (ECG) revealed total AV block (TAVB) with ST-segment elevation in the inferior leads. Initial therapy included oxygen supplementation, atropine sulfate (total dose, 1.5 mg), and maintenance of tissue perfusion with intravenous dopamine. An antiplatelet loading dose was administered via a nasogastric tube, along with subcutaneous anticoagulant using enoxaparin. The patient was referred to a tertiary hospital for primary percutaneous coronary intervention (PCI) and temporary pacemaker (TPM) insertion.

Conclusion: Inferior STEMI due to right coronary artery occlusion may result in TAVB and cardiogenic shock. In resource-limited hospitals without PCI and TPM facilities, early recognition, accurate diagnosis, and maximal supportive management are essential for improving outcomes. Timely referral through an integrated system is crucial for preventing mortality.

Keywords: Total atrioventricular block, acute myocardial infarction, consciousness.



[12INAHRS-CR154]

Delayed Ventricular Arrhythmia Following Low-Voltage Electrocutation: A Case Report

M. N. Nugroho¹, R. A. Rabby², S. P. Kencana¹

¹General Practitioner, Tigaraksa General Hospital, Tangerang, Indonesia

²Cardiologist, Tigaraksa General Hospital, Tangerang, Indonesia

Background: Low-voltage electrical injuries are typically considered benign, particularly in patients with stable vital signs and normal electrocardiograms (ECG). Cardiac involvement is usually immediate and rare. However, delayed arrhythmias can occasionally occur and may be overlooked in the absence of early warning signs.

Case Illustration: A 53-year-old woman without any known chronic illnesses or family history of cardiac disease or sudden cardiac death presented to the emergency department two hours after sustaining a low-voltage electrical injury while unplugging a power cable in a flooded bathroom. She experienced a brief loss of consciousness (~5 minutes), followed by a mild headache and two episodes of vomiting. The patient denied any history of chest pain, palpitations, or exertional dyspnea. On examination, she was alert and hemodynamically stable, with a superficial burn mark on her left palm (entry point). The initial ECG showed normal sinus rhythm, and laboratory tests revealed mild hypokalemia (2.8 mmol/L), which was corrected. The patient was admitted for inpatient observation.

The patient remained asymptomatic for 24 hours. On day two, she developed palpitations and shortness of breath. The ECG showed new-onset ventricular couplets and bigeminy. Cardiac biomarkers and echocardiography were unavailable. She was treated with oral bisoprolol (2.5 mg daily), resulting in the resolution of symptoms and normalization of the ECG. The patient was discharged in a stable condition on day four.

Conclusion: This case highlights that delayed ventricular arrhythmias can occur even after low-voltage electrocution, particularly in patients with loss of consciousness (LOC). Clinical decisions should not rely solely on initial ECG or voltage levels. In line with the current literature, at least 24 hours of ECG monitoring is recommended for patients presenting with red flags. Structured observation and clinical vigilance are essential to avoid missed arrhythmias.

Keywords: electrical injury, electrocution, cardiac monitoring, ventricular arrhythmia

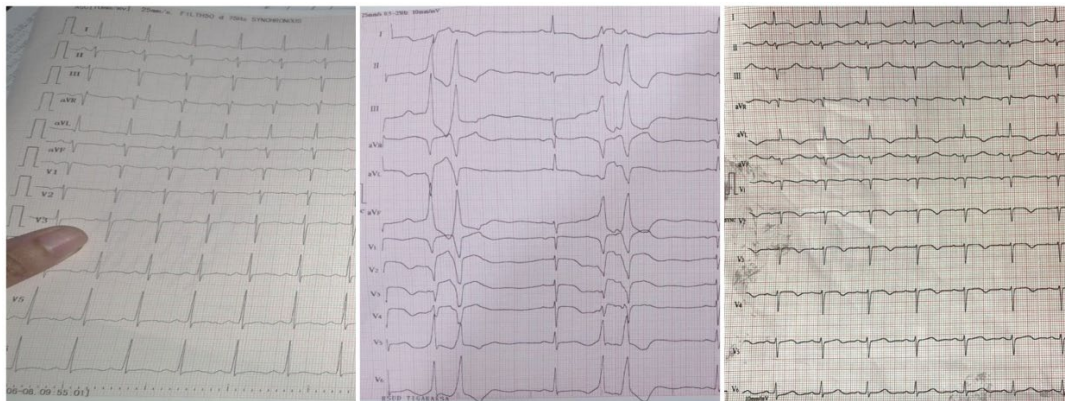


Figure 1. Left: Normal sinus rhythm upon admission. Middle: Ventricular couplets and bigeminy on day two. Right: Normal sinus rhythm with T-wave inversions in V2–V4, I, and aVL on day four.

[12INAHRS-CR155]

Inflammatory Cardiomyopathy Manifesting as Atrial Fibrillation and Frequent Premature Ventricular Contractions: Case Series of Two Clinical Presentations

**D. D. Deria¹, L. Qadrina¹, D. Siagian¹, R. R. E. Kristineke¹, Frederik S¹,
R. Maulana¹, Haikal², A. Harsoyo².**

¹General Practitioner, Arrhythmia Unit, Department of Cardiology and Vascular Medicine, Gatot Soebroto Army Central Hospital, Jakarta, Indonesia

²Arrhythmia Subspecialist, Department of Cardiology and Vascular Medicine, Gatot Soebroto Army Central Hospital, Jakarta, Indonesia

Background: The mechanism of arrhythmias in myocarditis is multifactorial, involving inflammation, myocardial injury, and ion channel disruption, which can cause anatomical remodeling, leading to electrical remodeling. (1) Arrhythmias, particularly ventricular arrhythmias, may occur in some cases, especially in young adults, and can cause a significant number of sudden cardiac deaths, up to 10 %. In addition, a left ventricular ejection fraction (LVEF) <50% and late gadolinium enhancement (LGE) on cardiac magnetic resonance imaging increase the risk of arrhythmias and death. (2)

Case Illustration:

Case 1: A 49-year-old man presented with palpitations and a history of dyslipidemia, hypertension, and active smoking. Laboratory tests showed WBC within normal limits, mild eosinophilia (8%), elevated monocyte count (10%), and increased ESR at 25 mm/h, ASTO 83 IU/mL. Holter monitoring revealed frequent multifocal PVCs (9% burden), primarily from the anterior RVOT, burst PACs, and suspected paroxysmal AF. Echocardiography revealed a mildly reduced LVEF (48.5%), concentric LV with E/A fusion, mild TR, and RWMA. Cardiac MRI revealed reduced LVEF (44%), global LV hypokinesia, AML prolapse, myocardial microinflammation, non-ischemic scars in multiple LV and RV segments, subepicardial late gadolinium enhancement (LGE), and pericardial enhancement, consistent with myocarditis.

Case 2: A 17-year-old female patient with no comorbidities presented with palpitations. Laboratory tests showed an elevated WBC count (11150/ μ L) with an increased segmented neutrophil count (70%), accompanied by an elevated ESR. Holter monitoring showed persistent atrial fibrillation (75% burden), frequent PVCs from the anterior RVOT (9% burden), and 1st AV block. Echocardiography demonstrated LA and LV dilation, eccentric LV hypertrophy, global hypokinesia, and reduced LVEF (38%). RV function was preserved (TAPSE, 1.7 cm). Cardiac MRI revealed an LVEF of 36%, impaired RV function (RVEF 31%), and widespread myocardial fibrosis and edema on T1 mapping and ECV assessment, indicative of myocarditis. Further investigations are underway to determine the other potential causes of myocarditis.

Conclusion: Myocarditis should be considered in patients with unexplained arrhythmias and LV dysfunction, regardless of age or comorbidities, particularly when the standard ischemic workup is negative. Early cardiac imaging should be considered to confirm the diagnosis and guide management before irreversible myocardial damage occurs.

Keywords: myocarditis, premature ventricular contractions, atrial fibrillation, left ventricular dysfunction

[12INAHRS-CR156]

When the Atrioventricular Node Stops Talking: How a Pregnant Woman with Total AV Block and Gestational Hypertension Defied the Odds

M. G. Perdana¹, A. D. Lamara¹, A. L. Rahman¹, D. N. Ghassani¹, R. I. Gunadi¹, M. J. A. Farabi¹, R. N. Rosyadi¹, R. Julario¹, B. B. Dharmadjati¹

¹Department of Cardiology and Vascular Medicine, Soetomo General Hospital, Faculty of Medicine, Airlangga University, Surabaya, Indonesia

Background: Total atrioventricular block (TAVB) during pregnancy is a rare disorder, with an estimated incidence of 1 in 20.000 pregnancies. In the context of pregnancy, physiological cardiovascular adaptations, such as hormonal changes, increased blood volume, heart rate, and vagal tone, may exacerbate conduction abnormalities, leading to bradycardia and compromised maternal-fetal circulation. The coexistence of gestational hypertension further increases the risk of adverse outcomes, including preterm delivery, fetal growth restriction, and maternal decompensation. We report a case of a structurally normal heart presenting with TAVB and gestational hypertension, successfully managed with temporary pacing and caesarean section at term.

Case Illustration: A 30-year-old pregnant woman was referred to the Emergency Department from another hospital with complaints of abdominal pain and amniotic fluid leakage. Electrocardiography (ECG) revealed TAVB. She was administered 3 mg of atropine sulfate; however, repeat ECG continued to show TAVB. This was her first pregnancy at a gestational age of 39–40 weeks. The patient had no history of cardiac disease. On arrival at our hospital, her blood pressure was 157/92 mmHg, and an ECG confirmed TAVB at a rate of 44 beats per minute. Laboratory test results were within normal limits. Echocardiography revealed normal cardiac structure and function, with an ejection fraction of 54%. Dopamine infusion was initiated to support the hemodynamics. A temporary pacemaker was implanted. An emergency caesarean section was performed by the obstetric team, resulting in the delivery of a healthy newborn. Following delivery, the patient was monitored by both the cardiology and obstetrics teams. After several days of observation, the TAVB persisted, and we decided to proceed with permanent pacemaker implantation. Once her condition stabilized, she was discharged with no complaints.

Conclusion: This case underscores the importance of early identification and management of TAVB during pregnancy, even in previously asymptomatic women without known structural heart disease. Hemodynamic stabilization and temporary pacing, combined with multidisciplinary coordination, can lead to safe maternal and neonatal outcomes in such cases. This case adds to the limited literature on conduction disturbances coexisting with gestational hypertension and may inform protocols for emergency pacing in similar obstetric scenarios.

Keywords: Total AV-block, gestational hypertension, arrhythmia, pregnancy

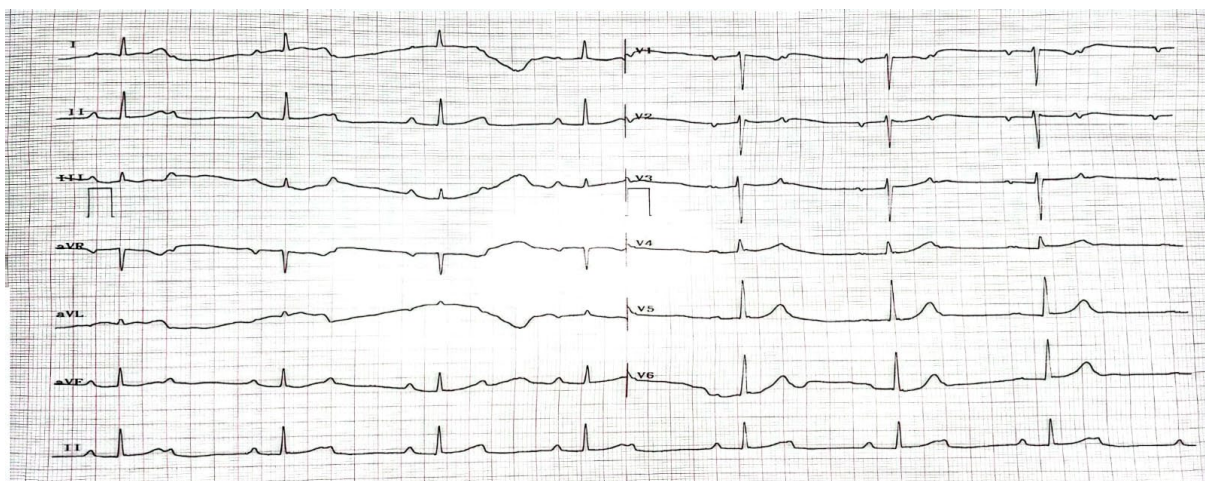


Figure 1. ECG showed total atrioventricular block at a rate of 44 beats per minute.

[12INAHRS-CR157]
Mutation SCN5A with Bradycardia Symptoms: Should ICD Therapy be Considered?

N.H. Karunawan¹, G.Karwiky¹, M. Iqbal¹, C. Achmad¹

¹Department of Cardiology and Vascular Medicine, Universitas Padjadjaran, Bandung, Indonesia

Introduction: SCN5A mutations are associated with various inherited cardiac diseases with different electrophysiological profiles. A gain-of-function mutation is associated with long QT syndrome, whereas a loss-of-function mutation is associated with Brugada syndrome, progressive conduction disease, and sick sinus syndrome. Here, we describe a patient with bradycardia and SCN5A mutations that have not been previously reported in Asians.

Case Illustration: A 30-year-old man presented with recurrent dizziness and palpitations for 5 years. His family history revealed the presence of several cases of cardiac conduction disease: his mother (52 years old) was affected by sick sinus syndrome and was implanted with a pacemaker. His cousin was affected and experienced sudden cardiac death at 21 years of age. The ECG shows a Brugada pattern type 2 (Figure 1). Echocardiography revealed no structural or functional changes, and EPS demonstrated SA and AV node dysfunction with no inducible VT or VF. The patient was referred for exercise and genetic testing. He stopped at minute 12:17 due to fatigue (Borg Scale 17) according to the standard Bruce protocol. However, lightheadedness with bradycardia occurred at recovery phase minute 08:00, exercise-induced hypotension at recovery minute 17:50, and chronotropic incompetence. ECG at recovery phase showed a sinus pause episode at recovery minute 7:50 and junctional bradycardia at recovery minute 8:50 (Figure 2). The patient underwent genetic testing for genes associated with cardiac conduction disease, which showed a likely pathogenic variant in SCN5A (c.310C>T; p.Arg104Trp; heterozygous mutation). Finally, the patient underwent ICD pacemaker implantation.

Conclusion: Bradycardia can occur in patients with heterozygous mutations of SCN5A with the Brugada pattern on ECG. SCN5A variants, such as the loss-of-function splice donor variant c.310C>T found in our patient, may lead to a variety of clinical syndromes, including sinus pause episodes and junctional bradycardia. Genetic etiology may provide prognostic information and guide cascade screening, risk stratification, and management. ICD-pacemaker implantation was considered because of SCD in the family. Further research is warranted to determine the optimal management strategy for these patients.

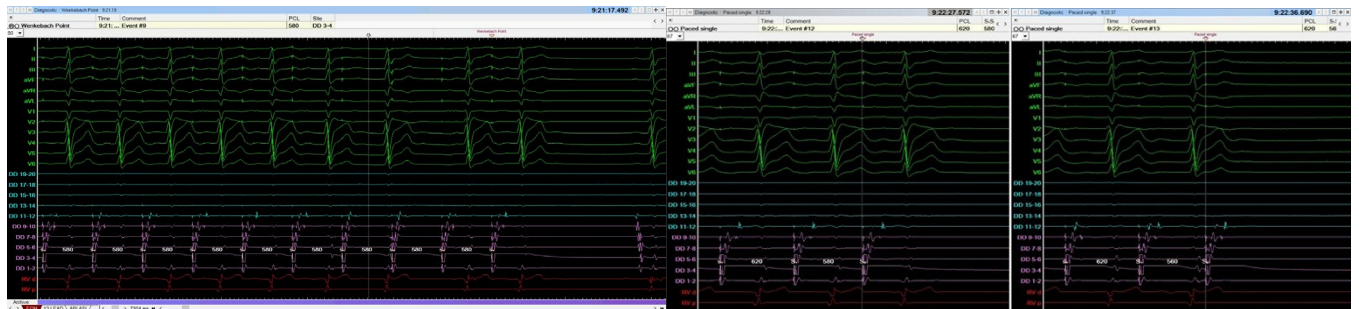


Figure 1. AV function: Wenkebach Point > 580 ms, HRA S1S2 showed AVN ERP 650/540 ms.

[12INAHRS-CR158]

From Tachycardia Challenges to Sinus Rhythm Restoration: Management of SVT and Atrial Fibrillation in a Young Patient with Mitral Regurgitation

B. Presidiana¹, M. Ardiana¹, R. I. Gunadi¹

¹Department of Cardiology and Vascular Medicine, Faculty of Medicine, Airlangga University, Dr. Soetomo General Hospital, Surabaya, Indonesia

Background and aims: Supraventricular arrhythmias frequently complicate the clinical course of patients with mitral regurgitation (MR), particularly in acute decompensated heart failure. We report a case of a 35-year-old man who exhibited recurrent episodes of supraventricular tachycardia (SVT), including an episode that spontaneously reverted to sinus rhythm. Additionally, the patient experienced atrial fibrillation (AF), which is also manageable and can be converted to sinus rhythm. Changes in volume status, particularly overload, play a primary role in triggering electrical instability by dilating the left atrium (LA) and disrupting the conduction pathways. SVTs may result from atrial stretch or triggered activity, whereas ongoing remodeling and fibrosis can lead to persistent atrial fibrillation (AF), marked by disorganized electrical activity. Chronic volume overload in mitral regurgitation (MR) leads to LA enlargement and structural changes, creating a substrate for both recurrent SVT and paroxysmal AF. Elevated LA pressure and volume induce electrophysiological changes, including fibrosis, which further perpetuate an arrhythmogenic environment. This case exemplifies the dynamic interplay between acute hemodynamic perturbations and chronic atrial remodeling in the pathogenesis of supraventricular arrhythmias. Comprehensive management focuses on irreversible factors related to achieving and sustaining sinus rhythms in complex clinical scenarios.

Conclusion: Alterations in volume status, particularly volume overload, play a fundamental role in precipitating electrical instability. Volume overload contributes to left atrial (LA) dilatation and disrupts the atrial conduction pathways. Supraventricular tachycardia (SVTs) may develop secondary to atrial stretch or triggered activity; however, persistent atrial remodeling and fibrosis promote progression to permanent atrial fibrillation (AF), which is characterized by disorganized, sustained electrical activity.

Keywords: Exercise stress test, sudden cardiac death risk stratification, Wolff-Parkinson-White syndrome, arrhythmias, ventricular preexcitation, high-risk occupations, occupational health assessment, police, officers, police selection.

[12INAHRS-CR159]

Echocardiographic Hemodynamic Optimization to Evaluate Atrioventricular Synchronized Pacing Need In Pacemaker Syndrome

S. Kristianti¹, F. M. Yofrido¹, Jefri¹, C. J. Hardi², B. M. Setiadi¹

¹Department of Cardiology and Vascular Medicine, Prof. Dr. R. D. Kandou Hospital – Faculty of Medicine, Sam Ratulangi University, Manado, Indonesia

²Manado City Regional General Hospital, Indonesia

Background: Pacemaker syndrome refers to a collection of symptoms resulting from the loss of atrioventricular (AV) synchrony in patients with single-chamber ventricular pacing devices. Pacemaker syndrome can be challenging to diagnose, particularly when there are no significant echocardiographic findings. We used simple echocardiographic hemodynamic optimization to guide management and restore AV synchrony by upgrading from single- to dual-chamber pacing.

Case Illustration: A 74-year-old woman with a history of total atrioventricular block underwent single-chamber pacemaker implantation six years prior and presented with exertional dyspnea, orthopnea, and near-syncope over the preceding six months. She required repeated hospitalizations following the recurrence of symptoms. Physical examination revealed elevated jugular venous pressure, rales, and pitting edema. Electrocardiography revealed ventricular pacing. Repeated transthoracic echocardiography revealed a preserved left ventricular (LV) ejection fraction (64%). Given the clinical suspicion of pacemaker syndrome, echocardiographic hemodynamic optimization with a temporary transvenous dual-chamber pacemaker was performed to assess cardiac filling pressures and guide pacing adjustments to improve diastolic function and cardiac output. LV filling pressures were elevated during VVI pacing (pulmonary capillary wedge pressure/PCWP 18.5-21 mmHg) and improved with temporary dual-chamber DDD (PCWP 15 mmHg). Based on these findings, the patient underwent an upgrade to a dual-chamber permanent pacemaker. At the 3-month follow-up, the patient reported resolution of heart failure symptoms.

Conclusion: Pacemaker syndrome should be considered in patients who develop heart failure symptoms after single-chamber ventricular pacing. This case highlights the diagnostic utility of simple echocardiographic hemodynamic optimization in confirming pacemaker syndrome and guiding device upgrades. Restoration of AV synchrony through dual-chamber pacing results in significant hemodynamic and symptomatic improvements.

Keywords: Echocardiographic hemodynamic optimization, pacemaker syndrome

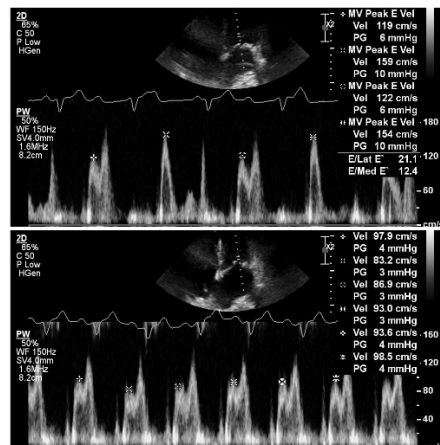


Figure 1. PCWP in the VVI mode (above) and DDD mode (below).

[12INAHRS-CR160]

Left Atrial Appendage Edema and Dense Spontaneous Echo Contrast Following Pulsed-Field Ablation for Pulmonary Vein Isolation: A Hidden Risk?

Jefri¹, F. Tedjasukmana², E. J. Gunawan², D. L. Munawar², B. M. Setiadi¹, D. A. Munawar^{2,3}, B. Hartono^{1,2}, M. Munawar^{1,2}

¹Faculty of Medicine, Sam Ratulangi University, Manado, Indonesia

²Binawaluya Cardiac Centre Hospital, Jakarta, Indonesia

³The University of Adelaide and Royal Adelaide Hospital, Adelaide, Australia

Background: Pulsed Field Ablation (PFA) is a novel non-thermal ablation technique with many advantages. Despite these advantages, data on potential complications remain limited. This case highlights the potential complications arising from PFA procedures, which are rarely reported.

Case Illustration: A 70-year-old man with persistent atrial fibrillation, HFpEF, and a history of ischemic stroke. Given the patient's symptomatic heart failure and the occurrence of stroke despite adequate OAC treatment, as well as the high bleeding risk associated with long-term anticoagulation, the patient was scheduled for pulmonary vein isolation (PVI) ablation using PFA for rhythm control, along with concomitant LAAC for stroke prevention and to reduce bleeding risk. Preprocedural imaging showed no left atrial appendage edema. Following ablation, a TEE evaluation was performed before proceeding with LAAC. However, significant edema of the LA ridge and appendage was observed following the PFA procedure, causing an increase in ridge dimensions to 7.75×10 mm and a reduction in ostium diameter to 1.51 cm in the same TEE view. Additionally, a dense SEC was detected in the LAA. Although the procedure successfully restored sinus rhythm, post-ablation transesophageal echocardiography revealed significant left atrial appendage (LAA) and left atrial ridge edema with dense spontaneous echocontrast (SEC), leading to LAAC postponement and anticoagulation initiation.

Conclusion: Although PFA has advantages over conventional ablation, its impact on LAA structures requires further investigation. Careful procedural planning is crucial to minimize risks and optimize outcomes, especially when considering concomitant PFA and LAAC, as PFA may induce edema at the left atrial ridge, potentially affecting subsequent LAAC device implantation.

Keywords: pulsed field ablation, left atrial ridge oedema, left atrial appendage closure

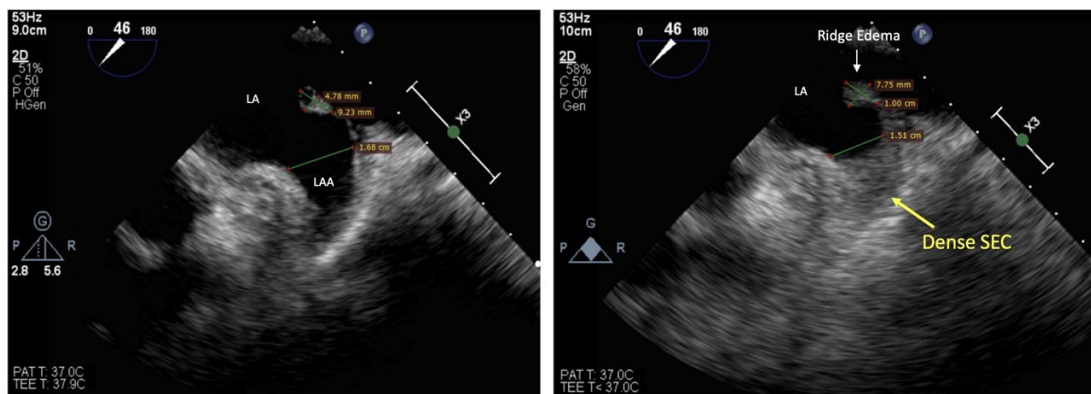


Figure 1. Comparison of pre-ablation (left) and post-ablation (right) TEE images showing edema in the LAA ridge, resulting in a smaller LAA ostium and dense SEC compared to baseline.

[12INAHRS-CR161]

Bachmann Pacing in Sick Sinus Syndrome: A Case Report

G. Handayani¹, B. Setiadi¹, E.J Gunawan², D.L Munawar², B. Hartono², M. Munawar²

¹*Universitas Sam Ratulangi, Manado, Indonesia*

²*Binawaluya Heart Center, Jakarta, Indonesia*

Objective: This case report aimed to demonstrate the implementation and benefits of Bachmann's bundle pacing in a patient with sick sinus syndrome, focusing on the technical approach and electrocardiographic changes.

Methods: A 78-year-old man presented with fatigue, dizziness, and presyncope symptoms. ECG showed alternating brady-tachy arrhythmia with normal sinus and junctional rhythms. The patient had hypertension, type II diabetes mellitus, and stage IIIb chronic kidney disease (CKD). The initial P wave duration was 110 ms, with a PR interval of 194 ms during sinus rhythm. Permanent pacemaker implantation was performed using an active lead, and the ventricular lead was positioned at the anatomical left bundle branch. For atrial lead placement at Bachmann's bundle, a hand-shaped stylet is used to navigate the target area at the right atrial roof and interatrial septum. Lead positioning was confirmed using fluoroscopy in multiple views.

Results: Post-procedure ECG demonstrated a reduction in P wave duration to 88 ms, with positive P waves in leads I, II, and III and a biphasic P wave in V1. The paced P wave started immediately with the pacing spike without latency and was 15-20 ms shorter than the sinus P wave when measured on the 6-limb lead electrocardiogram. The patient remained hemodynamically stable throughout and after the procedure.

Conclusions: Bachmann's bundle pacing resulted in a shorter P wave duration while preserving the PR interval. This approach potentially reduces unnecessary ventricular pacing, which may help decrease atrial fibrillation incidence and prevent stroke by improving left ventricular function through optimized atrial activation

[12INAHRS-CR162]

Structural Malformation, Electrical Precision: Ablation of Persistent SVT in Ebstein Anomaly

N. A. Tambunan¹, A. C. Lubis², A. N. Nasution³

¹*Cardiology Resident, Department of Cardiology and Vascular, Faculty of Medicine, Universitas Sumatera Utara, Medan, Indonesia*

²*Cardiologist, Department of Cardiology and Vascular, Faculty of Medicine, Universitas Sumatera Utara, Medan, Indonesia*

³*Department of Cardiology and Vascular Medicine, Faculty of Medicine, Universitas Sumatera Utara, Haji Adam Malik General Hospital, Medan, Indonesia*

Background: Ebstein's anomaly is a rare congenital heart defect characterized by apical displacement of the tricuspid valve, atrialization of the right ventricle, and frequent association with tricuspid regurgitation and supraventricular tachyarrhythmias due to accessory pathways and right atrial dilatation.

Case Illustration: A 44-year-old man presented with recurrent palpitations and cyanosis, with electrocardiographic findings of wide complex tachycardia and right bundle branch block. Echocardiography revealed the typical features of Ebstein's anomaly, including an atrialized right ventricle, apical displacement of the tricuspid valve, and an atrial septal defect. An electrophysiological study confirmed orthodromic atrioventricular reentrant tachycardia (AVRT) mediated by a posterolateral accessory pathway. Catheter ablation targeting the accessory pathway of the tricuspid annulus was performed. Restoration of a stable sinus rhythm was achieved after successful ablation, with significant clinical improvement and no recurrence of arrhythmia during hospitalization. Follow-up ECG demonstrated a normal rhythm with persistent right axis deviation and right bundle branch block.

Conclusion: Persistent SVT in patients with Ebstein's anomaly is commonly attributed to accessory pathway-mediated reentrant circuits. Electrophysiological studies and catheter ablation represent effective strategies for definitive rhythm control, particularly in symptomatic patients with hemodynamic compromise.

Keywords: Ebstein's anomaly, supraventricular tachycardia, accessory pathway, atrioventricular reentrant tachycardia, catheter ablation