

# Non Surgical Management of Unprotected Isolated Ostial Left Main Coroner Artery Disease

Kabul Priyantoro, Sunarya Soerianata

Departement of Cardiology and Vascular Medicine, Faculty of Medicine University of Indonesia, and National Cardiovascular Center Harapan Kita, Jakarta

Prevalence of left main coroner artery (LMCA) stenosis in patients undergoing coronary angiography was 2.5 to 10 %, almost all patients suffer from concomitant atherosclerotic disease of other coronary branches. In contrast, an isolated atherosclerotic lesion of LMCA is very rare, with incidences 0.07 to 0.15 %. Coroner artery bypass graft surgery (CABG) has been recommended as the standard treatment in LMCA disease, however, percutaneous coronary interventions (PCI) on the LMCA remained in scope, as some patients with high risk or contraindications of CABG and very limited life expectancy, still had no other option than PCI.

A 58<sup>th</sup> years old man with risk factor; smoker, dyslipidemia and hypertension, complain of chest discomfort, he was referred with diagnosis of APS CCS III and MSCT coroner revealed mild plaque burden with critical subtotal occlusion in LMCA, calcified plaque in LAD and other vessels were normal. He refuse CABG and went for PCI, angiography revealed significant isolated unprotected LMCA disease. Successful PCI using anchor wire technique and implantation of BMS in the lesion was done. Patient discharged on day 6 of hospitalization with no complication.

(J Kardiol Indones. 2012;33:166-73)

**Keywords:** Isolated ostial LMCA stenosis, Percutaneous coronary intervention (PCI), and bare metal stent (BMS)

# Tatalaksana Nonbedah pada Penyempitan Pembuluh Darah Utama Koroner Kiri yang Terisolasi

Kabul Priyantoro, Sunarya Soerianata

Prevalensi penyempitan pembuluh darah utama koroner kiri pada pasien yang menjalani pemeriksaan angiografi koroner berkisar antara 2,5 – 10%, dan hampir semua lesi disebabkan oleh proses aterosklerosis yang juga melibatkan cabang – cabang pembuluh darah koroner lainnya. Lesi aterosklerotik yang terisolasi hanya pada pangkal pembuluh darah utama koroner kiri sangat jarang, dengan insiden 0,07 – 0,15% pada semua tindakan angiografi di dunia. Bedah pintas koroner (CABG) merupakan prosedur standar menangani kasus penyempitan pembuluh darah koroner utama kiri. Kateterisasi jantung transkutan (PCI) memiliki peran bagi pasien dengan resiko tinggi atau memiliki kontra indikasi untuk menjalani CABG.

Laki – laki 58 tahun dengan faktor resiko; merokok, dislipidemia, dan hipertensi, mengeluh dada terasa tidak nyaman, pasien dirujuk dengan diagnosis APS CCS III, pemeriksaan MSCT koroner menemukan lesi aterosklerotik dengan sumbatan subtotal pada pangkal pembuluh darah utama koroner kiri, kalsifikasi pembuluh LAD sedangkan pembuluh koroner lainnya baik. Pasien menolak tindakan CABG dan menjalani PCI, pada angiografi koroner didapatkan penyempitan signifikan pangkal pembuluh darah utama koroner kiri, tanpa kolateral kecabang pembuluh darah koroner kiri distal. Dilakukan tindakan PCI dengan 1 BMS menggunakan teknik *anchor wire* pada lesi dengan hasil baik.

(J Kardiol Indones. 2012;33:166-73)

**Kata kunci:** Penyempitan pembuluh darah utama koroner kiri yang terisolasi, kateterisasi koroner transkutan (PCI), stent tanpa obat (BMS)

## Introduction

The prevalence of LM stenosis in patients undergoing coronary angiography range from 2.5 to 10 %; and nearly all patients suffer from a concomitant atherosclerotic disease of other coronary branches.

In contrast, an isolated atherosclerotic lesion of the LM is very rare, with reported incidences of 0.07 to 0.15 % of all angiographed patients.<sup>2</sup> In national cardiac center Harapan Kita hospital (NCCHK) during 2009 there were around 120 cases of LM disease that underwent CABG, meanwhile those in the same period that were perform PCI around 56 cases.<sup>3</sup> Based on available evidence on significant left main coronary artery (LMCA) disease (both protected and unprotected), coronary artery bypass graft surgery (CABG) has been recommended as the standard of treatment in managing LMCA disease.<sup>4</sup>

### Alamat Korespondensi:

dr. Sunarya Soerianata, SpJP Pusat Jantung Nasional Harapan Kita  
Jl. S Parman Kav 87 Slipi Jakarta I 1420 e-mail: [dr.sunaryasoerianata@gmail.com](mailto:dr.sunaryasoerianata@gmail.com)

In 1984 the National Heart, Lung, and Blood Institute in Austria published a consensus that stenosis of the LMCA were a contraindication to percutaneous transluminal coronary angioplasty.<sup>4</sup> However, percutaneous interventions on the LMCA remained in scope, as some patients with high risk for CABG, with contraindications to CABG or with very limited life expectancy still had no other option than a percutaneous intervention of the LM<sup>5</sup>. Impressive advances in stent technology together with improvements in interventional techniques, adjunctive device, drug therapy and supported by many growing evidence on feasibility and safety of percutaneous intervention of LMCA disease, unprotected left main coronary artery requiring revascularization remains the area of surgeon at most institutions, but percutaneous coronary intervention (PCI) of an unprotected LMCA has increased in frequency.<sup>5,6</sup>

Moreover in 2009, a consensus document from 6 cardiac societies was published describing “*Appropriateness Criteria for Coronary Revascularization*,” in which PCI was considered to be “*inappropriate*” for significant LMCA disease, regardless of the extent of concomitant coronary artery disease, presence or absence of diabetes, and left ventricular function.<sup>6</sup> The aim of this case report is to present feasibility and safety on management of percutaneous coronary intervention in significant unprotected isolated ostial left main coronary artery (LMCA) stenosis.

## Case Illustration

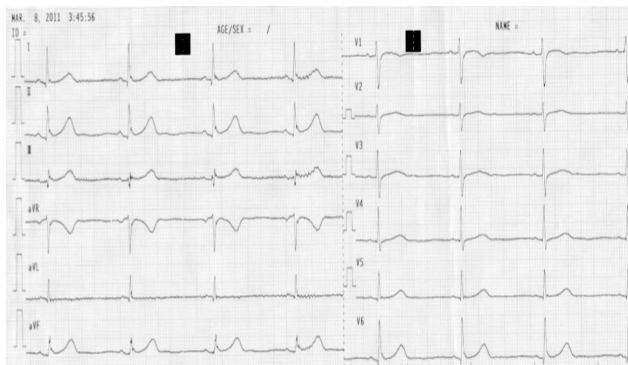
A 58<sup>th</sup> years old man was requested to be referred to national cardiac center harapankita (NCCHK) from Sanglah hospital with diagnosis of APS CCS III after suffering from myocardial infarction for further management, patient with coronary artery disease risk factors smoker, hypertension and dyslipidemia. Patient with medical history of being hospitalized in Sanglah hospital 5 month ago due to myocardial infarction (NSTEMI), he was received standard therapy with dual antiplatelet and heparinization with fondaparinux for 5 days, then he was discharge from hospital without experiencing any chest pain at rest, but at home on daily activities he still complain of being very easy to get tired.

He continue visiting his cardiologist and taking medication regularly, but after 5 months he felt there was no improvement. His physician then scheduled

him for treadmill test, but the test was unable to completely perform because during the test after around 5 min he felt very tired and request to stop the test. He was asked to do cardiac catheterization, but due to some reason he preferred having the examination in NCCHK. On march 3<sup>rd</sup> 2011, he arrived in our hospital through polyclinic without any chest pain nor dyspnea at rest, on physical examination his blood pressure was 120/80 mmHg, BW: 55 Kg, H: 160 cm, BMI: 21,5, no cardiac murmur nor rales in his lungs, his ECG was: SR, QRS rate 60 times per min, P wave: N, PR int: 0,16 det, QRS axis: N, QRS dur: 0,08 sec, ST – T changes (-) → conclusion: normo sinus rhythm without no sign of Q wave infarction.

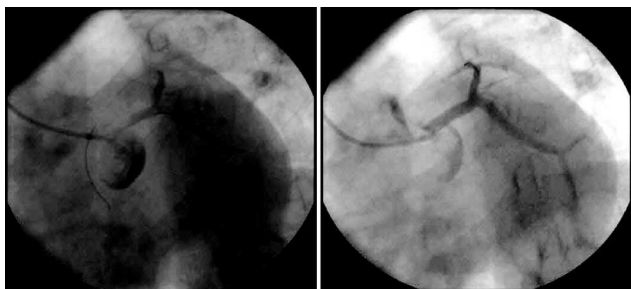
His laboratory result on December 29<sup>th</sup> 2010 revealed that his total cholesterol level was 352, TG: 211, LDL 258, HDL: 51 and was diagnose as APS CCS III with previous medical therapy vaclo 1x75 mg, acetosal 1x80 mg, ISDN 3x5 mg, diltiazem, 2x30 mg, and simvastatin 1x20 mg. In poliklinik he was scheduled for MSCT coroner examination and adjusted medical therapy with vascardin 3x10 mg, ascardia 1x80 mg, concor 1x2,5 mg, tromboles 2x1, plavix 1x75 mg, lipitor 1x20 mg. On march 7<sup>th</sup> 2011 he went for MSCT coroner examination, and the result was; LM: soft plaque in ostial with subtotal stenosis (calcium score 0), LAD: calcified plaque before D1 with 30% stenosis (calcium score 44), LCx and RCA: normal (calcium score 0), with conclusion: mild plaque burden with critical subtotal left main.

After MSCT coroner examination, the patient suddenly felt chest discomfort and weak sensation whole over his body, then immediately he was sent to emergency room to be stabilized, from anamnesis



Picture 1. ECG at Polyclinic: Normo sinus rhythm with no ST – T changes





**Picture 4.** Left: spider view showing critical ostial LMCA stenosis, Right: same patient after BMS implantation

207 ms, E/e' 10, septal e' 6 cm/s, mitral e' 9 cm/s, Ao V max 0,8 m/s; Conclusion: Good LV systolic function with EF 60%, Hypokinetic mid anteroseptal, anterior, LV diastolic function good, with LVEDP normal, TR mild and good RV contractility.

CABG was previously planned for this patient, unfortunately during hospitalization he refused to have CABG and prefer for non surgical intervention, on day 3 (march 10<sup>th</sup> 2011) patient was performed cardiac catheterization, coroangiography showed critical ostial LMCA stenosis with LAD, LCx & RCA were normal, then he proceed with LM intervention using anchor wire technique to facilitate precise ostial stent placement and eliminate errors of positioning inside or outside the ostial narrowing. PCI was conducted successfully in ostial LMCA with Tsunami stent 4.0 x 15 mm (BMS), during and after procedure there were no significant complication and patient was in stable condition.

During hospitalization his clinical and hemodynamic parameter were in good range, with BP range 108 – 111/54 – 68 mmHg, HR range 56 – 66 beat per minutes and experience no repeated chest pain nor dyspnea at rest. One day after catheterization (on day 6<sup>th</sup>) patient was discharge in a good condition his BP: 111/68 mmHg, HR: 66x/min, RR: 15x/min, laboratory showed CK: 22/CKMB: 7/VRDL:(-)/TPHA:(-), with medication prior discharge were ascardia 1x80 mg, plavix 1x75 mg, lipitor 1x20 mg and herbeser cd 1x100 mg. one week after hospitalization patient came for medical control, at home he report no chest discomfort nor dispnea and physical activity improvement, his BP was 115/66 mmHg, HR: 55 – 58x/min, patient then allowed to go back to Denpasar with continued medication: plavix 1x75 mg, ascardia 1x80 mg, amdixal 1x5 mg, simvastatin 1x20 mg.

## Discussion

The detection of ostial LMCA disease in this patient was first by MDCT imaging which revealed mild plaque burden with critical subtotal occlusion in left main coroner artery, a 64 slice MDCT detected a soft plaque in ostial LM with subtotal stenosis (calcium score 0) and calcified plaque before D1 with 30% stenosis (calcium score 44) in LAD and other vessels were normal. Many studies and meta-analyses of MDCT to detect CAD have generally shown high negative predictive values (NPVs), suggesting that MDCT is excellent in excluding significant CAD, while positive predictive values (PPVs) were only moderate, only about half of the stenosis classified as significant by MDCT are associated with ischemia, indicating that MDCT angiography cannot accurately predict the hemodynamic significance of coronary stenosis.<sup>6</sup>

MDCT is reliable for ruling out significant CAD in patients with stable and unstable anginal syndromes and in patients with low to moderate likelihood of CAD, however, MDCT angiography typically overestimates the severity of atherosclerotic obstructions and decisions for patient management require further functional testing, as in this patient that the lesion in LAD according to MSCT was not proven angiographically during invasive diagnostic.<sup>7,8</sup> Isolated ostial LM disease always raise suspicion of non atherosclerotic etiology of coroner artery disease, as seen in this patient after coroangiography examination it was revealed that only ostial LM coroner artery has significant stenosis, then VRDL and TPHA laboratory examination, which gave negative result were carried out in this patient to eliminate syphilitic aortitis.<sup>2</sup>

As written in the literature that isolated coroner ostial stenosis is one of the cardiac manifestations of tertiary syphilis and consider as a disorder of the aorta which can be found or reappeared in developing countries due to drug abuse and sexual promiscuity, which was suspected after coroangiography examination because patient is at reproductive sexual age and lived in the developing country.<sup>1,2</sup> From a histological viewpoint, LMCA is a peculiar muscular artery, it originates directly from the aortic wall which lacks of tunica adventitia at the ostium and extremely rich in smooth muscle cells and elastic tissue in tunica media which is enveloped by the aorta's muscle cells.<sup>2</sup>

The elastic component is more abundant ostial LMCA than in any other coronary branch and tends to decrease distally towards the vessel, consequently all diseases of the aorta can affect the LM trunk, without obvious evidence of atherosclerotic process it is necessary to find out other cause of ostial LMCA disease in order to optimize causative treatment in patient with isolated ostial LMCA disease<sup>2</sup>. Most of left main obstructive disease is caused by atherosclerotic, with higher prevalence in woman in anatomically short (< 10 mm) left main coroner artery and characteristic of lesion are less plaque burden, less calcification, eccentric lesion type and negative remodeling, as in this patient that MSCT coroner examination shown a soft plaque in ostial left main, with calcified plaque before D1 with 30% stenosis (calcium score 44) in LAD suggesting the atherosclerotic process, and support by the presence of coroner atherosclerotic disease risk factor in this patient which are previously smoker (1 pack per day) and dyslipidemia.<sup>1,2</sup>

Darabian et al conduct a research involving 258 patients with left main tract disease, the atherosclerotic risk factors were compared between patients with ostial and nonostial lesions of the left main coronary artery and also in patients with ostial right coronary artery, a multivariate logistic regression analysis revealed that female sex (odds ratio: 2.3) and hypertriglyceridemia (odds ratio: 1.0) were independent risk factors of ostial left main coronary artery disease, for ostial right coronary artery lesion, female sex and family history of coronary artery disease were independent predictors.<sup>7</sup> Demographic and clinical profiles of ostial stenosis suggest that this group may represent a distinct entity, different from more common atherosclerotic left main trunk stenosis.<sup>2,7</sup>

Female sex and serum triglyceride level can be considered as independent predictors of ostial left main coroner artery disease,<sup>7</sup> in this patient, previously he

had total cholesterol level 352, TG: 211, and LDL 258, despite of the gender different dyslipidemia in this patient can be consider as predictor of highly suspicious of ostial left main coroner artery disease. Unprotected LM stenosis paired with ischemic syndromes always means a highly critical situation that has to be resolved in a very short time, both protected and unprotected LM stenosis can be the reason for stable and unstable coronary syndromes, causing hemodynamic instability requiring emergency bypass surgery, or if an operation is not possible, an emergency percutaneous treatment is an option, as with this patient that he had NSTEMI 5 month ago with significant residual angina symptom (CCS III), despite of optimal medical therapy with dual antiplatelet and nitrate, statin and nondihydropyridine CCB<sup>8</sup>.

LMCA angioplasty is often perceived as an extremely complex procedure with a high incidence of periprocedural complications, which should always be avoided in the presence of the evidence significant LMCA disease, this in turn leaves the surgeon to address the burden of the issues related to treatment of significant LMCA disease.<sup>1</sup> In actual fact the application of percutaneous coronary intervention (PCI) to selected cases has proven to be safe and effective in managing LMCA disease, this is corroborated by the latest evidence in the literature about the feasibility and safety of PCI procedure in unprotected LMCA disease, as we know that on the basis of the hemodynamic situation, the outcomes of percutaneous interventions on protected and unprotected LM stenosis differ considerably.<sup>4,8</sup>

Regarding the result of MSCT examination in this patient, CABG was previously offer, fortunately since he refused surgery then PCI intervention of unprotected significant ostial LMCA disease was performed with successful BMS implantation, using anchor wire technique, that was first described by Szabowich facilitate precise ostial stent placement and eliminate errors of positioning inside or outside the ostial narrowing, the ostial lesions were crossed by guide wire through respective guiding catheter then predilated with appropriate balloon at high pressure and followed by deployment of Tsunami stent 4.0 x 15 mm.<sup>1,2</sup> In one of large multicenter cohort study of patients with unprotected LMCA disease comparing CABG and PCI, there was no significant difference in the risks of death and a composite outcome of death, Q-wave MI, or stroke between PCI and CABG groups during 5 years of follow-up.<sup>8</sup>

**Table 1.** Etiology of Left Main Coronary artery disease<sup>2</sup>.

Atherosclerosis
Non atherosclerosis etiologies
Radiation
Takayasu's arteritis
Syphilitic aortitis
Rheumatoid arthritis
Aortic valve disease
Kawasaki disease
Injury after left main coronary intervention or cardiac surgery
Idiopathic

This finding were consistent when BMS or DES were used compared with CABG, but the rate of total vessel revascularization (TVR) was significantly lower in CABG group than in PCI group, but sub analysis showed that among patients with unprotected LMCA disease who received DES, a 5-year cumulative stent thrombosis incidence is 1.5%, consistent to other studies with a range between 1% and 2%.<sup>9</sup> DES implantation in ostial LMCA lesions appears safe and effective and is associated with a significant decrease in restenotic rates compared with BMS, another multicentre registry conducted by Chieffo et al showed that the elective use of DES in unprotected LMCA stenosis appears to be safe and effective and restenosis rate is less with DES stent as compared to BMS but due to financial constraints in this patient bare metal stents were implanted.<sup>10</sup>

Nonsurgical of unprotected LMCA intervention is in a milestone process among nonsurgical intervention technique and development, as with rapid growing of new evidence of safety and feasibility, before 2009 many intervention cardiologists consider that unprotected of LMCA disease mostly is still in the "province" of surgeon, patients undergoing PCI of unprotected LMCA disease have frequent serious comorbidities and consequently have high event rates, so that PCI was consider as an alternative to CABG for a select proportion of elective patients and may also be appropriate for highly symptomatic inoperable patients.<sup>6</sup> Percutaneous revascularization of patients with significant LMCA stenosis was first described by Gruntzigin his original report on PTCA in 1979, but due to procedural difficulties and an early cardiac death, LMCA stenosis was a contraindication for balloon angioplasty.<sup>4</sup>

Another experience of LMCA balloon angioplasty was reported by O'Keefe et al, they done series of 127 procedures and 33 of them were performed on an unprotected LMCA stenosis, despite the initial success of 94%, there was a 9.1% procedural mortality with only 35% surviving to 3 years and they concluded that angioplasty was technically feasible but the results were inferior to the surgical procedure.<sup>4</sup> With the advent of newer interventional devices, particularly the coronary stent, the risk of acute closure has been significantly reduced and therefore there has been a renewed interest in percutaneous intervention. Even so, until there are controlled double blind studies comparing surgical revascularisation, the indications for percutaneous interventions will remain tightly restricted.<sup>8</sup> These now include:

- Those who refuse surgery.
- Those at too high a risk for surgery - advanced renal, pulmonary or hepatic disease.
- Those with limited life expectancy.
- Those with acute MI and in cardiogenic shock.
- Protected left main disease.

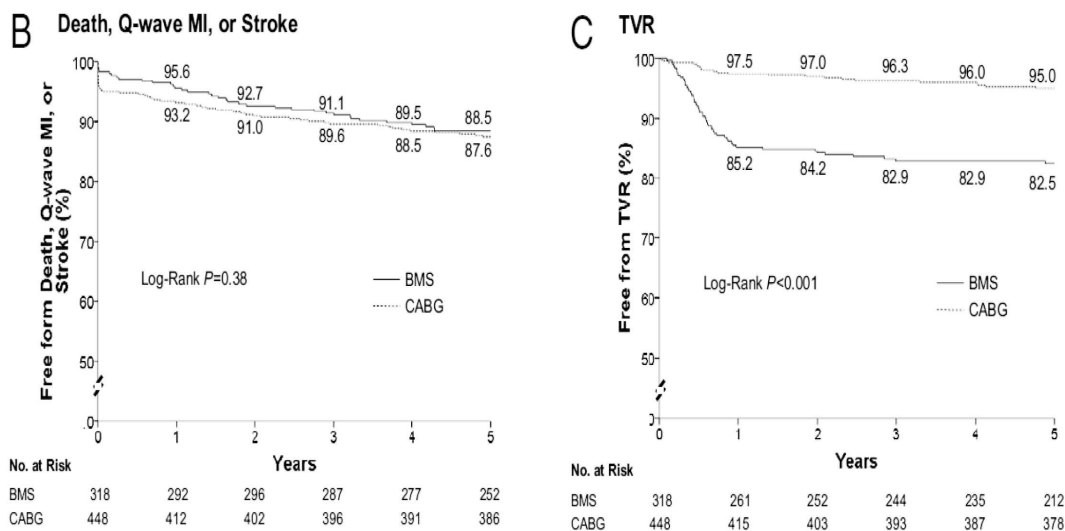
In dealing with LMCA stenosis there are certain important factors that need to be considered, such as prognostic factors, protected or unprotected LMCA stenosis and emergency or elective cases. Technical considerations of PCI are depending on the location of stenosis: aorto-ostial, left main trunk or distal bifurcation.<sup>2,6</sup>

In January 1994, a multicentre registry (Unprotected left main trunk intervention multicentre assessment ULTIMA) was started to assess the results of LMCA intervention. Data from this and the single centre experience by Park et al, have been useful to evaluate the results with the newer devices. There are few studies that have looked at angioplasty in patients with unprotected LMCA stenosis the registry data showed 12% in hospital mortality and a further 17% mortality within 12 months and the event free survival was also very poor. The single centre experience of Park et al, was better and this was attributed to more of isolated LMCA stenosis, less of distal bifurcation lesions and better LV function.<sup>1,5</sup>

As stated by Park et al in MAIN-COMPARE Registry study (Revascularization for Unprotected Left Main Coronary Artery Stenosis: Comparison of Percutaneous Coronary Angioplasty Versus Surgical Revascularization) involving 2,240 patient with 5 years prospective cohort that showed similar long-term (5-year) rates of death and the composite end point of death, Q-wave MI, or stroke for patients with unprotected LMCA disease whom perform PCI with stenting and CABG but rates of repeat revascularization were still higher among patients who underwent PCI than among those who underwent CABG.<sup>8,10</sup>

## Summary

A 58<sup>th</sup> years old man with CAD risk factor; smoker, dyslipidemia and hypertension complain of chest discomfort on daily activities, he was referred to NCCHK from Sanglah hospital with diagnosis of APS CCS III with previously history of non ST elevation myocardial infarction (NSTEMI), his MSCT coroner revealed mild plaque burden with critical subtotal



Picture 6. Comparison of end point of CABG and BMS<sup>8</sup>

occlusion in left main coroner artery and calcified plaque before D1 with no significant stenosis in LAD and other vessels were normal. He went for percutaneous coronary intervention and reveled significant isolated unprotected LMCA disease, successful PCI using the anchor wire technique and implantation of BMS stent in ostial LMCA lesion was done, the patient was discharge on day 6 of hospitalization, there are no significant complication during and after procedure, patient report improve exercise tolerance during outpatient visit in polyclinic.

## References

- Di Salvo Me, La Manna A, Capodanno D. Literature Review. In: Tamburino C, Editor. Left Main Coronary Artery Disease A Practical Guide For The Interventional Cardiologist. Italia: Springer; 2009.P:15-26.
- Ladich E, Burke Ap, Joner M, Kolodgie F, Kutys R And Virmani R. Pathology Of Left Main Coronary Artery. In: Jung Park S, MintzGs, Editors. Handbook Of Left Main Stem Disease. United Kingdom: Informa; 2006.P:1-26.
- Mardiansyah, Et Al. Medical Record Ncchk 2008-2010. Ncchk: 2011.
- Kandzari De, Colombo A, Jung Park S, TommasoCl, Ellis Sg, Guzman La, Teirstein Ps, Tamburino C, Et All. Revascularization For Unprotected Left Main Disease: Evolution OfThe Evidence Basis To Redefine Treatment Standards. J. Am. Coll. Cardiol. 2009;54:1576-88.
- Jung Park S And Woo Park D. Percutaneous Coronary Intervention With Stent Implantation Versus Coronary Artery Bypass Surgery For Treatment Of Left Main Coronary Artery Disease : Is It Time To Change Guidelines?. CircCardiovasc Interv. 2009;2:59-68.
- Patel MR, Dehmer GJ, Hirshfeld JW, Smith PK, and Spertus JA. ACCF/ SCAI/ STS / AATS / AHA / ASNC 2009 Appropriateness Criteria for Coronary Revascularization. J.Am. Coll. Cardiol. 2009;53:530-53.
- Darabian S, Amirzadegan A, Sadeghian H, Sadeghian S, Abbasi A, And Raeesi M. Ostial Lesions Of Left Main And Right Coronary Arteries: Demographic And Angiographic Features. *Angiology*, 2008;10:1177-88.
- Woo Park D, Seung Kb, Jung Park S, Hak Kim Y, Young Lee J, Jang Kim W, Jin Kang S, Et All. Long-Term Safety And Efficacy Of Stenting Versus Coronary Artery Bypass Grafting For Unprotected Left Main Coronary Artery Disease: 5-Year Results From The Main-Compare (Revascularization For Unprotected Left Main Coronary Artery Stenosis: Comparison Of Percutaneous Coronary Angioplasty Versus Surgical Revascularization) Registry. J. Am. Coll. Cardiol. 2010;10:1016:1-10.
- PandyaSb, Hak Kim Y, MeyersSn, DavidsonCj, FlahertyJd, Woo Park W, Mediratta A, Et All. Drug-Eluting Versus Bare-Metal Stents In Unprotected Left Main Coronary Artery Stenosis. J Am Coll Cardiol Intv, 2010; 3:602-611.
- Chieffo A, Jung Park S, Meliga E, Sheiban I, S. Lee5 M, Latib A, Hak Kim Y, Et All. Late And Very Late Stent Thrombosis Following Drug-Eluting Stent Implantation In Unprotected Left Main Coronary Artery: A Multicentre Registry.